


ISSN 2321-4600

Vol. 5 | Issue 5 | Sep 2015



Trends in Orthodontics

Official Publication of
Asian Pacific Orthodontic Society



The Benefit System and its scope in contemporary orthodontic protocols

**Benedict Wilmes,
Jan Willmann,
Bruce Stocker,
Dieter Drescher**

*Department of Orthodontics,
University of Duesseldorf,
Moorenstr 5,
40225 Düsseldorf, Germany*

Abstract

Currently, the alveolar process is the most preferred insertion site for orthodontic mini-implants. However, due to the varying bone quality and the risk of root contact, the survival rate of implants inserted in the alveolar ridge still needs improvement. Other regions, such as the anterior palate and the mental region provide much better conditions for temporary anchorage device (TAD) insertion since the amount and quality of the available bone are far superior. Mini-implants with different types of abutments and connectors allow the construction of versatile and cost efficient appliances for a large variety of orthopedic and orthodontic applications. Utilizing TAD's in the anterior palate and the mental region eliminates the risk of root injury and takes the implants out of the path of tooth movement. The design of the interchangeable abutment system provides the orthodontist with a skeletal anchorage system that integrates easily into clinical practice and allows treatment of cases that were difficult or impossible to treat previously.

Key words: Class III treatment, distalization, mini-implant, skeletal anchorage, temporary anchorage device

INTRODUCTION

Mini-implants have become a common treatment modality in orthodontics due to their versatility, minimal invasiveness, and cost effectiveness. Still, today, the alveolar process is the most preferred insertion site.^[1-5] However, due to varying bone and soft tissue conditions, orthodontists are still confronted with an average loss rate of 16.1%, as reported in recent literature.^[6-9]

To enhance success rates five strategies were developed:

1. Selection of the optimum insertion site.
2. Avoidance of root contact.
3. Getting out of the path of tooth movement.

4. Use of tandem implants and.
5. Use of implants with sufficient length and diameter.

Applying these strategies and choosing the anterior palate as insertion site loss rates could be decreased to values as low as 2.1%.^[10]

Selection of the anterior palate in the upper jaw and miniplates in the lower jaw rendered the insertion of mini-implants in the alveolar ridges obsolete. Based on clinical examples and scientific evaluation, new

This is an open access article distributed under the terms of the Creative Commons Attribution-NonCommercial-ShareAlike 3.0 License, which allows others to remix, tweak, and build upon the work non-commercially, as long as the author is credited and the new creations are licensed under the identical terms.

For reprints contact: reprints@medknow.com

How to cite this article: Wilmes B, Willmann J, Stocker B, Drescher D. The Benefit System and its scope in contemporary orthodontic protocols. APOS Trends Orthod 2015;5:174-80.

Access this article online	
Quick Response Code:	Website: www.apospublications.com
	DOI: 10.4103/2321-1407.163414

Address for correspondence:

Dr. Benedict Wilmes, Department of Orthodontics, University of Duesseldorf, Moorestr 5, 40225 Düsseldorf, Germany.
E-mail: wilmes@med.uni-duesseldorf.de

solutions for a variety of treatment tasks such as molar distalization and mesialization, molar intrusion and extrusion, asymmetric space closure, midline correction, and anchorage of anterior and lateral dental segments are now available.

A new generation of mini-implants with interchangeable abutments (Benefit System, PSM, Germany^[11]) was developed that allow integration into the orthodontic mechanics [Figure 1]. For very high demands on the anchorage quality, two mini-implants were used. To couple two mini-implants very easily, a Beneplate^[12] (PSM, Germany, [Figure 1h]) is available in two different lengths. For connection to the orthodontic appliance, Beneplates with a stainless steel wire (1.1 mm or 0.8 mm) or a stainless steel bracket are employed. The Beneplate can be adapted to the Benefit mini-implants by bending of the miniplate body as well as the wire [Figure 2].

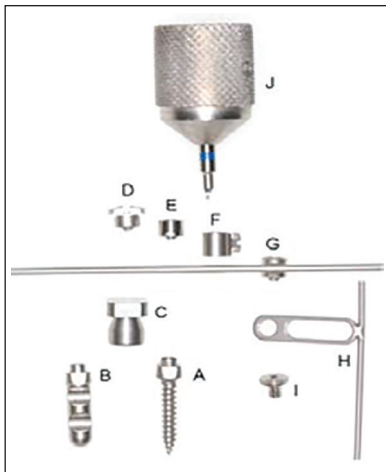


Figure 1: Benefit/Beneplate System: (a) Mini-implant. (b) Laboratory analog. (c) Impression cap. (d) Slot abutment. (e) Standard abutment. (f) Bracket abutment. (g) Wire abutment with wire in place. (h) Beneplate with wire in place. (i) Fixation screw. (j) Screwdriver for abutment fixation

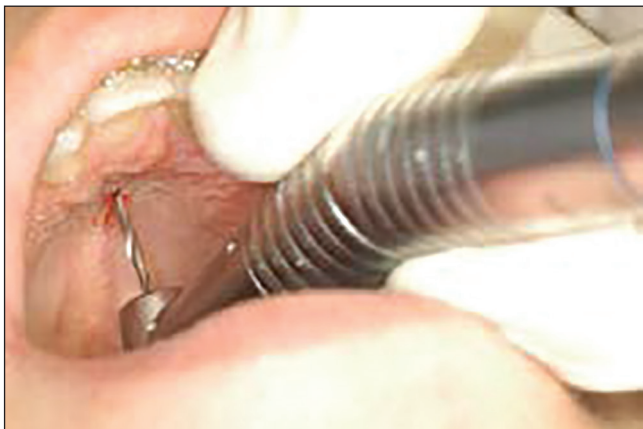


Figure 3: Manual predrilling (only needed in adults)

IMPLANT PLACEMENT AND ADAPTION OF THE MECHANICS

Due to a very good bone quality and quantity, the anterior palate is the favorite insertion site.^[13] If the patient is apprehensive about the use of a needle syringe, the miniscrews can be placed using only topical anesthetic (jelly). In adult patients, a pilot drilling (2-3 mm depth) should be performed due to very high bone densities [Figure 3]. In children and adolescents with relatively low bone mineralization, pilot drilling is not needed. Mini-implants with a diameter of 2 mm or 2.3 mm and lengths of 9 mm (anterior) and 7 mm (posterior) are inserted, which provides the best stability [Figures 4-6].^[14-17]

In many cases, the appliance could be adapted intra-orally, which, of course, implies some chair time [Figure 7a and b]. The alternative is to adapt the mechanics in the laboratory by taking a silicon impression and transferring the intra-oral setup to a plaster cast using the impression cap and the laboratory analogue from the Benefit System^[11] [Figure 1b and c].



Figure 2: Bending of the Beneplate to fit on two mini-implants

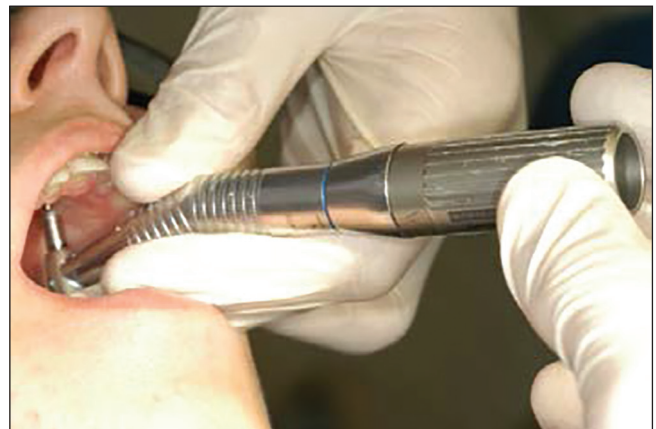

Figure 4: Manual insertion using the handpiece (PSM, Germany)

CLINICAL APPLICATIONS

Maxillary molar distalization (Beneslider and pendulum B)

The treatment objective of upper molar distalization may be required frequently during correction of malocclusions. The most common indication is a dentoalveolar Class II malocclusion with increased overjet and/or anterior crowding. Another less frequent indication may be to correct dentoalveolar compensation in Class III patients that are undergoing surgery. Due to esthetic drawbacks and the length of time to be worn, molar distalization with a headgear is unpleasant for many patients.^[18,19] This has resulted in a tendency to favor purely intra-oral distalization appliances with minimal need for patient cooperation. Unfortunately, most of the conventional devices for noncompliance maxillary molar distalization show some unwanted side effects, such as anchorage loss, especially, when distalization forces are applied buccally.^[20] One possibility to reduce unwanted effects of reciprocal orthodontic forces is the use of palatal acrylic pads (Nance buttons). However, the anchorage stability of this soft-tissue borne element is not always certain. Moreover, oral hygiene is impaired due to the partial coverage of the palatal area. If the anchorage unit includes teeth, mesial migration and/or protrusion of the anterior dentition have to be considered as major drawbacks.^[21,22] The amount of the anchorage loss of conventional intra-oral devices ranges between 24% and 55%.^[23] Although indirect anchorage can

be used to support the premolars during maxillary molar distalization, miniscrew tipping and wire deformation may result in anchorage loss and mesial premolar migration. Moreover, after molar distalization, the appliance must be refabricated for distalization of the premolars and anterior teeth. Therefore, direct anchorage is preferable.

To benefit from the advantages of direct anchorage mechanics and of the anterior palate as the most suitable mini-implant insertion site, the Beneslider^[5,11,12,24,25] device has been designed fixed on top of mini-implants with exchangeable abutments. The Beneslider utilizes sliding mechanics and has proved to be a reliable distalization device^[25] [Figure 8]. However, if frictionless mechanics is preferred and/or the molars are to be uprighted or derotated simultaneously during distalization, pendulum mechanics can be employed.^[26] Several authors introduced skeletally-supported pendulum mechanics to avoid anchorage loss.^[27-30] However, all described appliances require additional laboratory work. The pendulum B^[31] was designed to have the ability to adapt a skeletal borne pendulum device chair side immediately after mini-implant insertion without a laboratory procedure [Figure 9].

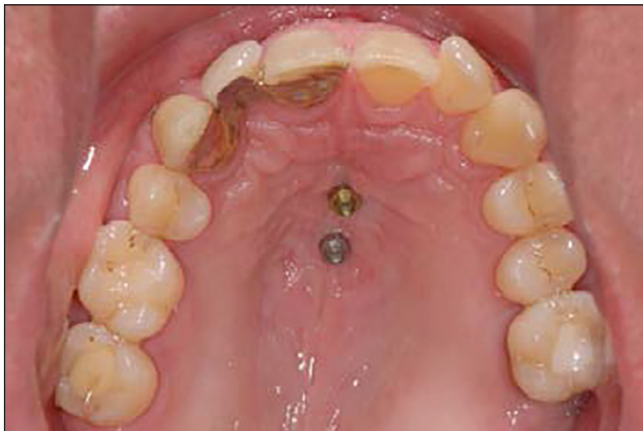

Figure 5: Insertion of two mini-implants posterior from the rugae, the distance between the mini-implants should be 8-14 mm

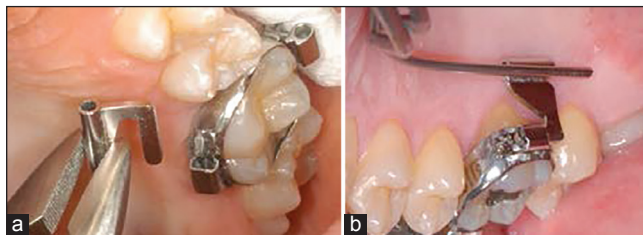

Figure 7: (a) Intra-oral adaption of a Benetube for a Beneslider. (b) Intra-oral adaption of the Beneplate for the Mesialslider

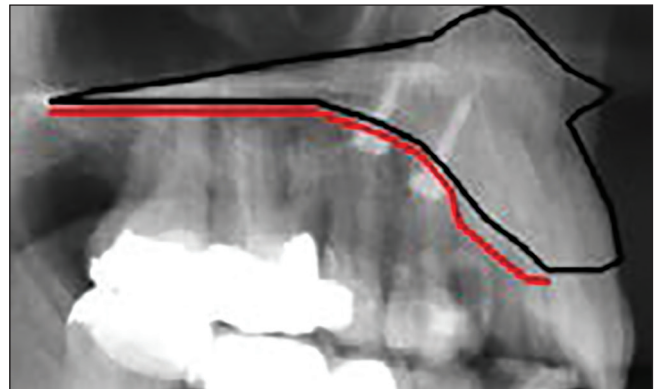


Figure 6: Angulation of the insertion is perpendicular to the bone. The soft tissue anterior is too thick

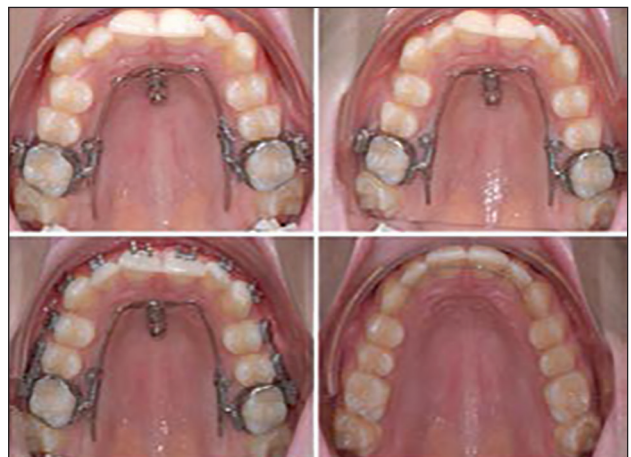

Figure 8: Clinical example: Beneslider for upper molar distalization

Maxillary space closure (Mesialslider)

Unilateral or bilateral missing upper teeth are diagnosed quite frequently: Congenitally missing lateral incisors/second bicusps, extremely displaced canines or a severe trauma of a central incisor are potential complaints that result in a reduced upper dentition. The two major treatment approaches are space closure or space opening to allow prosthodontic replacements either with a fixed prosthesis or single-tooth implant. Both of these treatment approaches may potentially compromise aesthetics, periodontal health, and function.^[32] In many cases, space closure to the mesial seems to be the favorable treatment goal, since treatment already can be completed as soon as the dentition is complete.^[33] Canine substitutions can be accomplished with good aesthetic outcomes by tooth reshaping and positioning, bleaching, and porcelain veneers.^[34,35]

The more mesial the missing tooth is, the higher will be the demands for anchorage quality, especially in asymmetric cases with a midline deviation. If the central

incisors are in the correct position (midline, torque and angulation are correct), a T-Bow^[11,12,36] can be bonded to the lingual surfaces of the central incisors to apply an indirect anchorage with the goal to avoid lingual tipping of the central incisors during space closure.^[11,12,36] As an alternative to the T-Bow (indirect anchorage), the Mesialslider^[11,12,37] as a direct anchorage device can be used. The Mesialslider enables clinicians to mesialize upper molars unilaterally or bilaterally. Since the incisors are not fixed, a midline deviation can be corrected at the same time. The Mesialslider can be used to close space in the upper arch from distal, e.g., for missing lateral incisors [Figure 10], canines [Figure 11], premolars [Figure 12] or molars. The Mesialslider can also be used for protrusion of the whole upper dentition to compensate a mild Class III occlusion.^[37]

Asymmetric molar distalization and space closure (Mesial-Distalslider)

In many cases with unilaterally missing teeth, the midline is off. The favored appliance to correct the midline, to close the space on one side and to distalize the contralateral segment is a combination of the Mesialslider and a Beneslider, the Mesial-Distalslider^[38] [Figure 13].

Rapid palatal expansion and early Class III treatment

Rapid palatal expansion (RPE) is considered to be the first orthodontic procedure to achieve skeletal widening

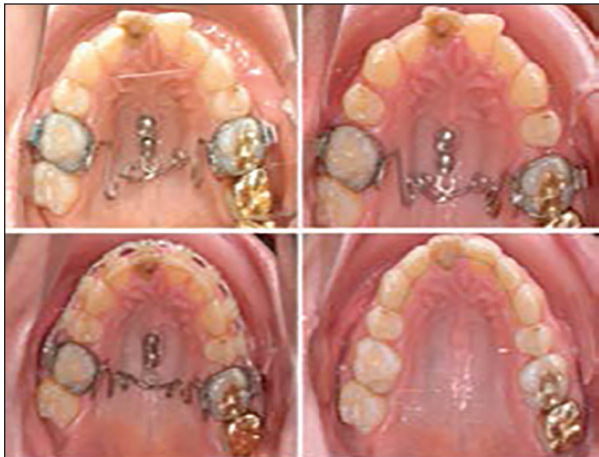

Figure 9: Clinical example: Pendulum B for upper molar distalization

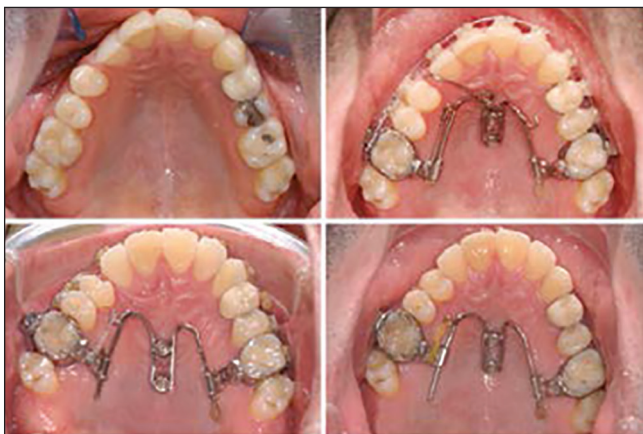

Figure 11: Clinical example with missing upper right canine: Mesialslider for unilateral upper mesialization

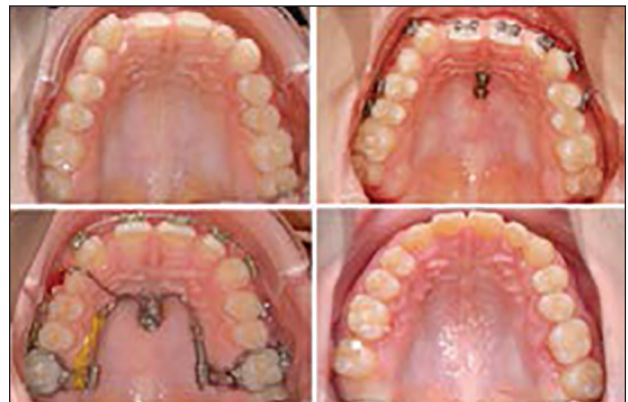

Figure 10: Clinical example with missing upper right lateral incisor: Mesialslider for unilateral upper mesialization

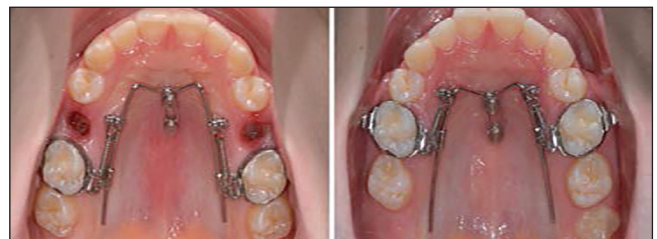

Figure 12: Clinical example with missing upper second bicusps: Mesialslider for bilateral upper mesialization

of the maxilla. Today, RPE is considered to be a method for sutural distraction osteogenesis. For the treatment of patients with a Class III caused by a retrognathic maxilla, RPE is combined with a facemask for the protraction of the maxilla. Since the orthopedic forces are transmitted to the skeletal structures via the anchor teeth, distribution of the forces to as many teeth as possible, as well as completion of root growth, are considered essential. However, besides the therapeutically intended skeletal expansion, side-effects such as buccal tipping of the anchor teeth, fenestration of the buccal bone, root resorptions, and gingiva recessions were reported in some cases.^[39,40] To avoid these complications caused by the tooth-borne character of the conventional appliances, some authors reported about pure bone-borne RPE devices. Several palatal distractors have been presented over the last decade.^[41,42] However, insertion and removal of these miniplate-borne distractors are invasive surgical procedures with the need of a flap preparation, risk of root lesions and infections.^[41,43] As a consequence distractors of this type could not establish themselves as standard devices for RPE. To minimize the surgical procedure, Harzer introduced the Dresden-Distractor that is borne solely on an implant and a mini-implant.^[44-46] Due to the risk of a root lesion at the insertion of implants in the lateral posterior alveolar process and lack of available bone in the median posterior palate, we used the 1st molars or 2nd deciduous as posterior anchorage unit. In the anterior median palate, there is more bone available for mini-implants^[13] and the resulting appliance is a half tooth-borne half bone-borne RPE device called hybrid hyrax^[5,11,47-49] [Figure 14].

The application of the hybrid hyrax is minimally surgical invasive compared with pure bone-borne RPE devices like distractors.^[41,42] To employ the first molars or second deciduous molars as posterior anchorage unit and mini-

implants as skeletal anterior anchorage unit provides several advantages.^[47-49]

- Applicable in cases with low anterior dental anchorage quality due to missing deciduous molars or deciduous molar with short roots.
- Applicable in cases with immature root development of the premolars.
- No risk of impairment of root development (curved roots).
- Reduction of the dental side effects, that is, premolar tipping.^[48]
- Anterior dentition is not bonded during the retention phase, and thus regular orthodontic treatment could be started earlier.
- Advantageous in cases with need for early Class III treatment, where the RPE supports maxillary advancement by weakening the midface sutures.
- Avoidance of mesial migration of the upper dentition during application of a facemask or the Mentoplate,^[47] thus enhancing the skeletal effects.^[48]

Skeletal Class III malocclusions are relatively infrequent, and their genesis is usually associated with genetic factors.^[50,51] The Class III relationship may be caused by a retrognathic maxilla, a prognathic mandible or both.^[50,51] Treatment of young Class III patients with maxillary deficiency is mostly conducted with a facemask. Since the force is applied to the teeth, mesial migration of the dentition is inevitable and may result in severe anterior crowding.^[52] On the other hand, the desired skeletal effect of this commonly used approach often turns out to be less than expected.^[52] To overcome these drawbacks and to minimize mesial migration of the molars, sagittal skeletal support by the hybrid hyrax is very useful. Secondly, to facilitate the advancement of the maxilla, opening of the midface sutures by RPE is recommended.^[53] With the goal to avoid an extra-oral device (facemask) and to apply the forces directly to the skeletal structures, De Clerck introduced the use of four miniplates (two anterior in the lower jaw and two posterior in the upper jaw) in combination with Class III elastics.^[54] This represents a new purely skeletal

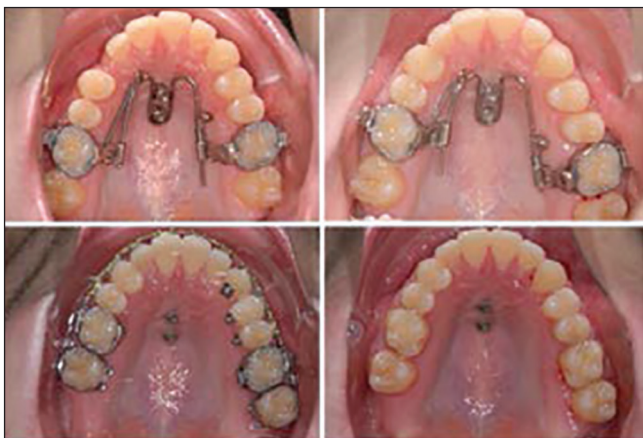

Figure 13: Clinical example with missing upper right canine and midline shift: Mesial-Distalslider for unilateral upper mesialization and contralateral distalization

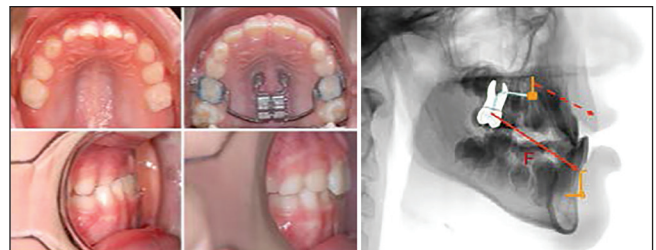


Figure 14: Hybrid hyrax. Anterior anchorage is provided by two 2 mm x 9 mm Benefit mini-implants, placed about 5 mm apart. Before and after rapid maxillary expansion and Class III treatment using a facemask

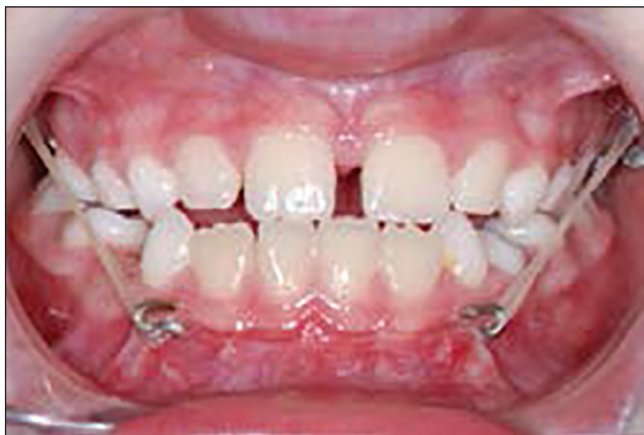

Figure 15: Skeletal born early Class III treatment using the hybrid hyrax and the Mentoplate

approach to correct the skeletal discrepancy. In order to enhance the skeletal effect by opening the midface sutures, we employ the hybrid hyrax appliance in the upper jaw allowing simultaneous rapid maxillary expansion and skeletally borne maxillary protraction. In the lower jaw, the Bollard miniplates by De Clerck are usually inserted after the eruption of the canines. To allow earlier insertion of the miniplate in the mandible, we developed the Mentoplate [Figure 15].^[47] Since the Mentoplate is inserted subapically to the lower incisors, it typically can be used already at the age of 8-9 years. By means of the hybrid hyrax in combination with a facemask or a Mentoplate forces are applied to skeletal structures only with the goal to achieve an optimum skeletal effect [Figure 15].

CONCLUSION

To summarize, the Benefit mini-implant in combination with the Beneplate expands skeletal anchorage options in orthodontic treatment and reduces the failure rate significantly. Insertion and removal are minimally invasive procedures: Orthodontists can place the screws by themselves and load them immediately. Usually, the screws can be removed without anesthesia. The anterior palate is our preferred insertion region because of its superior bone quality and relatively low rates of miniscrew instability and failure. The attached mucosa has a better prognosis than other areas, and there is no risk of tooth damage. In the mandible, miniplates such as Bollard plates or the Mentoplate are recommendable for orthopedic and orthodontic purposes.

Financial support and sponsorship

Nil.

Conflicts of interest

There are no conflicts of interest.

REFERENCES

- Costa A, Raffaini M, Melsen B. Miniscrews as orthodontic anchorage: A preliminary report. *Int J Adult Orthodon Orthognath Surg* 1998;13:201-9.
- Freudenthaler JW, Haas R, Bantleon HP. Bicortical titanium screws for critical orthodontic anchorage in the mandible: A preliminary report on clinical applications. *Clin Oral Implants Res* 2001;12:358-63.
- Kanomi R. Mini-implant for orthodontic anchorage. *J Clin Orthod* 1997;31:763-7.
- Melsen B, Costa A. Immediate loading of implants used for orthodontic anchorage. *Clin Orthod Res* 2000;3:23-8.
- Wilmes B. Fields of application of mini-implants. In: Ludwig B, Baumgaertel S, Bowman J, editors. *Innovative Anchorage Concepts. Mini-Implants in Orthodontics*. Berlin, New York: Quintessenz; 2008.
- Berens A, Wiechmann D, Dempf R. Mini- and micro-screws for temporary skeletal anchorage in orthodontic therapy. *J Orofac Orthop* 2006;67:450-8.
- Cheng SJ, Tseng IY, Lee JJ, Kok SH. A prospective study of the risk factors associated with failure of mini-implants used for orthodontic anchorage. *Int J Oral Maxillofac Implants* 2004;19:100-6.
- Fritz U, Ehmer A, Diedrich P. Clinical suitability of titanium microscrews for orthodontic anchorage-preliminary experiences. *J Orofac Orthop* 2004;65:410-8.
- Miyawaki S, Koyama I, Inoue M, Mishima K, Sugahara T, Takano-Yamamoto T. Factors associated with the stability of titanium screws placed in the posterior region for orthodontic anchorage. *Am J Orthod Dentofacial Orthop* 2003;124:373-8.
- Karagkiolidou A, Ludwig B, Pazera P, Gkantidis N, Pandis N, Katsaros C. Survival of palatal miniscrews used for orthodontic appliance anchorage: A retrospective cohort study. *Am J Orthod Dentofacial Orthop* 2013;143:767-72.
- Wilmes B, Drescher D. A miniscrew system with interchangeable abutments. *J Clin Orthod* 2008;42:574-80.
- Wilmes B, Drescher D, Nienkemper M. A miniplate system for improved stability of skeletal anchorage. *J Clin Orthod* 2009;43:494-501.
- Kang S, Lee SJ, Ahn SJ, Heo MS, Kim TW. Bone thickness of the palate for orthodontic mini-implant anchorage in adults. *Am J Orthod Dentofacial Orthop* 2007;131 4 Suppl:S74-81.
- Wilmes B, Ottenstreuer S, Su YY, Drescher D. Impact of implant design on primary stability of orthodontic mini-implants. *J Orofac Orthop* 2008;69:42-50.
- Wilmes B, Rademacher C, Olthoff G, Drescher D. Parameters affecting primary stability of orthodontic mini-implants. *J Orofac Orthop* 2006;67:162-74.
- Wilmes B, Su YY, Drescher D. Insertion angle impact on primary stability of orthodontic mini-implants. *Angle Orthod* 2008;78:1065-70.
- Wilmes B, Su YY, Sadigh L, Drescher D. Pre-drilling force and insertion torques during orthodontic mini-implant insertion in relation to root contact. *J Orofac Orthop* 2008;69:51-8.
- Clemmer EJ, Hayes EW. Patient cooperation in wearing orthodontic headgear. *Am J Orthod* 1979;75:517-24.
- Egolf RJ, BeGole EA, Upshaw HS. Factors associated with orthodontic patient compliance with intraoral elastic and headgear wear. *Am J Orthod Dentofacial Orthop* 1990;97:336-48.
- Antonarakis GS, Kiliaridis S. Maxillary molar distalization with noncompliance intramaxillary appliances in Class II malocclusion. A systematic review. *Angle Orthod* 2008;78:1133-40.
- Bussick TJ, McNamara JA Jr. Dentoalveolar and skeletal changes associated with the pendulum appliance. *Am J Orthod Dentofacial Orthop* 2000;117:333-43.
- Ghosh J, Nanda RS. Evaluation of an intraoral maxillary molar distalization technique. *Am J Orthod Dentofacial Orthop* 1996;110:639-46.
- Fortini A, Lupoli M, Giuntoli F, Franchi L. Dentoskeletal effects induced by rapid molar distalization with the first class appliance. *Am J Orthod Dentofacial Orthop* 2004;125:697-704.

24. Wilmes B, Drescher D. Application and effectiveness of the Beneslider: A device to move molars distally. *World J Orthod* 2010;11:331-40.
25. Nienkemper M, Wilmes B, Pauls A, Yamaguchi S, Ludwig B, Drescher D. Treatment efficiency of mini-implant-borne distalization depending on age and second-molar eruption. *J Orofac Orthop* 2014;75:118-32.
26. Hilgers JJ. The pendulum appliance for Class II non-compliance therapy. *J Clin Orthod* 1992;26:706-14.
27. Kircelli BH, Pektas ZO, Kircelli C. Maxillary molar distalization with a bone-anchored pendulum appliance. *Angle Orthod* 2006;76:650-9.
28. Karcher H, Byloff FK, Clar E. The Graz implant supported pendulum, a technical note. *J Craniomaxillofac Surg* 2002;30:87-90.
29. Kinzinger G, Wehrbein H, Byloff FK, Yildizhan F, Diedrich P. Innovative anchorage alternatives for molar distalization — An overview. *J Orofac Orthop* 2005;66:397-413.
30. Oncag G, Akyalçın S, Arikan F. The effectiveness of a single osteointegrated implant combined with pendulum springs for molar distalization. *Am J Orthod Dentofacial Orthop* 2007;131:277-84.
31. Wilmes B, Katyal V, Drescher D. Mini-implant-borne pendulum B appliance for maxillary molar distalization: Design and clinical procedure. *Aust Orthod J* 2014;30:230-9.
32. Robertsson S, Mohlin B. The congenitally missing upper lateral incisor. A retrospective study of orthodontic space closure versus restorative treatment. *Eur J Orthod* 2000;22:697-710.
33. Zachrisson BU, Rosa M, Toreskog S. Congenitally missing maxillary lateral incisors: Canine substitution. *Point. Am J Orthod Dentofacial Orthop* 2011;139:434, 436, 438.
34. Zachrisson BU, Mjör IA. Remodeling of teeth by grinding. *Am J Orthod* 1975;68:545-53.
35. Thordarson A, Zachrisson BU, Mjör IA. Remodeling of canines to the shape of lateral incisors by grinding: A long-term clinical and radiographic evaluation. *Am J Orthod Dentofacial Orthop* 1991;100:123-32.
36. Baumgaertel S. Maxillary molar movement with a new treatment auxiliary and palatal miniscrew anchorage. *J Clin Orthod* 2008;42:587-9.
37. Wilmes B, Nienkemper M, Nanda R, Lübberink G, Drescher D. Palatally anchored maxillary molar mesialization using the Mesialslider. *J Clin Orthod* 2013;47:172-79.
38. Wilmes B, Nanda R, Nienkemper M, Ludwig B, Drescher D. Correction of upper-arch asymmetries using the Mesial-Distalslider. *J Clin Orthod* 2013;47:648-55.
39. Garib DG, Henriques JF, Janson G, de Freitas MR, Fernandes AY. Periodontal effects of rapid maxillary expansion with tooth-tissue-borne and tooth-borne expanders: A computed tomography evaluation. *Am J Orthod Dentofacial Orthop* 2006;129:749-58.
40. Schuster G, Borel-Scherf I, Schopf PM. Frequency of and complications in the use of RPE appliances — Results of a survey in the Federal State of Hesse, Germany. *J Orofac Orthop* 2005;66:148-61.
41. Mommaerts MY. Transpalatal distraction as a method of maxillary expansion. *Br J Oral Maxillofac Surg* 1999;37:268-72.
42. Koudstaal MJ, van der Wal KG, Wolvius EB, Schulten AJ. The Rotterdam Palatal Distractor: Introduction of the new bone-borne device and report of the pilot study. *Int J Oral Maxillofac Surg* 2006;35:31-5.
43. Fuck L, Wilmes B, Drescher D. Rapid palatal expansion with a transpalatal distractor. *Kieferorthopädie* 2008;22:251-8.
44. Hansen L, Tausche E, Hietschold V, Hotan T, Lagravere M, Harzer W. Skeletally-anchored rapid maxillary expansion using the dresden distractor. *J Orofac Orthop* 2007;68:148-58.
45. Harzer W, Schneider M, Gedrange T. Rapid maxillary expansion with palatal anchorage of the hyrax expansion screw — Pilot study with case presentation. *J Orofac Orthop* 2004;65:419-24.
46. Harzer W, Schneider M, Gedrange T, Tausche E. Direct bone placement of the hyrax fixation screw for surgically assisted rapid palatal expansion (SARPE). *J Oral Maxillofac Surg* 2006;64:1313-7.
47. Wilmes B, Nienkemper M, Ludwig B, Kau CH, Drescher D. Early class III treatment with a hybrid hyrax-mentoplate combination. *J Clin Orthod* 2011;45:1-7.
48. Wilmes B, Nienkemper M, Drescher D. Application and effectiveness of a mini-implant-and tooth-borne rapid palatal expansion device: The hybrid hyrax. *World J Orthod* 2010;11:323-330.
49. Ludwig B, Glas B, Bowman SJ, Drescher D, Wilmes B. Miniscrew-supported class III treatment with the hybrid RPE advancer. *J Clin Orthod* 2010;44:533-9.
50. Litton SF, Ackermann LV, Isaacson RJ, Shapiro BL. A genetic study of class 3 malocclusion. *Am J Orthod* 1970;58:565-77.
51. Proffit WR, Fields HW Jr, Moray LJ. Prevalence of malocclusion and orthodontic treatment need in the United States: Estimates from the NHANES III survey. *Int J Adult Orthodon Orthognath Surg* 1998;13:97-106.
52. Williams MD, Sarver DM, Sadowsky PL, Bradley E. Combined rapid maxillary expansion and protraction facemask in the treatment of class III malocclusions in growing children: A prospective long-term study. *Semin Orthod* 1997;3:265-74.
53. Baccetti T, McGill JS, Franchi L, McNamara JA Jr, Tollaro I. Skeletal effects of early treatment of class III malocclusion with maxillary expansion and face-mask therapy. *Am J Orthod Dentofacial Orthop* 1998;113:333-43.
54. De Clerck HJ, Cornelis MA, Cevidanes LH, Heymann GC, Tulloch CJ. Orthopedic traction of the maxilla with miniplates: A new perspective for treatment of midface deficiency. *J Oral Maxillofac Surg* 2009;67:2123-9.