

Benedict Wilmes

The new Benefit for Aligner Technique to overcome limitations of aligners



Benedict Wilmes

KEY WORDS aligners, asymmetry, Class II treatment, complex adult cases, distalisation, Invisalign, miniscrew, rapid maxillary expansion, skeletal anchorage

Aligners are gaining in popularity as adults in particular dislike the appearance of fixed appliances; however, it is difficult to achieve bodily tooth movement, especially of molars, when relying on aligners alone. Additionally, reinforced anchorage is required in some cases, and the potential side effects of maxillomandibular elastics must be considered, such as unwanted shift of the anchor teeth. This could pose a serious problem, especially when unilateral elastics are applied, as these have the potential to cause midline shift, arch rotation, arch discrepancy and transverse occlusal canting. To avoid the risks of tipping and anchorage loss, as well as the strict requirements for elastic wear, mini-implant-borne sliders and expanders can be used. The anterior palate provides excellent conditions for inserting and ensuring stability of skeletal anchorage devices, as the amount and quality of available bone are far superior to those in other regions of the oral cavity. In this paper, the most frequently used combinations of mini-implant-borne appliances and aligners (Benefit for Aligner Technique) are presented to show how more predictable and faster results can be achieved in aligner therapy.

Benedict Wilmes, Dr med dent, PhD
Professor, Department of Orthodontics, University of Duesseldorf,
Duesseldorf, Germany

Correspondence to: Dr Benedict Wilmes, Department for Orthodontics,
University of Dusseldorf, Moorenstr. 5, 40225 Dusseldorf, Germany. Email:
wilmes@med.uni-dueseldorf.de

Introduction

An increasing number of orthodontic patients present seeking invisible or aesthetic orthodontic treatment with clear sequential thermoplastic aligners, which offer the advantages of improved aesthetics, digital treatment planning and reduced risk of white spot lesions¹. Using aligners, teeth can be tipped and rotated effectively, depending on their morphology²; however, the treatment objective of achieving pure bodily tooth movement exclusively with aligner therapy and with a high level of predictability can prove challenging, especially when molars require bodily movement. Although there are only limited reports of successful movements of up to 2.5 mm in distalisation cases in the literature, a high level of patient compliance is expected, with the additional requirement for maxillomandibular elastics to be applied for extended periods³⁻⁵. Moreover, the potential side effects of these elastics must be considered in terms of how they contribute to shifting the anchor teeth. This can pose a serious problem, especially when unilateral elastics are applied, as these have the potential to cause midline shift, arch rotation, arch discrepancy and transverse occlusal canting. Arch width control in particular may be better when asymmetrical elastics are used in aligner treatment because of the absence of play between the wire and slot.

To minimise anchorage loss, mini-implants have been incorporated into aligner treatment planning recently⁶⁻⁹.

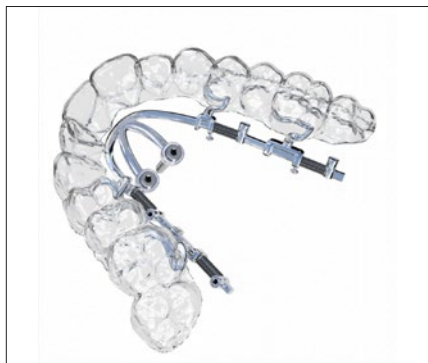

Fig 1 The BAT: a combination of sliders/expanders on palatal TADs and aligners.



Fig 2 CAD/CAM insertion guide.

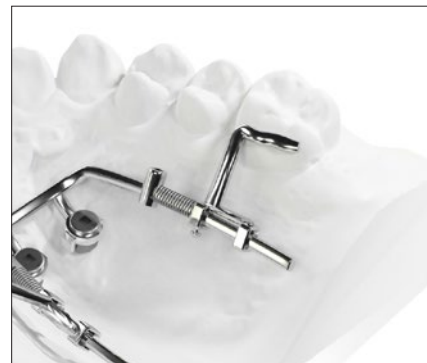

Fig 3 CAD/CAM metal printed Beneslider.

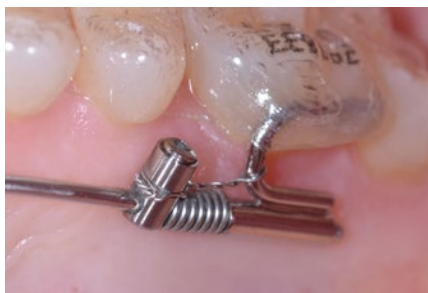

Fig 4 Bonded tube for the connection from a Beneslider to a molar. After distalisation, the appliance should be left in situ for molar anchorage (modified into a passive molar anchorage device by using a steel ligature).

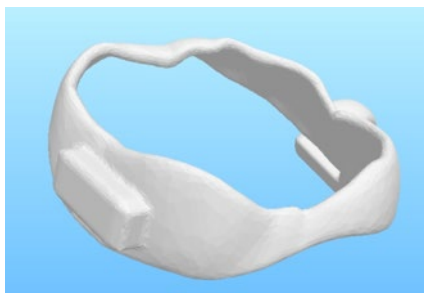


Fig 5 Design of a metal printed shell with a buccal attachment.

They can be positioned intraorally with a minimal degree of surgical invasiveness, are readily integrated with concomitant biomechanical initiatives and are relatively cost-effective¹⁰⁻¹². The use of mini-implants has increased over the last couple of years with a view to achieving more reliable anchorage^{10,13,14}.

Skeletal anchorage: Where to insert temporary anchorage devices (TADs)

The alveolar process and the infrazygomatic crest (IZC) region are still frequently used insertion sites for mini-implants; however, due to the high failure rate and the risk of root damage, insertion in these areas seems far from satisfactory¹⁵. Moreover, mini-implants that are inserted buccally can be positioned in the intended path of tooth movement. Lastly, bodily tooth movement is still not guaranteed. Conversely, the anterior palate offers the advantage of allowing all teeth to be moved without any interference from mini-implants^{16,17}. Furthermore, it is an area of high-quality bone with a thin attached mucosa, minimal risk of tooth

injury and a reported success rate of over 90%^{15,18-20}. Finally, bodily tooth movement is possible if palatal sliders with rails are employed. As such, it seems highly advisable to use mini-implants inserted in the anterior palate and sliders/expanders to:

- avoid unwanted movement of anchor teeth and reduce the need for maxillomandibular elastics to be worn;
- avoid tipping of teeth during desired bodily movements (in contrast to the use of IZC mini-implants).

This new combination of sliders/expanders on palatal temporary anchorage devices (TADs) and aligners is called the Benefit for Aligner Technique (BAT; Fig 1). Recent developments in CAD/CAM techniques have been published showing the possible use of insertion guides for palatal TADs to enable insertion of TADs and TAD-borne appliances in just one appointment (Fig 2)²¹. These guides may also give less experienced doctors more confidence in performing palatal TAD insertion. Nowadays, TAD-borne appliances can be metal printed using selective laser melting procedures that offer more opportunities for customisation (Fig 3)^{22,23}.

Connection of aligners and sliders

If clear aligners are to be used with a TAD-borne slider, the use of bonded tubes (Figs 3 and 4) or metal printed shells with attachments (Fig 5) is recommended⁹. With both of these, the adaptability and fit of the aligners is not undermined by the presence of stainless-steel molar bands, which is advantageous. The aligner material could therefore cover this bonded connection similarly to a large attachment (Fig 4).

Timing and staging

Two-phase approach

This approach involves an initial phase for molar distalisation/mesialisation/expansion, and a secondary phase for final detailing of the occlusion with aligners. In this two-phase approach, an impression or scan of the teeth is taken after the molar distalisation/space closure/expansion is completed.

One-phase approach

This involves simultaneous use of the TAD-borne slider and aligners. In a single, integrated approach, impressions/scans for aligners are taken immediately after insertion of the slider/expander. For this purpose, the mean speed of molar movements using sliders of 0.6 mm/month must be considered during aligner treatment planning^{24,25}.

Maxillary molar distalisation

Class II malocclusions are encountered frequently in orthodontic practice. Although there are limited reports of successful maxillary molar distalisation of up to 2.5 mm using aligners and Class II elastics in the literature, a high level of patient compliance is expected, with the additional requirement for maxillomandibular Class II elastics to be worn throughout sequential maxillary molar distalisation^{3,4,26}. Moreover, the potential side effects of Class II elastics must be considered in terms of mesial shift of the mandibular anchor teeth and resulting incisor protrusion. This could pose a serious problem, especially when unilateral Class II elastics are applied, as these have the potential to cause mandibular midline shift, maxillary rotation, arch discrepancy and transverse occlusal canting. The Beneslider²⁷⁻²⁹

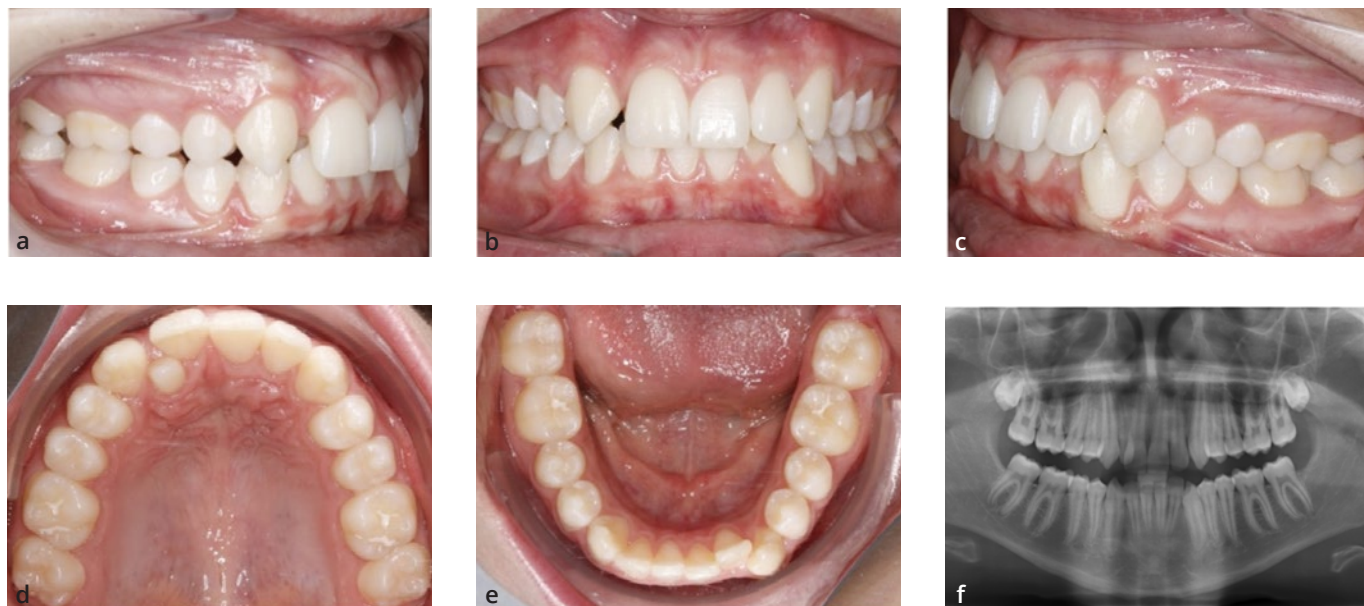
was the first mini-implant-borne maxillary molar distalisation appliance to be used in the anterior palate (Fig 3). A few other systems involving similar distalisation mechanics on TADs have now been designed³⁰. By modifying the angulation of the rail, it is possible to achieve distalisation and simultaneous intrusion or extrusion of the molars^{9,31,32}. Following distalisation of the maxillary molars, steel ligatures can be used or springs removed to modify the Beneslider from an active distalisation device to a passive molar anchorage device. The primary objective is to stabilise the maxillary molars during retraction of the maxillary anterior teeth.

Clinical case 1 using the Beneslider

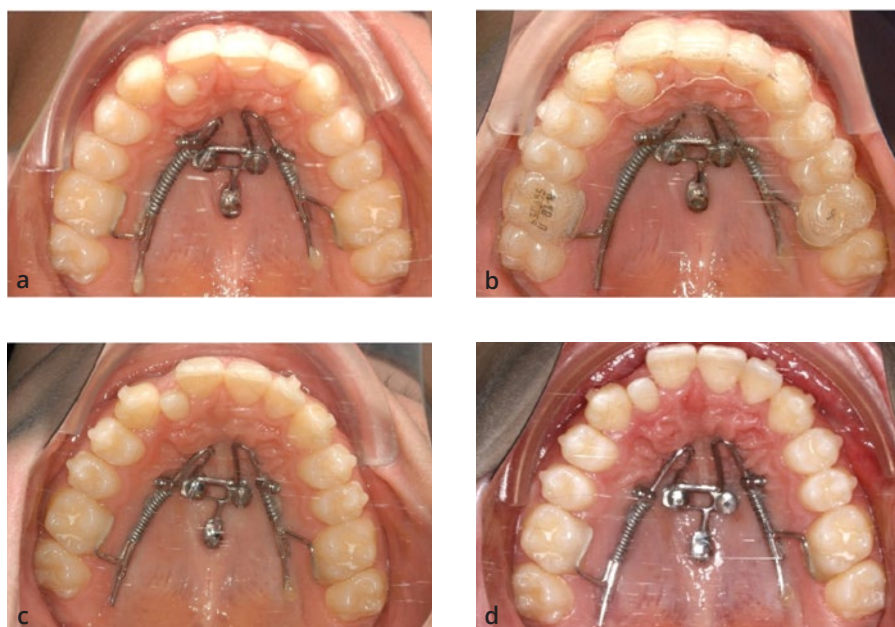
A 12-year-old boy with Angle Class II malocclusion presented with anterior crowding, midline deviation and a peg-shaped maxillary right lateral incisor (Fig 6). The maxillary posterior teeth were noted to be positioned mesially. The patient specifically requested an “invisible” orthodontic treatment to be performed on a non-extraction basis. The treatment plan involved bilateral distalisation with the Beneslider and simultaneous use of aligners (one-phase approach). After insertion of a Beneslider (Fig 7a), digital scans were taken for fabrication of clear aligners (Invisalign, Align Technology, San Jose, CA, USA). As soon as the aligners were delivered, treatment began with the distalisation appliance being activated by gently compressing the lock onto the NiTi spring (240 g) (Fig 7b). After 2.5 (Fig 7c) and 4 (Fig 7d) months of active distalisation, several small spaces were visible between the maxillary teeth and more space was gained for the maxillary right lateral incisor. As soon as the molars were in a Class I occlusion, all spaces were closed distally. The treatment was completed after 10 months, including reshaping of the maxillary right lateral incisor (Fig 8). The panoramic radiograph shows the bodily distalisation of all the maxillary lateral teeth (Fig 8b).

Space closure/mesialisation

Unilateral or bilateral missing maxillary teeth are encountered frequently in clinical practice. The aetiology of hypodontia includes congenitally missing lateral incisors/second premolars, significant ectopic displacement of maxillary canines and dentoalveolar trauma resulting in anterior tooth loss. The treatment options available to address



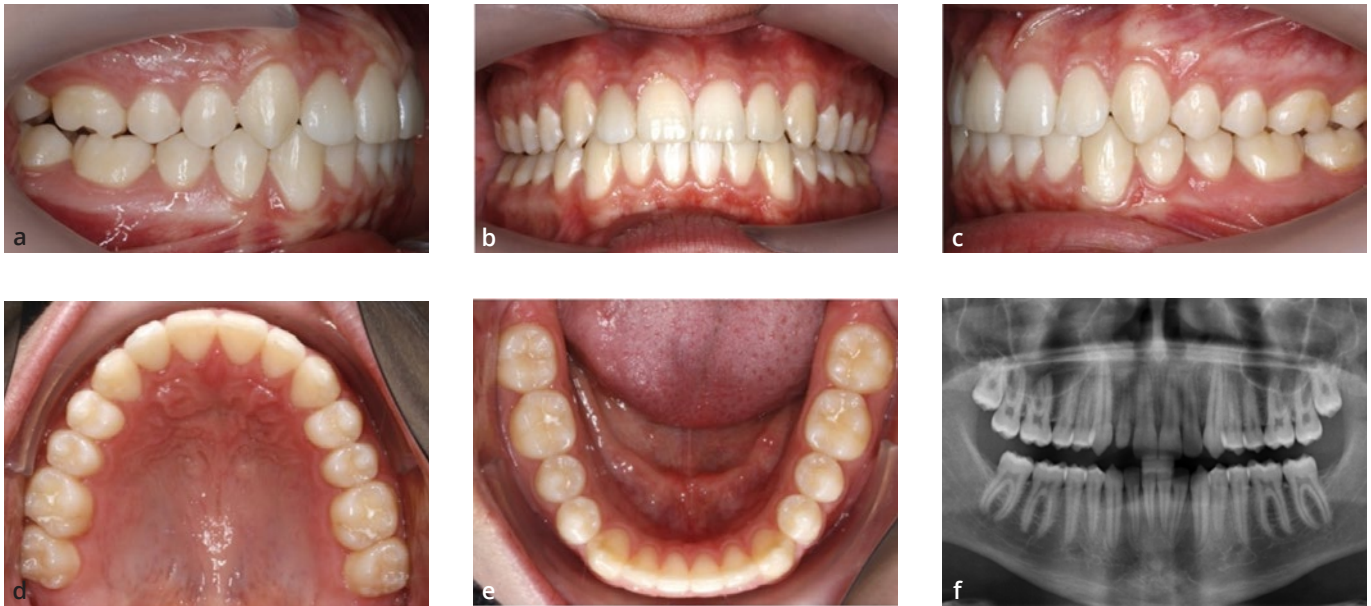Figs 6a-f Clinical case 1: a 12-year-old boy with anterior crowding, midline deviation and a peg-shaped maxillary right lateral incisor.



Figs 7a-d Insertion of a Beneslider (a), simultaneous use of aligners and the Beneslider (b), and the situation after 2.5 months (c) and 4 months (d) of active distalisation.

missing teeth are space closure or space opening with a view to performing subsequent prosthetic replacement. Both of these treatment approaches can influence the overall aesthetics, periodontal health and function of the final occlusal result³³. Single-tooth osseointegrated implants in the anterior maxilla have the highest reported risk of aesthetic complications from infrapositioning due to continuing facial growth and eruption of the adjacent teeth^{34,35}. In

many cases, achieving space closure mesially and protraction of the maxillary posterior teeth seem to be the prioritised treatment objectives. Class III elastics have been used to augment anchorage in cases with a missing maxillary tooth; however, this anchorage modality requires a high level of patient compliance and may result in the side effects described above. The Mesialslider^{27,28,36} was introduced as a mechanism to achieve sliding mechanics using



Figs 8a-f Treatment results after 10 months. (a to e) Intraoral photographs. (f) Panoramic radiograph showing bodily distalisation of all the maxillary lateral teeth.

mini-implants in the anterior palate, and enables the clinician to mesialise or protract the maxillary molars and thus close spaces in the arch, either unilaterally or bilaterally, without the need for additional buccal brackets³⁷. The appliance is versatile, and contralateral distalisation of teeth is possible (Mesial-Distalslider)^{38,39}. As an alternative to the conventional Mesialslider which is only attached to the molars, an additional force can be added to premolars using bonded tubes (B-Mesialslider)⁴⁰.

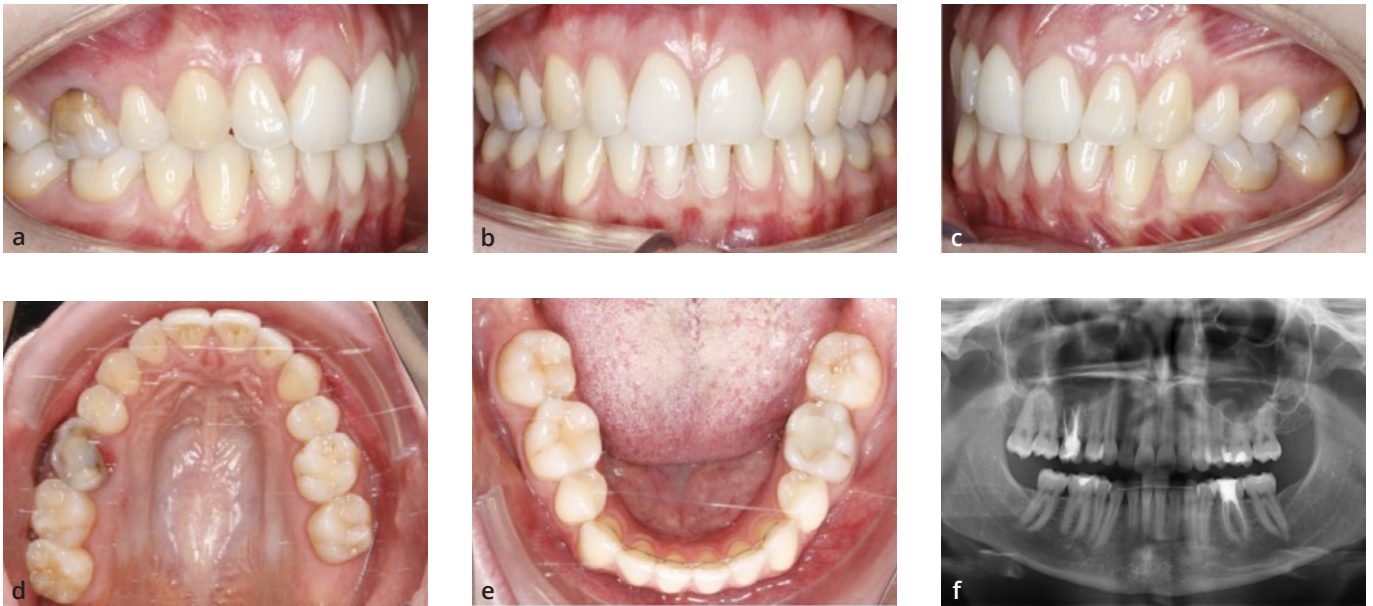
Clinical case 2 using the Mesialslider

The treatment protocol for a 25-year-old woman with a congenitally missing maxillary right second premolar is illustrated in Fig 9. The primary molar remained in place but was to be extracted due to its poor prognosis (Fig 9b). Following presentation of the treatment options and consideration of alternatives, the patient provided informed consent to proceed with an aesthetic orthodontic treatment option with a view to achieving space closure. The treatment began with the insertion of two mini-implants (2 x 9 mm anterior and 2 x 7 mm posterior, BENEFit, PSM, Gunningen, Germany) positioned in the midline of the anterior palate (Fig 10a), and the Mesialslider (Fig 10b).

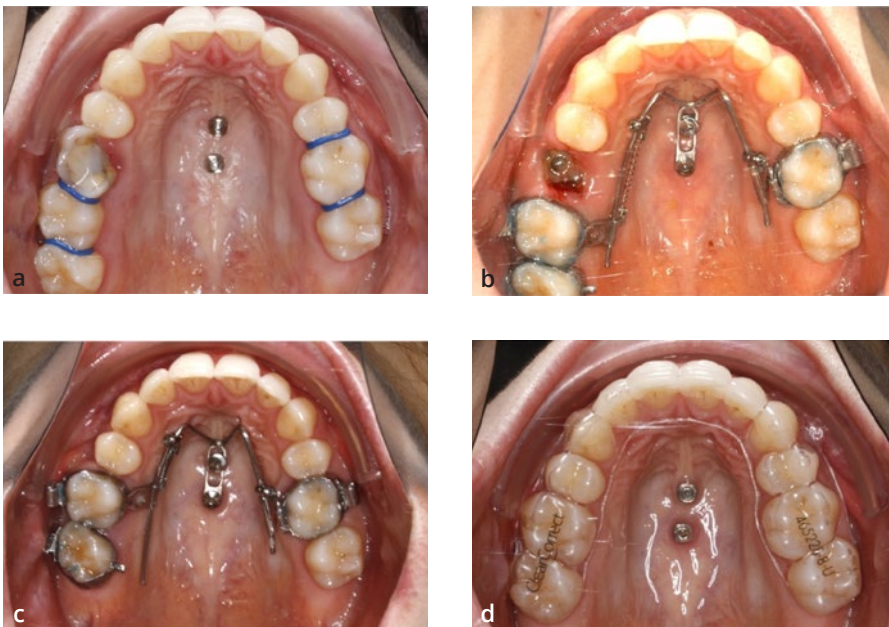
Extraction of the primary molar was deferred until immediately before treatment began in order to facilitate expedient space closure (owing to the underlying expected regional acceleratory phenomenon). The mesialisation springs (NiTi, 250 g) were activated immediately after insertion of the Mesialslider (two-phase approach). After 10 months, significant mesial bodily movement of the maxillary right molars was noted (Fig 10c). The Mesialslider was removed and impressions were taken to facilitate detailing of the occlusion with clear sequential plastic aligners (Fig 10d). A thermoformed splint was worn at nighttime during the interval between removal of the Mesialslider and fabrication of the aligners. The second phase of treatment was completed with aligners for detailing and finishing the occlusion (ClearCorrect, Round Rock, TX, USA). The treatment was completed over a 15-month period (Fig 11a). Radiographic findings and intraoral images showed optimal bodily mesialisation (Fig 11b).

Clinical case 3 using a Mesial-Distalslider

The treatment protocol for a 45-year-old woman with Class II malocclusion and a missing maxillary right first



Figs 9a-f Clinical case 2: a 25-year-old woman with a congenitally missing maxillary right second premolar.

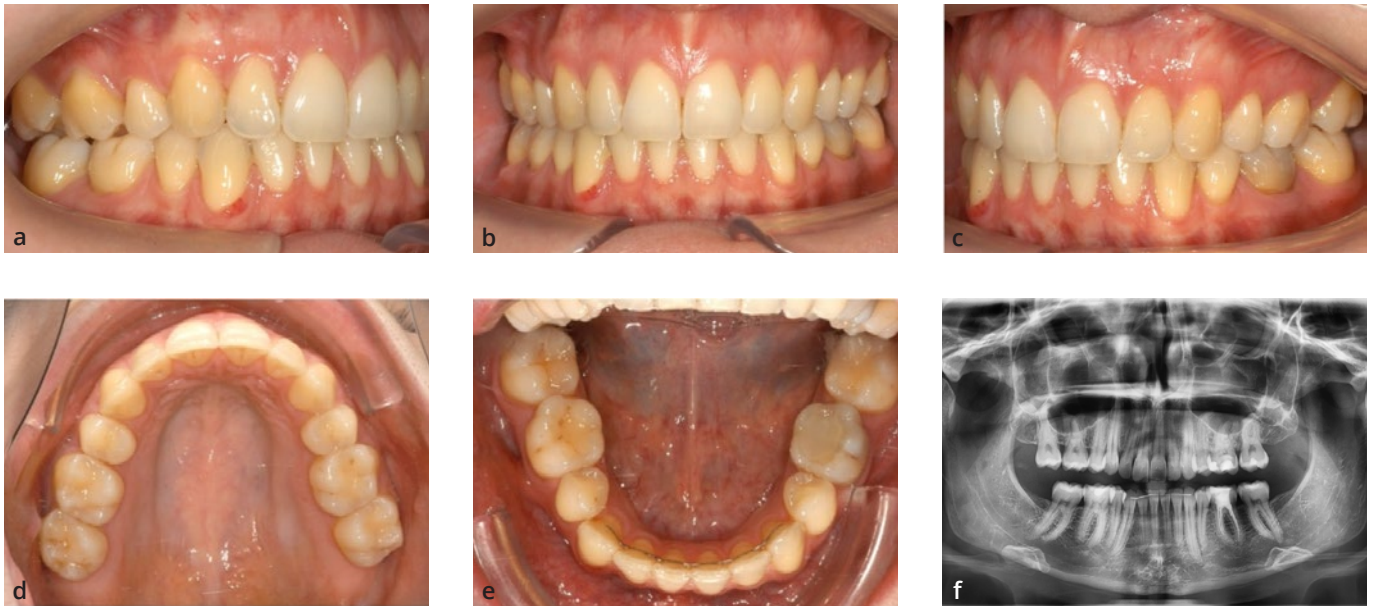


Figs 10a-d (a) Insertion of mini-implants in the anterior palate, (b) placement of the Mesial-Distal slider, (c) space closure after 10 months and (d) detailing of the occlusion with clear sequential plastic aligners.

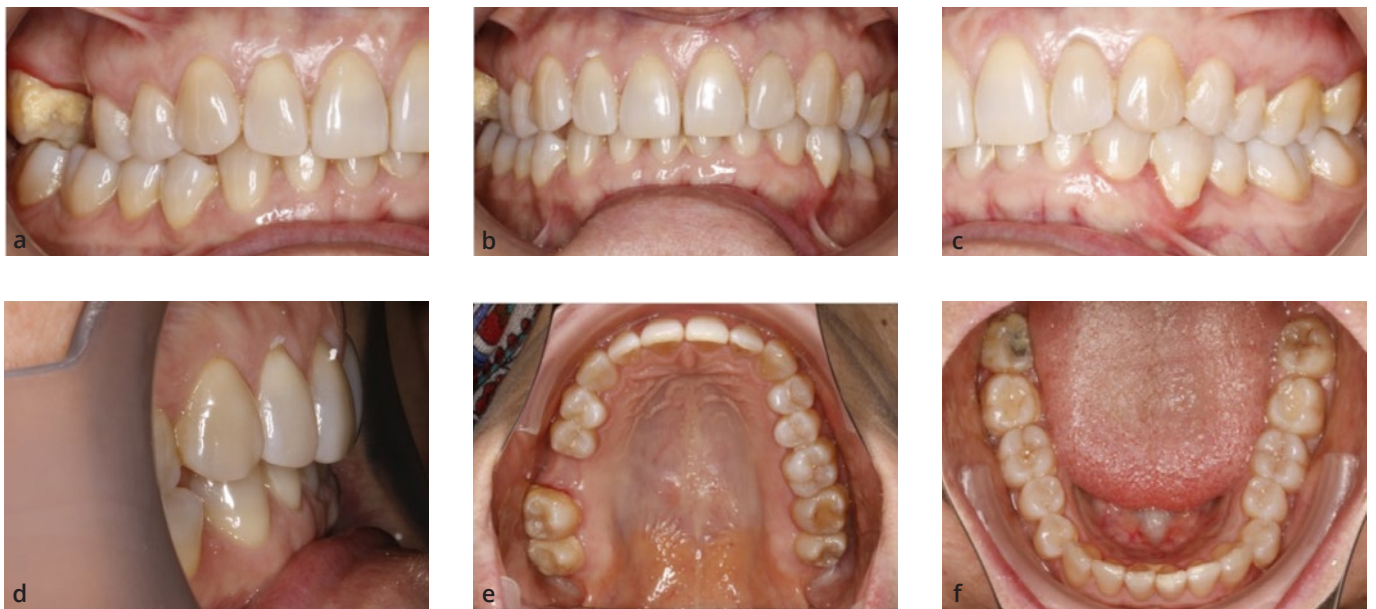molar is illustrated in Fig 12. The patient specifically requested an “invisible” orthodontic treatment option including space closure in the first quadrant. Consequently, the two-phase treatment plan consisted of distalisation of all premolars in both maxillary quadrants and the molars in the second quadrant to correct the Class II malocclusion. Additionally, the molars in the first quadrant were to be

mesialised for space closure. In the second phase, aligners were to be inserted for finishing.

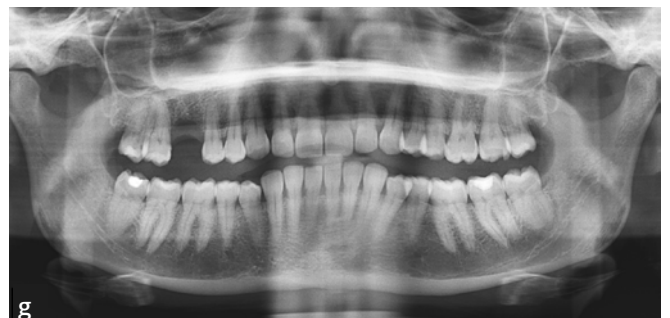After placement of two mini-implants (2 x 9 mm anterior and 2 x 7 mm posterior), the Mesial-Distal slider was inserted (Fig 13a). In the second quadrant, a 240-g distalisation spring was placed, and in the first quadrant, space closure was initiated with a reciprocal force application

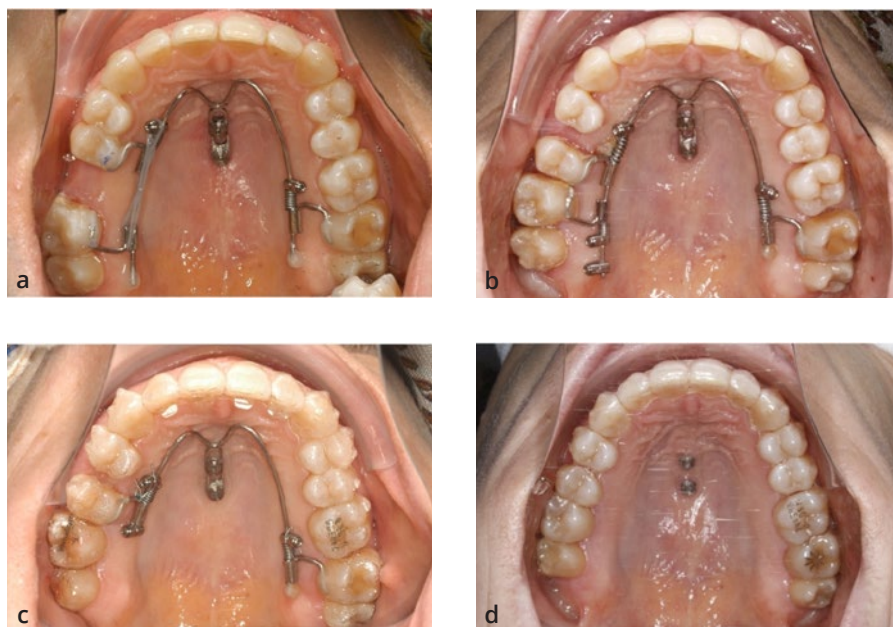


Figs 11a-f Treatment results after 15 months. (a to e) Intraoral photographs. (f) Panoramic radiograph showing optimal bodily mesialisation.

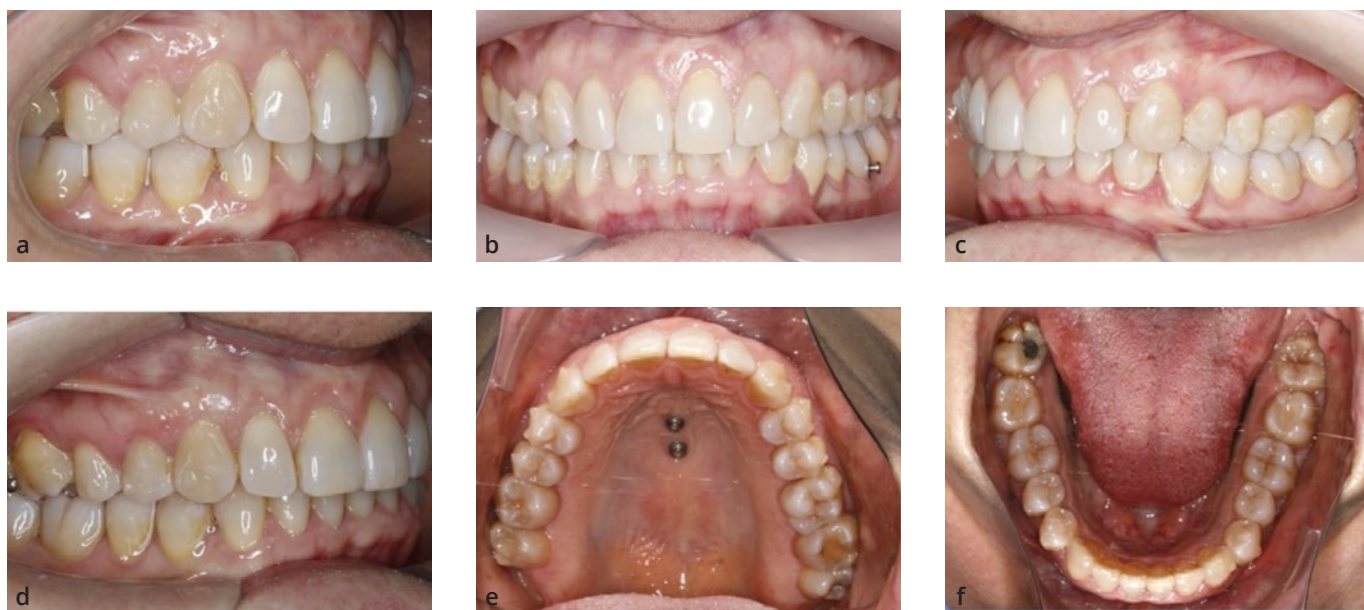


Figs 12a-g Clinical case 3: a 45-year-old woman with Class II malocclusion and a missing maxillary right first molar.





Figs 13a-d (a) Insertion of the Mesial-Distalslider, (b) 10-month follow-up and (c and d) second phase of aligner treatment.

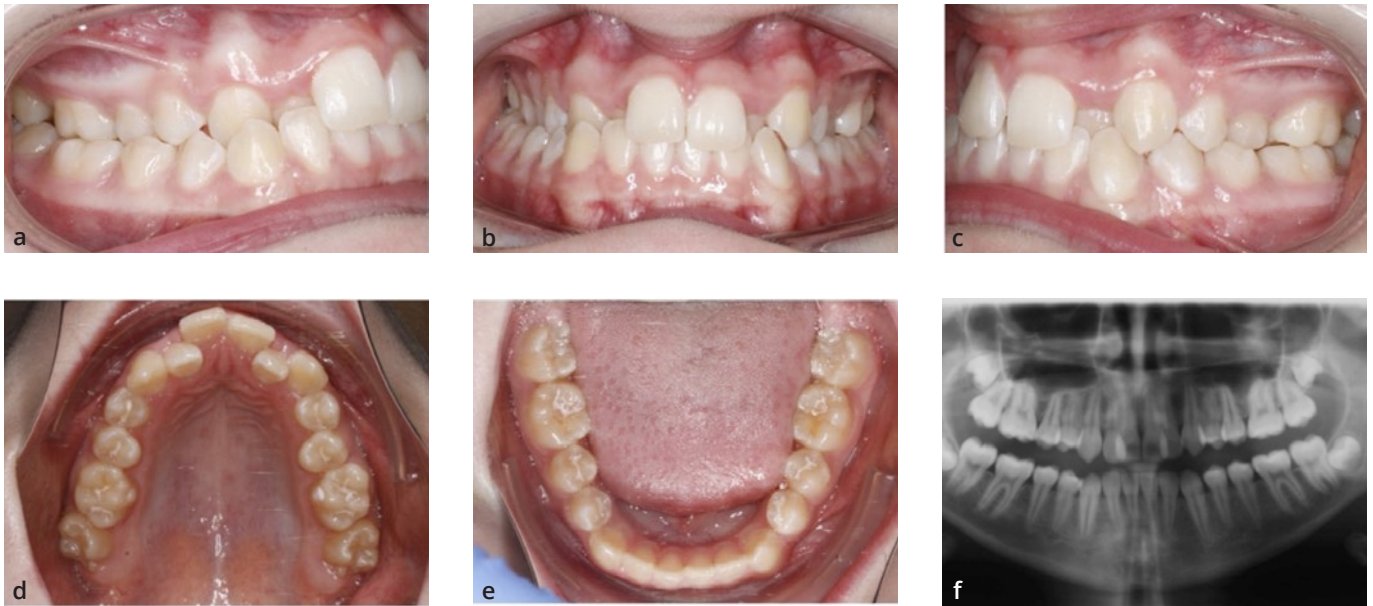

Figs 14a-f Treatment results after 20 months.

using an elastic chain (Fig 13a), then later using open springs (Fig 13b). The bodily space closure took 10 months (Fig 13b). The second phase of treatment involved finishing with Invisalign aligners (Figs 13c and d). After the total treatment time of 20 months, all spaces were closed and a Class I occlusion was achieved (Fig 14).

Maxillary expansion

Rapid maxillary expansion (RME; also known as rapid palatal expansion, RPE) is considered the optimal procedure to achieve skeletal widening of the maxilla^{41,42}. Since the forces are distributed to the bony structures via the anchor teeth, their distribution to as many teeth as possible and completion of root growth are considered essential;

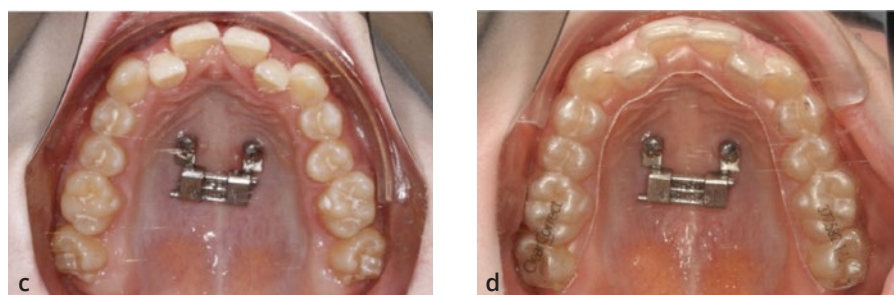
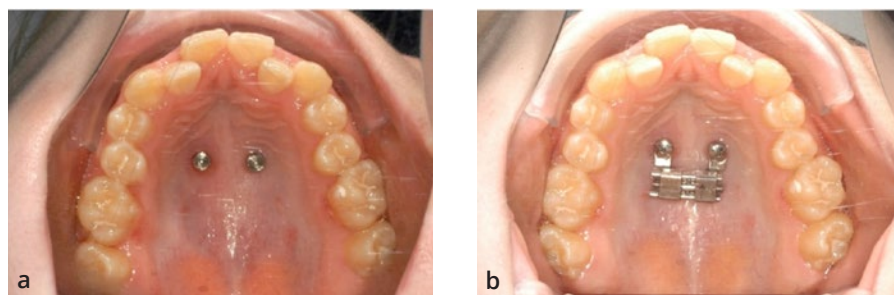


Figs 15a-f Clinical case 4: a 13-year-old girl with a severe maxillary transverse deficiency.

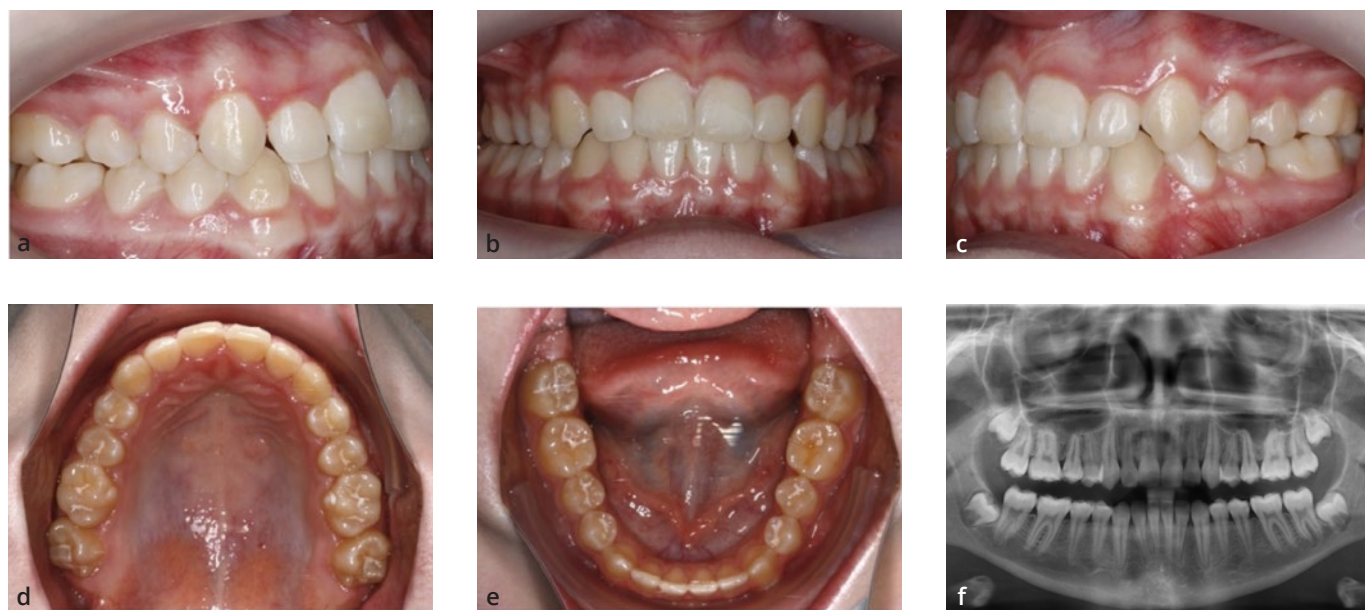however, side effects such as tooth tipping, root resorption, a decrease in buccal bone thickness, buccal bone dehiscence and loss of marginal bone height, resulting in gingival recession, may occur⁴³⁻⁴⁶. More recently, mini-implants have been used to share the load of the expansion with the anchor teeth to reduce or eliminate the unwanted dental side effects. Wilmes et al^{14,27,47,48} introduced the Hybrid Hyrax expander in 2007 using two mini-implants in the anterior palate and two (primary) molars. Similar expanders were introduced subsequently by Garib et al⁴⁹ in 2008, Lee et al⁵⁰ in 2010 and Moon et al⁵¹ in 2015 and called maxillary skeletal expanders (MSEs). In the conventional Hybrid Hyrax, the mini-implants and molars are used as anchors for RME; however, if a patient is treated with aligners, it seems advantageous to avoid any connection with the dentition, with the aim of aligning all teeth free from interference, with an expander that must stay in the mouth for retention. Consequently, pure bone-borne expanders were established using two (Benefit Maxillary Xpander [BMX], PSM) or four (Quadexpander) mini-implants.

Clinical case 4 using two mini-implants and a BMX

A 13-year-old girl presented with a severe maxillary transverse deficiency (Fig 15). She and her parents requested an aligner treatment and made an informed decision to proceed with a treatment using a mini-implant-borne expander in the maxilla and aligners to level the teeth afterwards. The treatment began with insertion of two mini-implants (2 x 9 mm) in the anterior palate under local anaesthesia (Fig 16a). A prefabricated BMX (8 mm) was adapted by pre-turning the expansion screw directly chair-side and fixed with two fixation screws (Fig 16b). Expansion activation was initiated by performing one activation per day to achieve a total of around 0.2 mm expansion each day. After 4 weeks of activation, approximately 5.5 mm maxillary expansion had been achieved (Fig 16c). Subsequently, scans were taken for aligner finishing (ClearCorrect). The BMX stayed in place for skeletal retention (Fig 16d). The aligner treatment was completed after 10 months (Fig 17). The total treatment duration was 12 months (1 month expansion, 1 month aligner manufacturing, 10 months aligner finishing).



Figs 16a-d (a) Insertion of two mini-implants in the anterior palate, (b) BMX, (c) maxillary expansion after 4 weeks of activation and (d) subsequent aligner finishing.

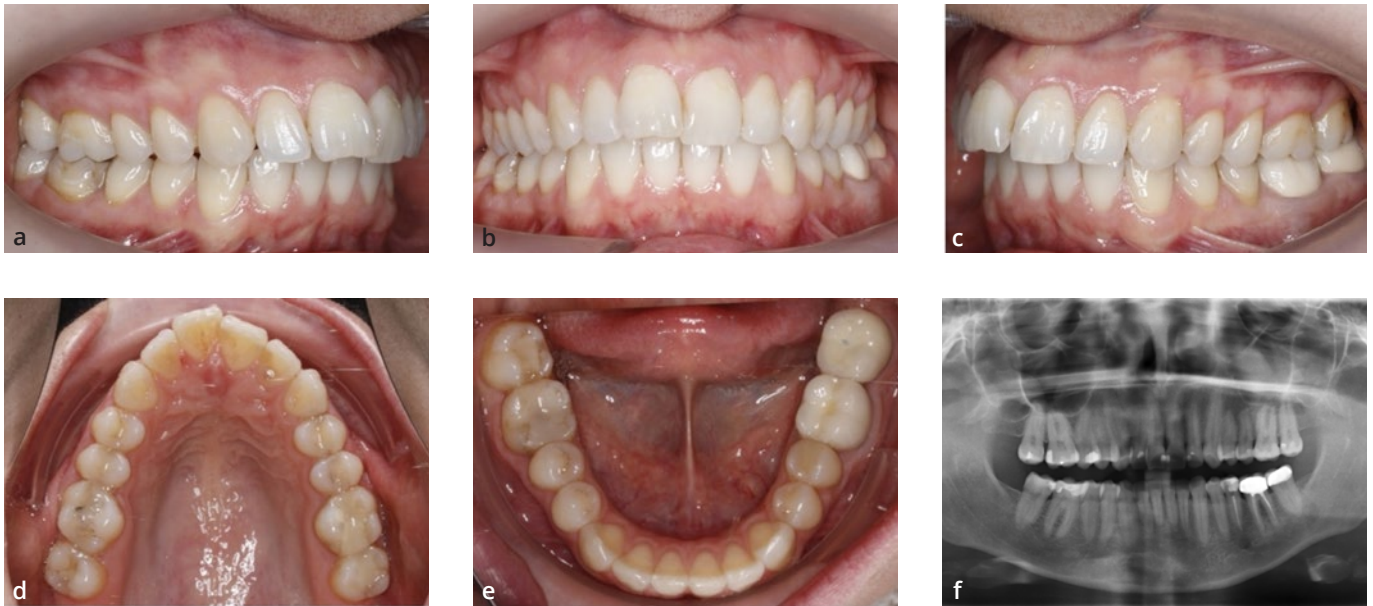


Figs 17a-f Treatment results after 10 months.

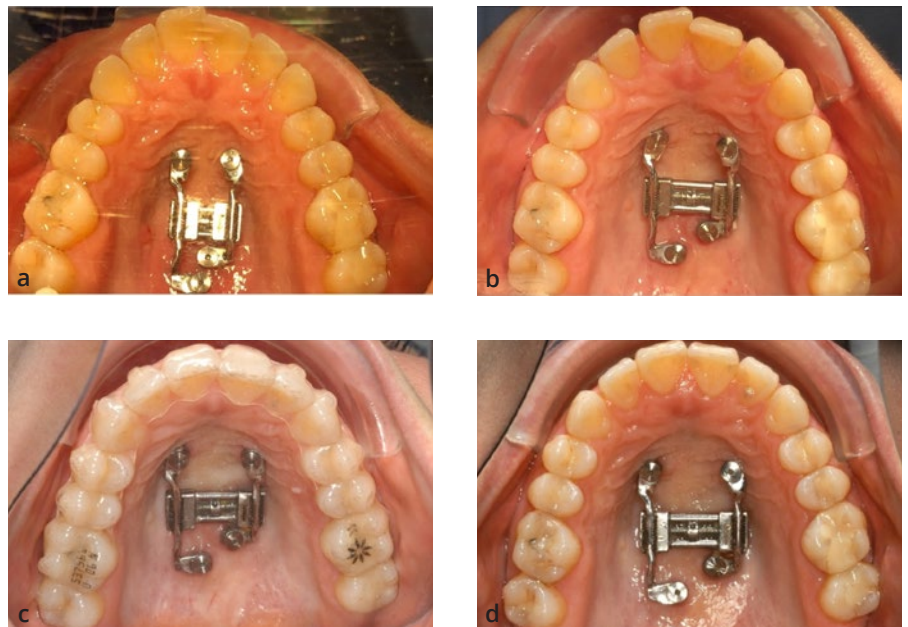Clinical case 5 using four mini-implants and a Quadexpander

A 37-year-old woman with a Class II malocclusion presented with a maxillary transverse deficiency (Fig 18). She requested an aligner treatment and made an informed decision to proceed with a treatment involving use of a mini-implant-borne expander in the maxilla and aligners for the

Class II treatment and levelling of the teeth afterwards. The treatment began with insertion of four mini-implants (2 x 9 mm anterior and 2 x 7 mm posterior) in the palate and a scan to manufacture the Quadexpander^{46,47} in a laboratory. After insertion of the Quadexpander (Fig 19a), activation was initiated by performing one activation per day to achieve a total of around 0.2 mm expansion each day. After 4 weeks of activation, approximately 5.0 mm maxillary



Figs 18a-f Clinical case 5: a 37-year-old woman with Class II malocclusion and a maxillary transverse deficiency.



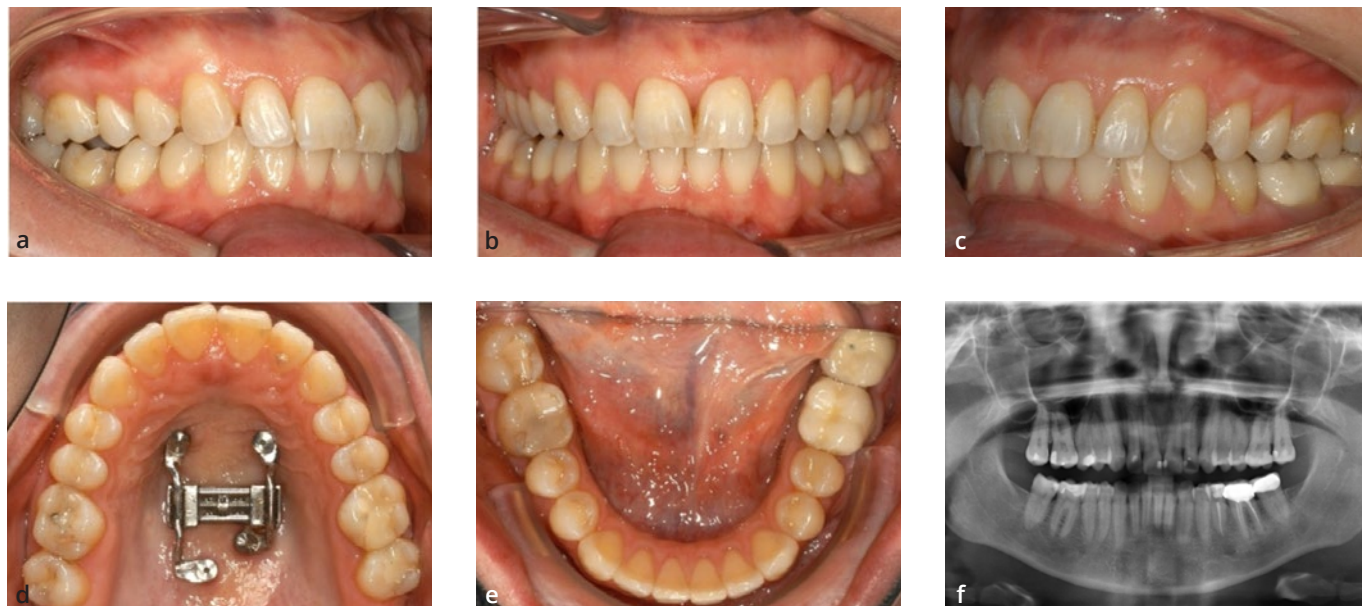
Figs 19a-d (a) Insertion of the Quad-expander; (b) after 4 weeks of activation; (c) aligner treatment; (d) the Quad-expander remained in place for skeletal retention.

expansion had been achieved without any surgical assistance (Fig 19b). Subsequently, scans were taken for the aligner treatment using Class II elastics (Align Technology) (Fig 19c). The Quadexpander stayed in place for skeletal retention (Fig 19d). The treatment was completed after 12 months (Fig 20).

Discussion

Additional anchorage with palatal TADs

The anterior palate has proven to be a highly recommended insertion site where mini-implants with larger dimensions and higher stability^{52,53} can be placed in a region with high bone quality, thin overlying soft tissue and an almost



Figs 20a-f Treatment results after 12 months.

negligible risk of interference with teeth or potential root damage⁵⁴. The bone volume is reduced in the lateral and posterior areas of the palate^{55,56}. The area immediately distal to the third palatal rugae, referred to as the “T-zone”, remains the preferred region for insertion of palatal mini-implants⁵⁷. The two adjacent mini-implants in the anterior palate can be positioned in a sagittal (median insertion) or transverse (paramedian insertion) direction²⁸. Nowadays, paramedian insertion is preferred to avoid any inference with the incisive canals and suture⁵⁸ and because of the higher stability it offers⁵⁹.

Timing and staging: The simultaneous (one-phase) approach versus the consecutive (two-phase) approach

Our experience in using a TAD-borne appliance in conjunction with aligners originated with a two-phase approach⁹: the initial phase involved molar distalisation/mesialisation/expansion, and the second involved final detailing of the occlusion with aligners. In this two-phase approach, an impression or scan for aligners is taken after molar distalisation/space closure/expansion is completed. The approach does not require coordination of tooth movement with the slider and staging of tooth movement with the clear aligners, and fewer aligners can be used to achieve specific treatment objectives; however, alignment of the

anterior teeth and improvements that are visible to the patient only occur at a later stage of treatment.

To reduce the total treatment duration and start alignment of the anterior teeth sooner, simultaneous use of a TAD-borne slider and alignment with aligners seems advantageous. With a single, integrated approach, the impressions/scans for aligners are taken immediately after insertion of the slider. The tooth movement anticipated to be produced by the slider is programmed in the digital software platform. The potential drawback of this approach is the coordination between the slider and the tooth movements planned to be produced using the aligners. The wire of the slider has to be designed considering the anticipated movement curve of the dentition. A two-dimensional superimposition of the ClinCheck (Align Technology) and a picture of the slider may help to check and coordinate tooth movement in the horizontal plane. If the distalisation/mesialisation force and/or the rate of mesial molar movement are greater than the aligner staging, the fit and accuracy of the aligner may be compromised. Teeth that are connected with the slider will move parallel to the wire. Thus, rotation or tipping of these teeth cannot be integrated into the ClinCheck at this early stage of treatment; however, attachments are still important in order to have a proper connection between both appliances. The speed of the movement in the ClinCheck is anticipated based on the

usual rates of tooth movement. The rate of maxillary molar distal/mesial movement associated with the use of a slider is approximately 0.6 mm per month^{24,25}; this rate of molar speed, i.e. 0.15 mm per week, should be kept in mind when determining the appropriate aligner staging. In clinical reality, the slider probably acts as the pacemaker and the aligner potentially reduces the speed of tooth movement. All the other tooth movements are controlled by the aligners. According to the present clinical findings, sequential tooth movement is not required. The entire maxilla can be moved simultaneously due to the absolute anchorage provided by the mini-implant-borne appliance; the stretching of the interdental fibres supports the simultaneous drift of the teeth. On the other hand, sequential tooth movement may provide better tooth control as the aligners have more contact with the teeth to be moved. Thus, the present author recommends en masse distalisation/mesialisation with small spaces (semi-sequential tooth movement). Another point that should be noted is that when a refinement is planned and new aligners are ordered, the slider must be maintained in a passive state to ensure adaptation and fit of the aligners.

Conclusion

In conclusion, for maxillary molar distalisation cases, a two-stage approach is recommended for young patients due to its greater ease, and a one-stage approach is advisable for adults as the anterior teeth are aligned at an earlier stage. In space closure and expansion cases, a two-stage protocol seems favourable.

Declaration

The authors declare there are no conflicts of interest relating to this study.

References

- Buschang PH, Chastain D, Keylor CL, Crosby D, Julien KC. Incidence of white spot lesions among patients treated with clear aligners and traditional braces. *Angle Orthod* 2019;89:359–364.
- Papadimitriou A, Mousoulea S, Gkantidis N, Kloukos D. Clinical effectiveness of Invisalign(R) orthodontic treatment: a systematic review. *Prog Orthod* 2018;19:1–24.
- Ravera S, Castroflorio T, Garino F, Daher S, Cugliari G, Deregibus A. Maxillary molar distalization with aligners in adult patients: A multi-center retrospective study. *Prog Orthod* 2016;17:1–9.
- Bowman SJ, Celenza F, Sparaga J, Papadopoulos MA, Ojima K, Lin JC. Creative adjuncts for clear aligners, part 1: Class II treatment. *J Clin Orthod* 2015;49:83–94.
- Simon M, Keilig L, Schwarze J, Jung BA, Bourauel C. Forces and moments generated by removable thermoplastic aligners: Incisor torque, premolar derotation, and molar distalization. *Am J Orthod Dentofacial Orthop* 2014;145:728–736.
- Greco M, Rossini G, Rombolà A. G-Block: Posterior anchorage device tads-supported after molar distalization with aligners: An adult case report. *Int Orthod* 2022;20:1–12.
- Wilmes B, Tarraf N, Drescher D. Treatment of maxillary transversal deficiency by using a mini-implant-borne rapid maxillary expander and aligners in combination. *Am J Orthod Dentofacial Orthop* 2021;160:147–154.
- Wilmes B, Schwarze J, Vasudavan S, Drescher D. Maxillary space closure using aligners and palatal mini-implants in patients with congenitally missing lateral incisors. *J Clin Orthod* 2021;55:20–33.
- Wilmes B, Nienkemper M, Ludwig B, Kau CH, Pauls A, Drescher D. Esthetic Class II treatment with the Beneslider and aligners. *J Clin Orthod* 2012;46:390–398.
- Costa A, Raffaini M, Melsen B. Miniscrews as orthodontic anchorage: A preliminary report. *Int J Adult Orthodon Orthognath Surg* 1998;13:201–209.
- Kanomi R. Mini-implant for orthodontic anchorage. *J Clin Orthod* 1997;31:763–767.
- Melsen B, Costa A. Immediate loading of implants used for orthodontic anchorage. *Clin Orthod Res* 2000;3:23–28.
- Fritz U, Diedrich P, Kinzinger G, Al-Said M. The anchorage quality of mini-implants towards translatory and extrusive forces. *J Orofac Orthop* 2003;64:293–304.
- Wilmes B. Fields of application of mini-implants. In: Ludwig B, Baumgaertel S, Bowman J (eds). *Mini-Implants in Orthodontics: Innovative Anchorage Concepts*. Berlin, New York: Quintessence, 2008:91–122.
- Arqub SA, Gandhi V, Mehta S, Palo L, Upadhyay M, Yadav S. Survival estimates and risk factors for failure of palatal and buccal mini-implants. *Angle Orthod* 2021;91:756–763.
- Wilmes B, Olthoff G, Drescher D. Comparison of skeletal and conventional anchorage methods in conjunction with pre-operative decompensation of a skeletal class III malocclusion. *J Orofac Orthop* 2009;70:297–305.
- Ludwig B, Glasl B, Bowman SJ, Wilmes B, Kinzinger GS, Lisson JA. Anatomical guidelines for miniscrew insertion: palatal sites. *J Clin Orthod* 2011;45:433–441.
- Hourfar J, Bister D, Kanavakis G, Lisson JA, Ludwig B. Influence of interdental and palatal placement of orthodontic mini-implants on the success (survival) rate. *Head Face Med* 2017;13:1–6.
- Lim HJ, Choi YJ, Evans CA, Hwang HS. Predictors of initial stability of orthodontic miniscrew implants. *Eur J Orthod* 2011;33:528–532.
- Karagiolidou A, Ludwig B, Pazera P, Gkantidis N, Pandis N, Katsaros C. Survival of palatal miniscrews used for orthodontic appliance anchorage: A retrospective cohort study. *Am J Orthod Dentofacial Orthop* 2013;143:767–772.
- Wilmes B, Vasudavan S, Drescher D. CAD-CAM-fabricated mini-implant insertion guides for the delivery of a distalization appliance in a single appointment. *Am J Orthod Dentofacial Orthop* 2019;156:148–156.
- Graf S, Cornelis MA, Hauber Gameiro G, Cattaneo PM. Computer-aided design and manufacture of hyrax devices: Can we really go digital? *Am J Orthod Dentofacial Orthop* 2017;152:870–874.
- Wilhelmy L, Willmann JH, Tarraf NE, Wilmes B, Drescher D. Maxillary space closure using a digital manufactured Mesialslider in a single appointment workflow. *Korean J Orthod* 2022;52:236–245.

24. Becker K, Wilmes B, Grandjean C, Vasudavan S, Drescher D. Skeletally anchored mesialization of molars using digitized casts and two surface-matching approaches: Analysis of treatment effects. *J Orofac Orthop* 2018;79:11–18.
25. Nienkemper M, Wilmes B, Pauls A, Yamaguchi S, Ludwig B, Drescher D. Treatment efficiency of mini-implant-borne distalization depending on age and second-molar eruption. *J Orofac Orthop* 2014;75:118–132.
26. Simon M, Keilig L, Schwarze J, Jung BA, Bourauel C. Treatment outcome and efficacy of an aligner technique—Regarding incisor torque, premolar derotation and molar distalization. *BMC Oral Health* 2014;14:1–7.
27. Wilmes B, Drescher D. A miniscrew system with interchangeable abutments. *J Clin Orthod* 2008;42:574–580.
28. Wilmes B, Drescher D, Nienkemper M. A miniplate system for improved stability of skeletal anchorage. *J Clin Orthod* 2009;43:494–501.
29. Wilmes B, Drescher D. Application and effectiveness of the Beneslider molar distalization device. *World J Orthod* 2010;11:331–340.
30. Bayome M, Park JH, Bay C, Kook YA. Distalization of maxillary molars using temporary skeletal anchorage devices: A systematic review and meta-analysis. *Orthod Craniofac Res* 2021;24(suppl 1):103–112.
31. Wilmes B, Neuschulz J, Safar M, Braumann B, Drescher D. Protocols for combining the Beneslider with lingual appliances in Class II treatment. *J Clin Orthod* 2014;48:744–752.
32. Wilmes B, Katyal V, Willmann J, Stocker B, Drescher D. Mini-implant-anchored Mesialslider for simultaneous mesialisation and intrusion of upper molars in an anterior open bite case: A three-year follow-up. *Aust Orthod J* 2015;31:87–97.
33. Robertsson S, Mohlin B. The congenitally missing upper lateral incisor. A retrospective study of orthodontic space closure versus restorative treatment. *Eur J Orthod* 2000;22:697–710.
34. Zitzmann NU, Arnold D, Ball J, Brusco D, Triaca A, Verna C. Treatment strategies for infraoccluded dental implants. *J Prosthet Dent* 2015;113:169–174.
35. Oesterle LJ, Cronin RJ Jr, Ranly DM. Maxillary implants and the growing patient. *Int J Oral Maxillofac Implants* 1993;8:377–387.
36. Wilmes B, Nienkemper M, Nanda R, Lubberink G, Drescher D. Palatally anchored maxillary molar mesialization using the mesialslider. *J Clin Orthod* 2013;47:172–179.
37. Wilmes B, Vasudavan S, Drescher D. Maxillary molar mesialization with the use of palatal mini-implants for direct anchorage in an adolescent patient. *Am J Orthod Dentofacial Orthop* 2019;155:725–732.
38. Wilmes B, Drescher D. Application and effectiveness of the Beneslider: A device to move molars distally. *World J Orthod* 2010;11:331–340.
39. Wilmes B, Nanda R, Nienkemper M, Ludwig B, Drescher D. Correction of upper-arch asymmetries using the Mesial-Distalslider. *J Clin Orthod* 2013;47:648–655.
40. Wilmes B, Beykirch S, Ludwig B, Becker K, Willmann J, Drescher D. The B-Mesialslider for non-compliance space closure in cases with missing upper laterals. *Seminars in Orthodontics* 2018;24:66–82.
41. Kuroi J, Berglund L. Longitudinal study and cost-benefit analysis of the effect of early treatment of posterior cross-bites in the primary dentition. *Eur J Orthod* 1992;14:173–179.
42. Camacho M, Chang ET, Song SA, et al. Rapid maxillary expansion for pediatric obstructive sleep apnea: A systematic review and meta-analysis. *Laryngoscope* 2017;127:1712–1719.
43. Garib DG, Henriques JF, Janson G, de Freitas MR, Fernandes AY. Periodontal effects of rapid maxillary expansion with tooth-tissue-borne and tooth-borne expanders: A computed tomography evaluation. *Am J Orthod Dentofacial Orthop* 2006;129:749–758.
44. Schuster G, Borel-Scherf I, Schopf PM. Frequency of and complications in the use of RPE appliances—Results of a survey in the Federal State of Hesse, Germany. *J Orofac Orthop* 2005;66:148–161.
45. Erverdi N, Okar I, Kucukkeles N, Arbak S. A comparison of two different rapid palatal expansion techniques from the point of root resorption. *Am J Orthod Dentofacial Orthop* 1994;106:47–51.
46. Akyalcin S, Alexander SP, Silva RM, English JD. Evaluation of three-dimensional root surface changes and resorption following rapid maxillary expansion: A cone beam computed tomography investigation. *Orthod Craniofac Res* 2015;18(suppl 1):117–126.
47. Wilmes B. Anwendungsgebiete von Mini-Implantaten. In: Ludwig B (ed). *Mini-Implantate in der Kieferorthopädie - Innovative Verankerungskonzepte*. Berlin: Quintessence, 2007:89–120.
48. Wilmes B, Nienkemper M, Drescher D. Application and effectiveness of a mini-implant- and tooth-borne rapid palatal expansion device: The hybrid hyrax. *World J Orthod* 2010;11:323–330.
49. Garib DG, Navarro R, Francischone CE, Oltramari PV. Rapid maxillary expansion using palatal implants. *J Clin Orthod* 2008;42:665–671.
50. Lee KJ, Park YC, Park JY, Hwang WS. Miniscrew-assisted nonsurgical palatal expansion before orthognathic surgery for a patient with severe mandibular prognathism. *Am J Orthod Dentofacial Orthop* 2010;137:830–839.
51. Moon W, Wu KW, MacGinnis M, et al. The efficacy of maxillary protraction protocols with the micro-implant-assisted rapid palatal expander (MARPE) and the novel N2 mini-implant-a finite element study. *Prog Orthod* 2015;16:1–14.
52. Wilmes B, Ottenstreuer S, Su YY, Drescher D. Impact of implant design on primary stability of orthodontic mini-implants. *J Orofac Orthop* 2008;69:42–50.
53. Wilmes B, Drescher D. Impact of bone quality, implant type, and implantation site preparation on insertion torques of mini-implants used for orthodontic anchorage. *Int J Oral Maxillofac Surg* 2011;40:697–703.
54. Ludwig B, Glasl B, Bowman SJ, Wilmes B, Kinzinger GS, Lisson JA. Anatomical guidelines for miniscrew insertion: palatal sites. *J Clin Orthod*;45:433–441.
55. Kang S, Lee SJ, Ahn SJ, Heo MS, Kim TW. Bone thickness of the palate for orthodontic mini-implant anchorage in adults. *Am J Orthod Dentofacial Orthop* 2007;131:S74–S81.
56. Hourfar J, Kanavakis G, Bister D, et al. Three dimensional anatomical exploration of the anterior hard palate at the level of the third ruga for the placement of mini-implants—A cone-beam CT study. *Eur J Orthod* 2015;37:589–595.
57. Becker K, Unland J, Wilmes B, Tarraf NE, Drescher D. Is there an ideal insertion angle and position for orthodontic mini-implants in the anterior palate? A CBCT study in humans. *Am J Orthod Dentofacial Orthop* 2019;156:345–354.
58. Wilmes B, Ludwig B, Vasudavan S, Nienkemper M, Drescher D. The t-zone: Median vs. paramedian insertion of palatal mini-implants. *J Clin Orthod* 2016;50:543–551.
59. Nienkemper M, Wilmes B, Pauls A, Drescher D. Mini-implant stability at the initial healing period: A clinical pilot study. *Angle Orthod* 2014;84:127–133.