

RESEARCH

Open Access



# Early Class III treatment with Hybrid-Hyrax-Facemask in comparison to Hybrid-Hyrax-Mentoplate – skeletal and dental outcomes

Jan H. Willmann<sup>1</sup>, Manuel Nienkemper<sup>1,3\*</sup>, Nour Eldin Tarraf<sup>2</sup>, Benedict Wilmes<sup>1</sup> and Dieter Drescher<sup>1</sup>

## Abstract

**Background:** Protraction of maxilla is usually the preferred and more commonly used treatment approach for skeletal Class III with a retrognathic maxilla. The aim of this study was the comparison of the skeletal and dental effects of two skeletally borne appliances for maxillary protraction: a) Hybrid-Hyrax in combination with facemask (FM), b) Hybrid-Hyrax in combination with Mentoplate (ME).

**Methods:** Thirty four Patients (17 facemask, 17 Mentoplate) were investigated by means of pre- and posttreatment cephalograms. The two groups matched with regard to treatment time, age gender and type of dentoskeletal deformity before treatment.

**Results:** Both groups showed a significant forward movement of A-point (FM GROUP: SNA + 2.23° ± 1.30°— *p* 0.000\*; ME: 2.23° ± 1.43°— *p* 0.000\*). B-Point showed a larger sagittal change in the FM Group (SNB 1.51° ± 1.1°— *p* 0.000\*) compared to the ME group (SNB: − 0.30° ± 0.9°— *p* 0.070). The FM group showed a significant increase of the ML-NL + 1.86° ± 1.65° (*p* 0.000\*) and NSL-ML + 1.17° ± 1.48 (*p* 0.006\*). Upper Incisor inclination did not change significantly during treatment in both groups as well as the distance of the first upper Molar in relation to A-point.

**Conclusion:** Both treatments achieve comparable rates of maxillary protraction, without dentoalveolar side effects. Skeletal anchorage with symphyseal plates in the mandible provides greater vertical control and might be the treatment of choice in high angle patients.

**Keywords:** Class III, Facemask, Mini-plates, Skeletal anchorage, Rapid maxillary expansion

## Background

Morphological features of skeletal class III malocclusion may comprise mandibular prognathism, maxillary retrognathism or a combination of both. Cross-sectional studies revealed a prevalence of class III patients with a retrusive maxilla between 32 and 63%, depending on the investigated population, ethnicity, and sex [1–3]. In these patients, protraction of the deficient maxilla represents a causal treatment approach [3–11].

Sagittal orthopaedic forces to protract the maxillary complex were commonly applied to the upper dental arch [6, 12, 13]. This approach incurred well-known side effects such as proclination of the upper front teeth, bite

opening, mesial movement of the lateral segments, and constriction of unerupted canines [14–18].

New skeletal anchorage concepts involving surgical mini-plates or mini-implants have been developed to address these problems [19–21]. Directing orthopaedic forces directly into the bony structures of the midface promised a significant reduction of dental side effects as well as an enhancement of skeletal response. To further increase orthopaedic treatment effects, some maxillary protraction protocols include rapid maxillary expansion (RME) in order to stimulate the midface sutures [12, 18, 22]. Interestingly, systematic reviews and meta-analyses representing a high level of evidence either advocate or dismiss the positive effect of RME [10, 23–25]. RME can be carried out purely bone-borne or with a combination of dental and skeletal anchorage using mini-implants in the anterior palate (Hybrid-Hyrax).

\* Correspondence: Manuel.Nienkemper@uni-duesseldorf.de

<sup>1</sup>Department of Orthodontics, Heinrich-Heine-University, Kasernenstr. 1, 40213 Düsseldorf, Germany

<sup>3</sup>Private Practice, Düsseldorf, Germany

Full list of author information is available at the end of the article

Traditionally, maxillary protraction has been performed by extraoral traction using various types of facemasks [26, 27]. The associated skeletal treatment effects have been documented extensively in numerous clinical studies: advancement and anterior rotation of the maxilla, sagittal growth inhibition and posterior rotation of the mandible, and increase of the vertical dimension [28–30].

As an alternative, skeletal anchorage in the lower jaw eliminates the need for extraoral devices, which might have a positive effect on patient's acceptance and compliance. The Mentoplate, which was used for maxillary protraction in one study group, is inserted subapical to the lower incisors and can be inserted prior to canine eruption [31].

The aim of this retrospective study was to investigate the skeletal and dental effects of two skeletally borne appliances for maxillary protraction: (a) Hybrid-Hyrax in combination with facemask (FM) and (b) Hybrid-Hyrax in combination with Mentoplate (ME) (Fig. 1). The null hypothesis was that there is no difference regarding the skeletal and dental effects between the different treatment modalities.

## Methods

Initially, a group of 50 consecutively treated patients was considered for this study.

Inclusion criteria were as follows:

- Moderate/severe class III: WITS  $\leq -2.0$  mm
- Age  $\geq 7$  years to  $\leq 12$  years
- Treated according to a standardised protocol (see below)
- Lateral cephalograms before and after treatment
- Anterior crossbite or incisor edge-to-edge relationship, class III molar relationship

Exclusion criteria were as follows:

- Craniofacial anomalies
- Systemic diseases
- Forced or functional bite

Thirty-four patients (17 facemask, 17 Mentoplate) fulfilled the inclusion/exclusion criteria. The group compositions can be found in Tables 1 and 2.

**Table 1** Group allocation

	Male	Female	Total
Facemask	8	9	17
Mentoplate	7	10	17
Total	15	19	34

Chi-square 0.500 n.s

## Treatment protocol

A Hybrid-Hyrax device fitted on two paramedian mini-implants in the anterior palate ( $2 \times 9$  mm, Benefit, PSM, Tuttlingen, Germany) for RME was used in all patients. RME was performed activating the Hyrax screw by  $90^\circ$  turns four times a day, resulting in an expansion of 0.8 mm per day (Fig. 2).

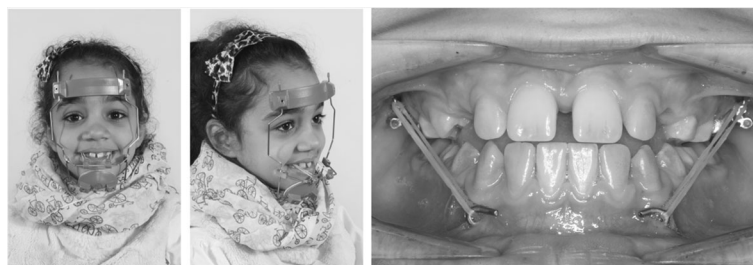The Mentoplate (PSM, Tuttlingen, Germany) was surgically inserted at the department for oral surgery under local anaesthesia 2 weeks prior to RME. Protraction was started simultaneously with RME in both groups.

The FM group was instructed to wear 400 g elastics on each side for 14–16 h per day [6, 11, 32]. The force vector of the elastics, between the FM and the Hybrid-Hyrax, was adjusted to have an inclination of  $20\text{--}30^\circ$  relative to the occlusal plane (Fig. 3). The ME group was instructed to wear 200 g elastics on each side, between the Hybrid-Hyrax and the Mentoplate, for 24 h per day. Cl. III elastics were worn with an inclination of  $10\text{--}15^\circ$  relative to the occlusal plane (Fig. 4).

## Cephalometric analysis

Digital pre- (T0) and posttreatment cephalograms (T1) (Sirona Orthopos XG plus; Bensheim, Germany) were calibrated and analysed. Measurements and superimpositions according to stable cranial structures the anterior border of Sella and median border of the orbital roof were performed by the same operator using the Software ImageCollector. Blinding of the operator was only possible for the pre-treatment cephalograms, since the Mentoplate was still in place in all of the post-treatment radiographs.

Cephalometric landmarks and planes and their definitions are presented in Fig. 5 and Table 3. Fifteen



**Fig. 1** Exemplary presentation of a patient wearing a facemask (left) and a Mentoplate (right)

**Table 2** Age distribution

	Age
Facemask	8.74 ± 1.20
Mentoplate	9.43 ± 0.95
T test	0.072 n.s.

randomly selected cephalograms were retraced on two different occasions within a 2-week interval by one examiner. The intraclass correlation coefficient (ICC) ranged between 0.93 and 0.98.

### Statistics

Statistical analysis was carried out using SPSS (IBM, Version 23). Measurements were tested for normal distribution using the Shapiro-Wilk test. Depending on these tests, statistical comparison of mean values was carried out using parametric or non-parametric tests, respectively. Intra-group differences were identified using Student's *t* test for dependent samples or Wilcoxon test. Differences between the groups were tested using *t* test for independent samples or Mann-Whitney *U* test. The confidence interval was set to 95%.

### Results

Treatment time, age and gender distribution did not show significant differences between the groups. (Tables 1, 2 and 4). Initial cephalometric values revealed did not differ significantly at T0 (Table 3).

The skeletal effects for each group are shown in Tables 5 and 6. The differences between the groups are shown in Table 7.

Anterior and posterior crossbites were corrected in all individuals. Neither implant or plate failures nor break-ages of the appliances occurred.

### Discussion

The main goal of early class III treatment of patients with maxillary retrognathia is to achieve maxillary protraction and growth restriction of the mandible without undesirable side effects such as mesial migration of the upper dentition and vertical skeletal changes.

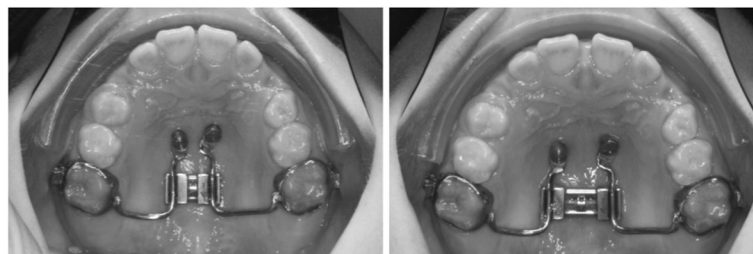
Various different strategies exist to achieve these objectives:

- The BAMP (Bone anchored Maxillary Protraction) protocol [19]
- The Miniscrew Implants/Facemask combination [33, 34]
- Two miniplates laterally to the aperture piriformis in conjunction with a facemask [35]
- The Hybrid-Hyrax Facemask/Mentoplate combination [31, 36]

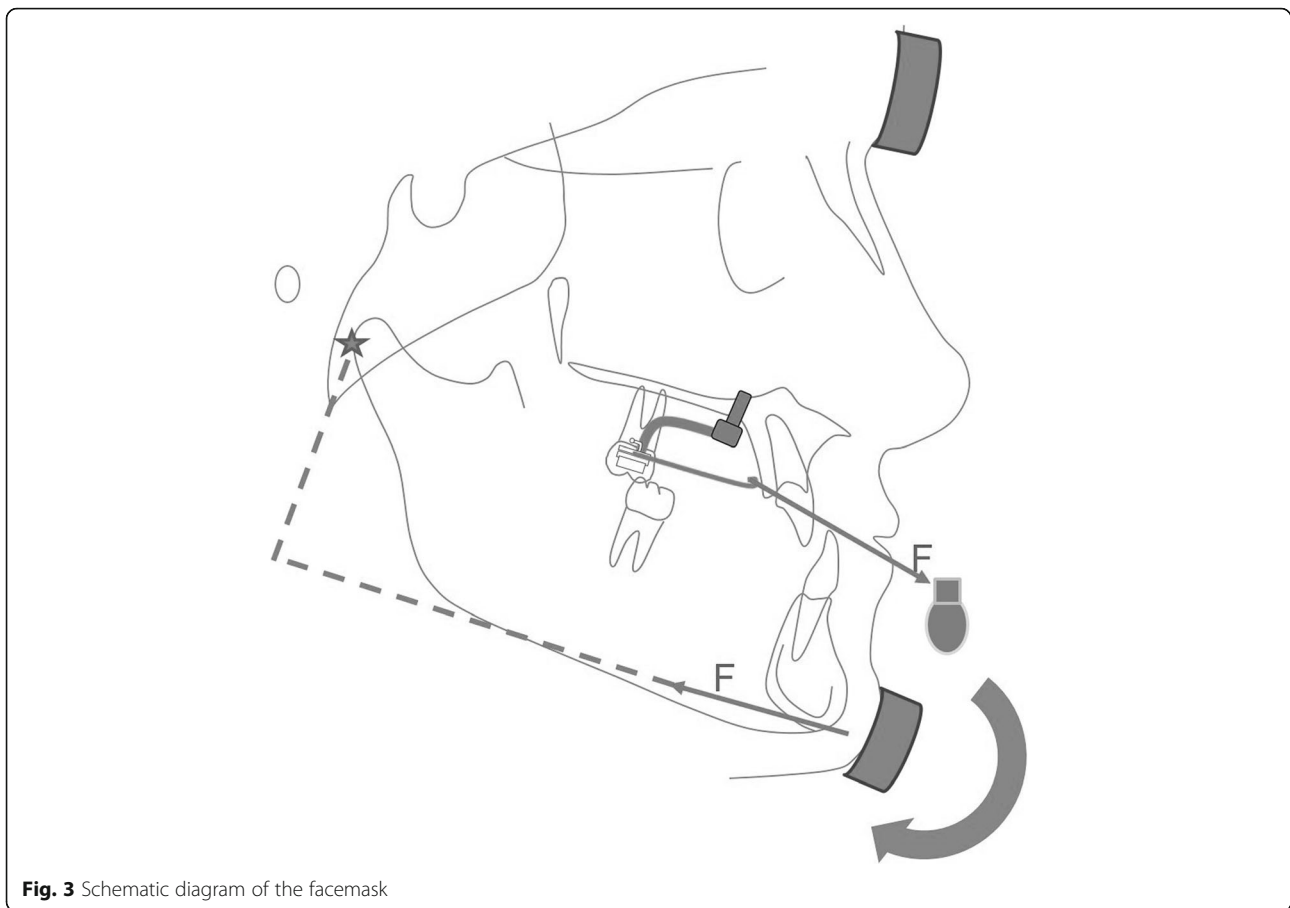
which was examined in this retrospective study. The groups were comparable regarding their skeletal pattern, age, sex, and treatment time. The review of the confidence interval show, that a sufficient number of patients were evaluated. The significant differences are thereby supported by alpha and beta errors.

Maxillary protraction was carried out successfully in both groups, leading to a significant improvement of the maxillary position. In both groups, similar changes were induced regarding the SNA-Angle during a comparable treatment period (SNA + 2.23°), and a significant improvement of the WITS-appraisal (FM Group 4.81 mm, ME 4.14 mm) was found. These changes comply with the reported treatment effects on SNA with range of 1–3° achieved by maxillary protraction [8–10, 37]. The values we found are slightly higher than those of conventional RME and FM therapy. In a controlled clinical study, Westwood et al. found increases of 1.6° in SNA and 4.3 mm in the Wits appraisal [7]. A meta-analysis of conventional maxillary protraction reported a mean increase of SNA by 1.4° [24].

Many clinicians favour the use of RME to open the midface sutures to improve the skeletal effect. The RME/FM protocol demonstrates superior maxillary protraction when performed in the early mixed dentition [6, 18]. Consequently, the timing of treatment seems to be of paramount importance. Current evidence seems to be slightly in favour to combine RME and maxillary protraction during early Class III treatment, which gave reason to perform RME in all patients included in this study [24].



**Fig. 2** Hybrid-Hyrax- before and after maxillary expansion



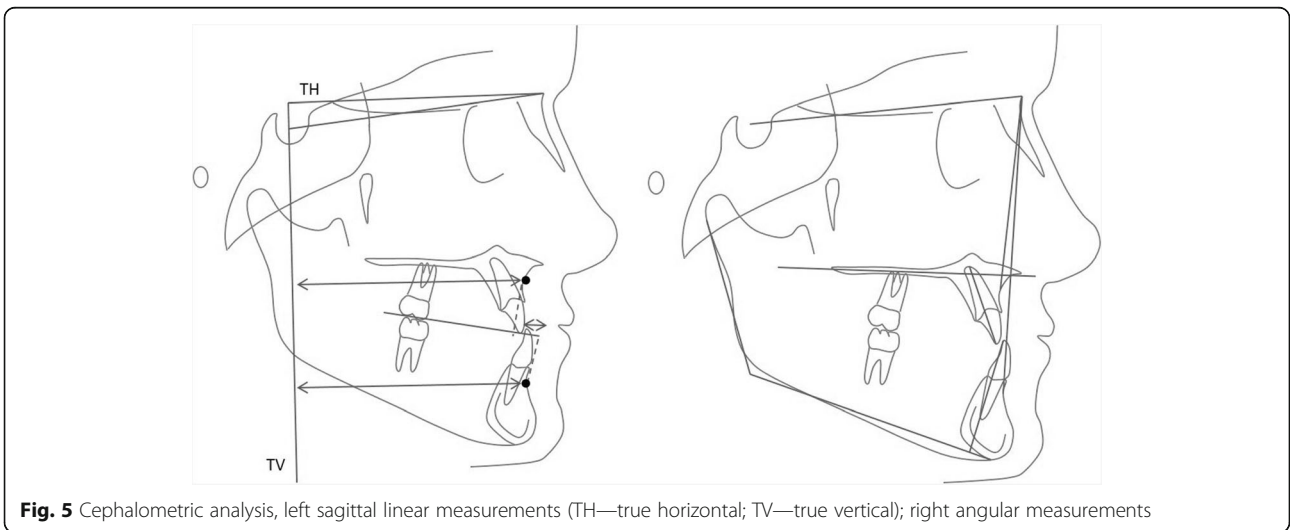
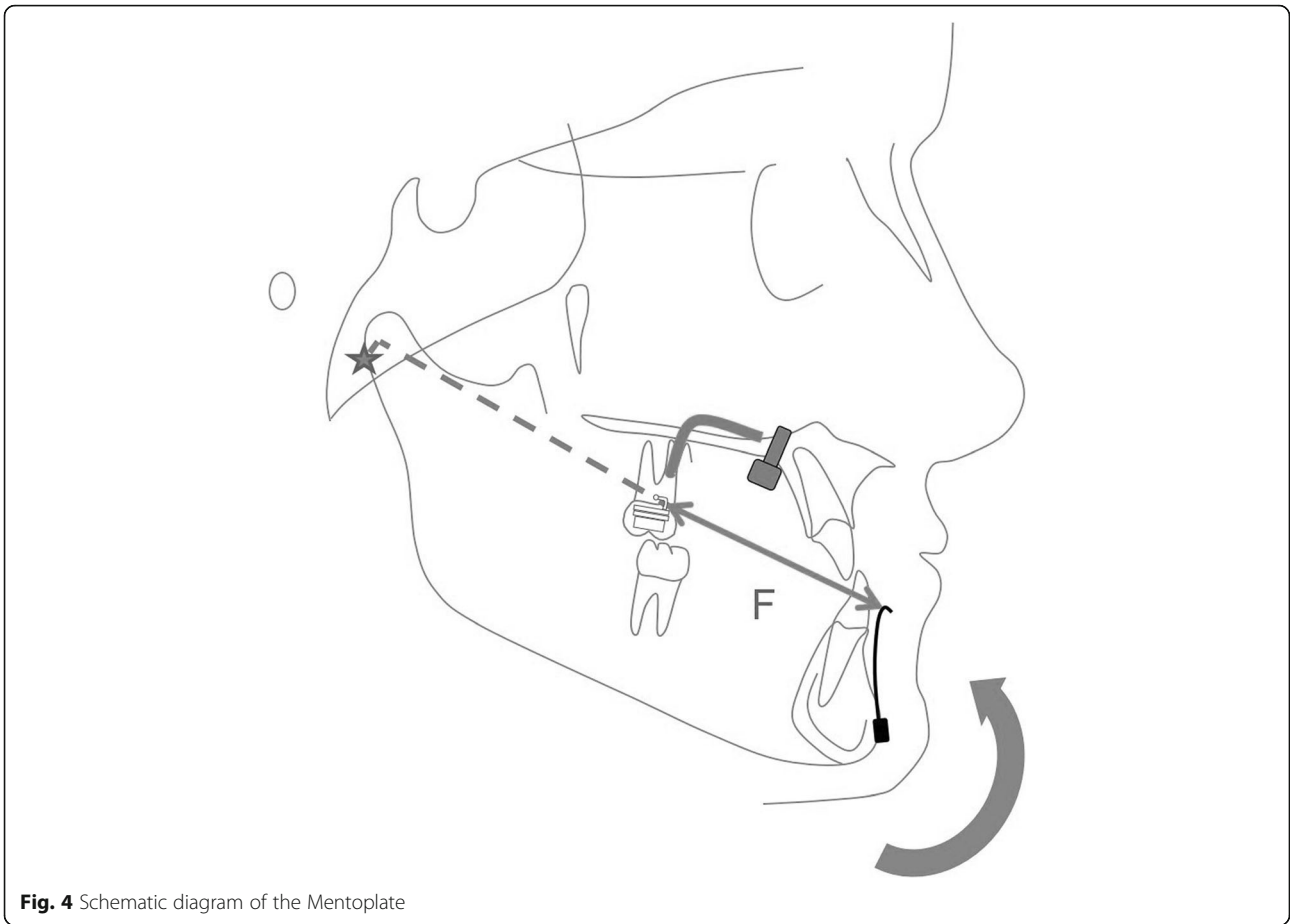
Mini-plate anchored maxillary protraction as described by de Clerck showed good skeletal effects in the late mixed or early permanent dentition [38, 39]. Since the Mentoplate is inserted in the subapical region of the lower incisors, awaiting the eruption of the lower canines is not necessary, allowing for an earlier onset of treatment [31, 40]. Currently, it is not very clear whether early and late onset of treatment using purely bone-borne protraction devices is more effective.

The skeletal effect in the maxilla seems to be improved, if the orthopaedic forces are applied directly to the maxillary bone with the help of skeletal anchorage instead of using tooth-borne appliances [39, 41, 42]; also, a reduction of dental side effects can be observed. The usual side effects occurring during protraction with tooth-borne appliances such as proclination of the incisors, space loss for the canines and mesial migration of the molars could not be observed in both study groups. Therefore, the majority of the overjet correction (FM group 3.51 mm, ME group 3.06 mm) was due to favourable skeletal changes rather than dentoalveolar compensation.

For protraction of the maxilla, heavy forces of 400 up to 1500 g are recommended with FM therapy, to

facilitate a sufficient orthopaedic effect [43]. For purely bone-anchored protraction protocols, lighter forces are recommended. De Clerck used an initial force of 100 g, which is gradually increased to 250 g, with a recommended full time wear of the Cl. III elastics. In this study, 200 g were used over the whole treatment time. Intraoral elastics can be worn full time without affecting the patient facial appearance, which might be a key to increase patient's compliance. Subjective wear time analysis revealed a FM wear time of 14 h per day [14, 18, 44, 45]. In a case study, an objective wear time measurement showed an average wear time of 9 h a day [46]. Apparently, the recommended heavy forces in conventional appliances stem from the limited wear times of these extraoral devices. In contrast, purely intraoral skeletally anchored devices can be worn over a longer period of time during a day, thus producing a comparable skeletal effect at lower force levels. As in all other studies, it would have been most desirable being able to objectively measure the exact wear times of the elastics for maxillary protraction.

As mentioned above, the skeletal effects found in the FM and ME groups on the maxilla were comparable. This was not true for the mandible where a





**Table 3** Cephalometric values; comparison of initial values before treatment

Variables	Facemask T0	Mentoplate T0	p values	CI 95%
SNA°	79.41 ± 2.86	79.23 ± 3.08	0.865	- 1.90 2.26
SNB°	80.51 ± 3.26	80.09 ± 3.05	0.703	- 1.79 2.63
ANB°	- 1.10 ± 1.98	- 0.86 ± 1.83	0.714	- 1.58 1.09
WITS mm	- 5.39 ± 1.47	- 5.83 ± 1.35	0.369	- 0.55 1.43
ATV mm	59.99 ± 2.99	59.42 ± 4.97	0.685	- 2.29 3.45
BTV mm	59.32 ± 4.78	58.24 ± 7.04	0.604	- 3.13 5.29
ABTV mm	0.67 ± 3.16	1.18 ± 2.88	0.629	- 2.62 1.61
ML-NL°	26.06 ± 5.44	27.87 ± 6.18	0.371	- 5.88 2.26
ML-NSL°	32.65 ± 6.27	34.95 ± 6.94	0.317	- 6.93 2.32
NSL-NL°	6.58 ± 2.93	7.08 ± 3.74	0.812(MWU)	- 2.85 1.85
AR-GO-ME°	126.92 ± 7.05	128.10 ± 4.99	0.643	- 6.23 3.95
MOK-A mm	26.37 ± 2.21	26.43 ± 1.93	0.929	- 1.51 1.39
U1-PP°	108.19 ± 7.85	110.36 ± 6.79	0.396	- 7.30 2.96
L1-ML°	86.87 ± 6.27	86.52 ± 6.93	0.892(MWU)	- 4.27 4.97

MWU Mann-Whitney U test

significant decrease of the SNB angle was found. Analysis of the vertical cephalometric measurements revealed a significant opening of the interbase angle (ML-NL) in the FM group which was mainly caused by a posterior rotation of the mandible. In other words, B point effectively moved down and backwards in the FM-group, which might be due to the chin-cap effect of the facemask [4]. Consequently, the skeletal effect on the mandible in the FM-group is more of a vertical nature, described by a posterior rotation of the mandible (Fig. 3). In contrast, the B-point remains stable in the ME-group (Fig. 4). These findings were consistent with those of Cevitanes and other authors, who reported a greater vertical control and less opening rotation of the mandible when applying forces to symphyseal plates [38, 39, 47]. The gonial angle decreased significantly in the ME-group, which might be due to changes in the direction of condylar and ramus growth [48].

The results represent short-term observation within the limitations of a retrospective study. Further observation of these patients would be desirable to be able to draw long-term conclusions of these treatment modalities.

**Table 4** Treatment time

	Treatment time in years
Facemask	0.79 ± 0.26
Mentoplate	0.87 ± 0.25
T test	0.362 n.s.

**Table 5** Skeletal and dental treatment effects in the facemask group

Variables	Facemask T0	Facemask T1	p values	CI 95%
SNA°	79.41 ± 2.86	81.66 ± 2.92	0.000*	1.60 2.90
SNB°	80.51 ± 3.26	79.02 ± 3.27	0.000*	- 2.06 - 0.91
ANB°	- 1.10 ± 1.98	2.65 ± 2.34	0.000*	3.00 4.49
WITS mm	- 5.39 ± 1.47	- 0.57 ± 1.51	0.000*	4.02 5.52
ATV mm	59.99 ± 2.99	62.42 ± 3.47	0.000*	1.71 3.13
BTV mm	59.32 ± 4.78	57.52 ± 5.05	0.002*	- 2.81 - 0.74
ABTV mm	0.67 ± 3.16	4.90 ± 3.60	0.000*	3.30 5.14
ML-NL°	26.06 ± 5.44	27.95 ± 6.12	0.000*	1.03 2.74
ML-NSL°	32.65 ± 6.27	33.79 ± 6.11	0.149	0.37 1.90
NSL-NL°	6.58 ± 2.93	5.84 ± 3.96	0.148 (W)	- 0.27 1.76
AR-GO-ME°	126.92 ± 7.05	127.33 ± 6.92	0.001*	0.19 0.61
MOK-A mm	26.37 ± 2.21	26.30 ± 2.19	0.246	- 0.05 0.19
U1-PP°	108.19 ± 7.85	107.04 ± 6.92	0.473	- 2.16 4.47
L1-ML°	86.87 ± 6.27	83.04 ± 4.26	0.028* (W)	- 6.99 - 0.67

W Wilcoxon

\*significant at p < 0.05

**Conclusions**

Both treatment options achieve comparable rates of maxillary protraction, without dentoalveolar side effects. The Mentoplate can be inserted before eruption of the mandibular canines allowing an early onset of class III treatment. The need to wear a facemask is eliminated. Hence, it can be alternative if patients refuse to wear a facemask. Skeletal anchorage with symphyseal plates in the mandible provides greater vertical control and might be the treatment of choice in high angle patients.

**Table 6** Skeletal and dental treatment effects in the Mentoplate group

Variables	Mentoplate T0	Mentoplate T1	p values	CI 95%
SNA°	79.23 ± 3.08	81.47 ± 3.15	0.000*	1.49 2.97
SNB°	80.09 ± 3.05	79.79 ± 3.20	0.070	- 0.42 0.97
ANB°	- 0.86 ± 1.83	1.68 ± 1.55	0.000*	2.20 3.20
WITS mm	- 5.83 ± 1.35	- 1.69 ± 1.32	0.000*	3.74 5.05
ATV mm	59.42 ± 4.97	62.09 ± 5.03	0.000*	1.90 3.44
BTV mm	58.24 ± 7.04	58.50 ± 7.24	0.973	- 0.91 0.88
ABTV mm	1.18 ± 2.88	3.59 ± 2.91	0.000*	2.16 3.17
ML-NL°	27.87 ± 6.18	27.97 ± 6.05	0.869	- 1.26 1.07
ML-NSL°	34.95 ± 6.94	34.40 ± 6.87	0.055	- 0.01 1.11
NSL-NL°	7.08 ± 3.74	6.44 ± 3.56	0.229	- 0.44 1.73
AR-GO-ME°	128.10 ± 4.99	125.14 ± 8.36	0.000*	- 3.96 - 1.94
MOK-A mm	26.43 ± 1.93	26.32 ± 1.86	0.054	0.00 0.22
U1-PP°	110.36 ± 6.79	110.78 ± 5.12	0.752	- 3.22 2.37
L1-ML°	86.52 ± 6.93	85.97 ± 6.22	0.556	- 1.41 2.52

\*significant at p < 0.05

**Table 7** Group differences between the facemask and Mentoplate group

Variables	Facemask ( $\Delta T0 - T1$ )	Mentoplate ( $\Delta T0 - T1$ )	<i>p</i> values	CI 95%	
SNA°	2.23 ± 1.30	2.23 ± 1.43	0.995	- 0.96	0.95
SNB°	- 1.51 ± 1,13	- 0.30 ± 0.98	0.002*	- 1.95	- 0.47
ANB°	3.75 ± 1.45	2.54 ± 0.99	0.008*	0.33	2.08
WITS mm	4.81 ± 1,38	4.14 ± 1.25	0.147	- 0.25	1.59
ATV mm	2.38 ± 1,42	2.67 ± 1.49	0.557	- 1.31	0.72
BTV mm	- 1.87 ± 2,08	0.26 ± 1.75	0.003*	- 3.47	- 0.78
ABTV mm	4.24 ± 1.78	2.41 ± 0.99	0.001*	0.82	2.84
ML-NL°	1.89 ± 1.65	0.12 ± 2.11	0.005*	0.61	3.27
ML-NSL°	1.17 ± 1.48	- 0.55 ± 1.09	0.001*	0.80	2.63
NSL-NL°	- 0.72 ± 1.99	- 0.49 ± 2.06	0.501 (MWU)	- 1.64	1.19
AR-GO-ME°	0.40 ± 0.41	- 2.96 ± 1.96	0.000*	2.36	4.35
MOK-A mm	- 0.07 ± 0.24	- 0.11 ± 0.22	0.624	- 0.12	0.20
U1-PP°	- 1.15 ± 6.45	0.57 ± 5.49	0.407	- 5.91	2.46
L1-ML°	- 3.84 ± 6.13	- 0.56 ± 3.83	0.081 (MWU)	- 6.85	0.29

MWU Mann-Whitney *U* test

\*significant at *p* < 0.05

#### Availability of data and materials

Please contact the author for data request.

#### Authors' contributions

JW took part in designing the study, wrote the main draft of the manuscript, and performed statistical analysis. MN took part in the study design and statistical analysis and critically revised the manuscript. NET critically revised the manuscript and aided in cephalometric data analysis. BW took part in designing the study and helped to draft the manuscript. DD participated in the design of the study, aided in the statistical analysis, and critically revised the manuscript. All authors read and approved the final manuscript.

#### Ethics approval and consent to participate

The study was approved by the local Ethical Committee.

Study ID: 6047R.

Registration-ID: 2017074350.

#### Consent for publication

Written informed consent was given for publication of the photos and individual person's data.

#### Competing interests

Benedict Wilmes is lecturing about the Benefit system, but holds no financial interest. The other authors declare that they have no competing interests.

#### Publisher's Note

Springer Nature remains neutral with regard to jurisdictional claims in published maps and institutional affiliations.

#### Author details

<sup>1</sup>Department of Orthodontics, Heinrich-Heine-University, Kasernenstr. 1, 40213 Düsseldorf, Germany. <sup>2</sup>Sydney, Australia. <sup>3</sup>Private Practice, Düsseldorf, Germany.

Received: 16 July 2018 Accepted: 28 August 2018

Published online: 22 October 2018

#### References

- Jacobson A, Evans WG, Preston CB, Sadowsky PL. Mandibular prognathism. *Am J Orthod.* 1974;66(2):140–71.
- Williams S, Andersen CE. The morphology of the potential class III skeletal pattern in the growing child. *Am J Orthod.* 1986;89(4):302–11.
- Williams MD, Sarver DM, Sadowsky PL, Bradley E. Combined rapid maxillary expansion and protraction facemask in the treatment of class III malocclusions in growing children: a prospective long-term study. *Semin Orthod.* 1997;3(4):265–74.
- Sugawara J, Asano T, Endo N, Mitani H. Long-term effects of chin-cap therapy on skeletal profile in mandibular prognathism. *Am J Orthod Dentofac Orthop.* 1990;98(2):127–33.
- Mitani H. Early application of chin-cap therapy to skeletal class III malocclusion. *Am J Orthod Dentofac Orthop.* 2002;121(6):584–5.
- Baccetti T, McGill JS, Franchi L, McNamara JA Jr, Tollaro I. Skeletal effects of early treatment of class III malocclusion with maxillary expansion and face-mask therapy. *Am J Orthod Dentofac Orthop.* 1998;113(3):333–43.
- Westwood PV, McNamara JA Jr, Baccetti T, Franchi L, Sarver DM. Long-term effects of class III treatment with rapid maxillary expansion and facemask therapy followed by fixed appliances. *Am J Orthod Dentofac Orthop.* 2003;123(3):306–20.
- Mandall N, DiBiase A, Littlewood S, et al. Is early class III protraction facemask treatment effective? A multicentre, randomized, controlled trial: 15-month follow-up. *J Orthod.* 2010;37(3):149–61.
- Mandall N, Cousley R, DiBiase A, et al. Is early class III protraction facemask treatment effective? A multicentre, randomized, controlled trial: 3-year follow-up. *J Orthod.* 2012;39(3):176–85.
- Vaughn GA, Mason B, Moon H-B, Turley PK. The effects of maxillary protraction therapy with or without rapid palatal expansion: a prospective, randomized clinical trial. *Am J Orthod Dentofac Orthop.* 2005;128(3):299–309.
- Nienkemper M, Wilmes B, Pauls A, Drescher D. Maxillary protraction using a hybrid hyrax-facemask combination. *Prog Orthod.* 2013;14(1):1.
- McNamara JA Jr. An orthopedic approach to the treatment of class III malocclusion in young patients. *J Clin Orthod : JCO.* 1987;21(9):598–608.
- Turley PK. Orthopedic correction of class III malocclusion with palatal expansion and custom protraction headgear. *J Clin Orthod : JCO.* 1988;22(5):314–25.
- Ngan PW, Hagg U, Yiu C, Wei SHY. Treatment response and long-term dentofacial adaptations to maxillary expansion and protraction. *Semin Orthod.* 1997;3(4):255–64.
- Saadia M, Torres E. Sagittal changes after maxillary protraction with expansion in class III patients in the primary, mixed, and late mixed dentitions: a longitudinal retrospective study. *Am J Orthod Dentofac Orthop.* 2000;117(6):669–80.
- Kapust AJ, Sinclair PM, Turley PK. Cephalometric effects of face mask/expansion therapy in class III children: a comparison of three age groups. *Am J Orthod Dentofac Orthop.* 1998;113(2):204–12.
- Cha K-S. Skeletal changes of maxillary protraction in patients exhibiting skeletal class III malocclusion: a comparison of three skeletal maturation groups. *Angle Orthod.* 2003;73(1):26–35.

18. Franchi L, Baccetti T, McNamara JA. Postpubertal assessment of treatment timing for maxillary expansion and protraction therapy followed by fixed appliances. *Am J Orthod Dentofac Orthop.* 2004;126(5):555–68.
19. De Clerck HJ, Cornelis MA, Cevidanes LH, Heymann GC, Tulloch CJ. Orthopedic traction of the maxilla with miniplates: a new perspective for treatment of midface deficiency. *J Oral Maxillofac Surg.* 2009;67(10):2123–9.
20. Wilmes B, Nienkemper M, Drescher D. Application and effectiveness of a new mini-implant and tooth-borne rapid palatal expansion device: the hybrid-hyrax. *World J Orthod.* 2010;2010(11):323–30.
21. Ludwig B, Glas B, Bowman SJ, Drescher D, Wilmes B. Miniscrew-supported class III treatment with the Hybrid RPE Advancer. *J Clin Orthod : JCO.* 2010; 44(9):533–9. quiz 561
22. Ngan P, Yiu C, Hu A, Hägg U, Wei SH, Gunel E. Cephalometric and occlusal changes following maxillary expansion and protraction. *Eur J Orthod.* 1998; 20(3):237–54.
23. Foersch M, Jacobs C, Wriedt S, Hechtner M, Wehrbein H. Effectiveness of maxillary protraction using facemask with or without maxillary expansion: a systematic review and meta-analysis. *Clin Oral Investig.* 2015;19(6):1181–92.
24. Jäger A, Braumann B, Kim C, Wahner S. Skeletal and dental effects of maxillary protraction in patients with angle class III malocclusion a meta-analysis. *J Orofac Orthop.* 2001;62(4):275–84.
25. Kim JH, Viana MA, Graber TM, Omerza FF, BeGole EA. The effectiveness of protraction face mask therapy: a meta-analysis. *Am J Orthod Dentofac Orthop.* 1999;115(6):675–85.
26. Delaire J. Manufacture of the “orthopedic mask”. *Rev Stomatol Chir Maxillofac.* 1971;72(5):579–82.
27. Hegmann M, Rütger A-K. The Grummons face mask as an early treatment modality within a class III therapy concept. *J Orofac Orthop.* 2003;64(6):450–6.
28. Hata S, Itoh T, Nakagawa M, et al. Biomechanical effects of maxillary protraction on the craniofacial complex. *Am J Orthod Dentofac Orthop.* 1987;91(4):305–11.
29. Chong YH, Ive JC, Artun J. Changes following the use of protraction headgear for early correction of class III malocclusion. *Angle Orthod.* 1996; 66(5):351–62.
30. Baik HS. Clinical results of the maxillary protraction in Korean children. *Am J Orthod Dentofac Orthop.* 1995;108(6):583–92.
31. Wilmes B, Nienkemper M, Ludwig B, Kau CH, Drescher D. Early class III treatment with a hybrid hyrax-mentoplate combination. *J Clin Orthod: JCO.* 2011;45:15–21. quiz 39
32. Masucci C, Franchi L, Giuntini V, Defraia E. Short-term effects of a modified alt-RAMEC protocol for early treatment of class III malocclusion: a controlled study. *Orthod Craniofac Res.* 2014;17(4):259–69.
33. Cha B-K, Choi D-S, Ngan P, Jost-Brinkmann P-G, Kim S-M, I-s J. Maxillary protraction with miniplates providing skeletal anchorage in a growing class III patient. *Am J Orthod Dentofac Orthop.* 2011;139(1):99–112.
34. Ge YS, Liu J, Chen L, Han JL, Guo X. Dentofacial effects of two facemask therapies for maxillary protraction: Miniscrew implants versus rapid maxillary expanders. *Angle Orthod.* 2012;82(6):1083–91.
35. Şar Ç, Şahinoğlu Z, Özçirpici AA, Uçkan S. Dentofacial effects of skeletal anchored treatment modalities for the correction of maxillary retrognathia. *Am J Orthod Dentofac Orthop.* 2014;145(1):41–54.
36. Nienkemper M, Wilmes B, Franchi L, Drescher D. Effectiveness of maxillary protraction using a hybrid hyrax-facemask combination: a controlled clinical study. *Angle Orthod.* 2015;85(5):764–70.
37. Showkatbakhsh R, Toumarijan L, Jamilian A, Sheibaninia A, Mirkarimi M, Taban T. The effects of face mask and tongue plate on maxillary deficiency in growing patients: a randomized clinical trial. *J Orthod.* 2013;40(2):130–6.
38. De Clerck H, Cevidanes L, Baccetti T. Dentofacial effects of bone-anchored maxillary protraction: a controlled study of consecutively treated class III patients. *Am J Orthod Dentofac Orthop.* 2010;138(5):577–81.
39. Cevidanes L, Baccetti T, Franchi L, McNamara JA, De Clerck H. Comparison of two protocols for maxillary protraction: bone anchors versus face mask with rapid maxillary expansion. *Angle Orthod.* 2010;80(5):799–806.
40. Katyal V, Wilmes B, Nienkemper M, Darendeliler M, Sampson W, Drescher D. The efficacy of hybrid hyrax-Mentoplate combination in early class III treatment: a novel approach and pilot study. *Aust Orthod J.* 2016;32(1):88.
41. Lee NK, Yang IH, Baek SH. The short-term treatment effects of face mask therapy in class III patients based on the anchorage device: miniplates vs rapid maxillary expansion. *Angle Orthod.* 2012;82(5):846–52.
42. Sar C, Arman-Ozçirpici A, Uçkan S, Yazici AC. Comparative evaluation of maxillary protraction with or without skeletal anchorage. *Am J Orthod Dentofac Orthop.* 2011;139(5):636–49.
43. Kim J, Viana M, Graber T, Omerza F, BeGole E. The effectiveness of protraction facemask therapy: a meta-analysis. *Am J Orthod Dentofac Orthop.* 1999;115(6):675.
44. Baccetti T, Franchi L, McNamara JA. Treatment and posttreatment craniofacial changes after rapid maxillary expansion and facemask therapy. *Am J Orthod Dentofac Orthop.* 2000;118(4):404–13.
45. Shanker S, Ngan P, Wade D, et al. Cephalometric A point changes during and after maxillary protraction and expansion. *Am J Orthod Dentofac Orthop.* 1996;110(4):423–30.
46. Stocker B, Willmann JH, Wilmes B, Vasudavan S, Drescher D. Wear-time recording during early class III facemask treatment using TheraMon chip technology. *Am J Orthod Dentofac Orthop.* 2016;150(3):533–40.
47. Elnagar MH, Elshourbagy E, Ghobashy S, Khedr M, Evans CA. Comparative evaluation of 2 skeletally anchored maxillary protraction protocols. *Am J Orthod Dentofac Orthop.* 2016;150(5):751–62.
48. De Clerck H, Nguyen T, de Paula LK, Cevidanes L. Three-dimensional assessment of mandibular and glenoid fossa changes after bone-anchored class III intermaxillary traction. *Am J Orthod Dentofac Orthop.* 2012;142(1):25–31.

**Submit your manuscript to a SpringerOpen® journal and benefit from:**

- Convenient online submission
- Rigorous peer review
- Open access: articles freely available online
- High visibility within the field
- Retaining the copyright to your article

---

Submit your next manuscript at ► [springeropen.com](http://springeropen.com)