

Correction of Upper-Arch Asymmetries Using the Mesial-Distalslider

BENEDICT WILMES, DMD, MSD, PHD
RAVINDRA NANDA, BDS, MDS, PHD
MANUEL NIENKEMPER, DDS, MSC
BJÖRN LUDWIG, DMD, MSD
DIETER DRESCHER, DMD, PHD

Correcting maxillary dental asymmetries without the need for extractions or space opening for dental implants represents a major challenge for the orthodontist, especially when using conventional anchorage methods. Although buccally inserted mini-implants provide more reliable anchorage, the potential correction is limited to about 1mm because the buccal mini-implant is placed in the path of the moving teeth. The palate is more suitable for skeletal anchorage, since any teeth can be moved without interference. In addition, the anterior palate offers good bone quality and a thin attached mucosa, with no risk of root injury, ensuring a high rate of success.^{1,2}

The Mesial-Distalslider³ (Fig. 1) is a mini-implant-borne appliance that combines the mechanics of the Beneslider^{4,5} and the Mesialslider,⁶ thus allowing simultaneous distalization and mesialization in the same arch. A common indication is the upper-arch midline deviation resulting from a unilateral missing tooth.

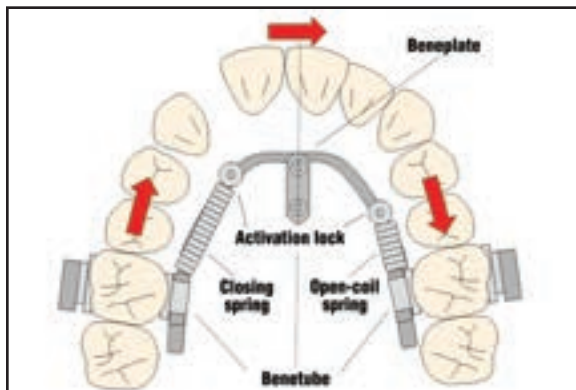


Fig. 1 Mesial-Distalslider for simultaneous unilateral distalization and contralateral mesialization.

Clinical Procedure

We use the Benefit* mini-implant system,⁷ in which the selected abutment is fixed to the mini-implant with an inner microscrew. To improve stability and prevent unwanted rotation, two Benefit mini-implants are coupled using a Beneplate³ with an integrated .045" stainless steel wire.

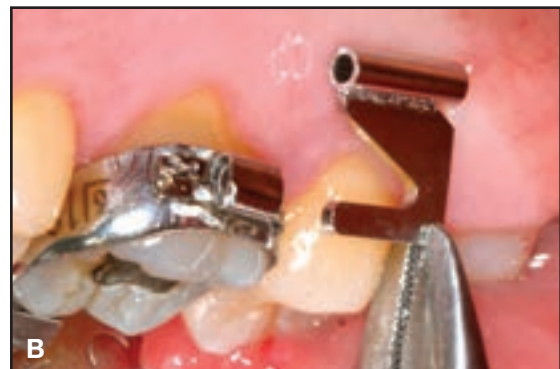
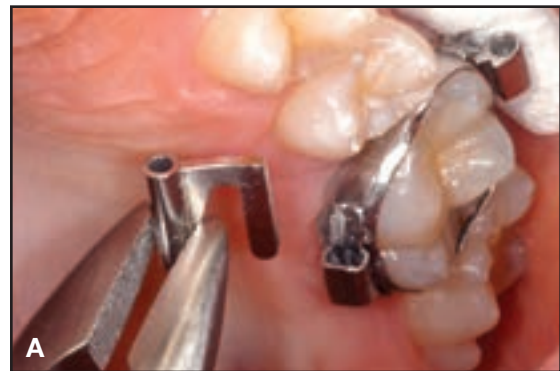
Fig. 2 Benetube inserted from mesial on distalization side (A) and from distal on mesialization side (B). Tube body is bent as needed to conform to palate and avoid soft-tissue irritation.



Dr. Wilmes



Dr. Nanda



Dr. Nienkemper



Dr. Ludwig



Dr. Drescher

Dr. Wilmes is a Professor, Dr. Nienkemper is an Instructor, and Dr. Drescher is Professor and Head, Department of Orthodontics, University of Düsseldorf, Moorenstrasse 5, 40225 Düsseldorf, Germany. Dr. Wilmes is also a Visiting Professor, Department of Orthodontics, University of Alabama at Birmingham School of Dentistry, and the developer of the Benefit system. Dr. Nanda is an Associate Editor of the *Journal of Clinical Orthodontics* and UConn Orthodontic Alumni Endowed Chair, Division of Orthodontics, and Professor and Head, Department of Craniofacial Sciences, University of Connecticut School of Dental Medicine, Farmington, CT. Dr. Ludwig is a Contributing Editor of the *Journal of Clinical Orthodontics*; an Instructor, Department of Orthodontics, University of Homburg, Saar, Germany; and in the private practice of orthodontics in Traben-Trarbach, Germany. E-mail Dr. Wilmes at: wilmes@med.uni-duesseldorf.de.

After administration of topical or local anesthetic, a 1.4mm drill is used to make pilot holes to a depth of 3mm near the midpalatal suture, posterior to the third rugae. The distance between the two mini-implants should be at least 5mm and no more than 14mm. Drilling can be done manually, using a 1:1 contra-angle equipped with a supplied manual driver, which avoids the need for cooling. The self-drilling Benefit mini-implants can usually be inserted without predrilling. In adult patients with high bone density in the anterior palate, however, the predrilling prevents excessive torquing moments. Predrilling is not necessary in patients younger than 12 due to the low level of bone mineralization.

Two Benefit mini-implants (2mm × 11mm anterior and 2mm × 9mm posterior) are inserted, again using the contra-angle screwdriver. Mini-screws with a diameter of 2mm or 2.3mm will provide superior stability compared to narrower screws.^{8,9} At the same appointment, bands with lingual sheaths are cemented to the upper molars. Benetubes are inserted from the mesial on the distalization side (Fig. 2A) and from the distal on the mesialization side (Fig. 2B). In most patients, the Benetubes should be bent away from the palate to avoid soft-tissue irritation; the Beneplate body can also be bent as needed. The Beneplate is affixed to the mini-implants with two microscrews.

The Mesial-Distalslider can be installed with no impressions or laboratory work, but can also be adapted on a plaster cast to save chairtime. The mesialization force is delivered by a nickel tita-

um closing spring (200g), secured by an activation lock pushed mesially (Fig. 3A), and the distalization force by a nickel titanium open-coil spring (240g in children, 500g after eruption of the second molars) with the activation lock pushed distally (Fig. 3B). Follow-up appointments are scheduled every four to six weeks. If friction appears to be too high on the mesialization side after a few months, elastic chains can be added.

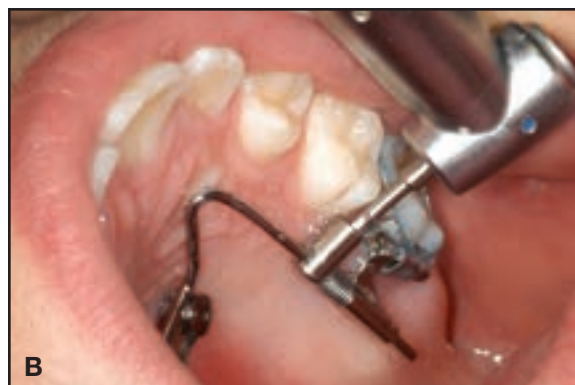
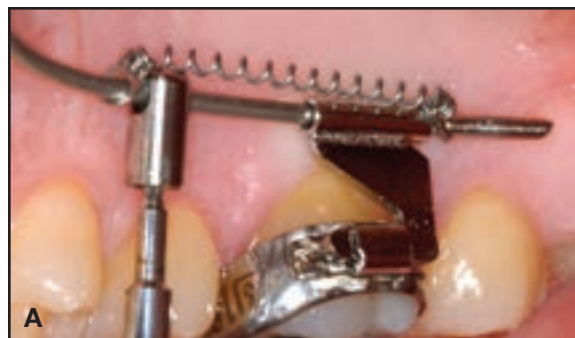
Fig. 3 Activation of Mesial-Distalslider by pushing activation lock mesially on mesialization side (A) and distally on distalization side (B).

*PSM Medical Solutions, Tuttlingen, Germany; www.psm.ms. Distributed in the U.S. by Mondeal North America, Inc., Indio, CA; www.mondeal-ortho.com.

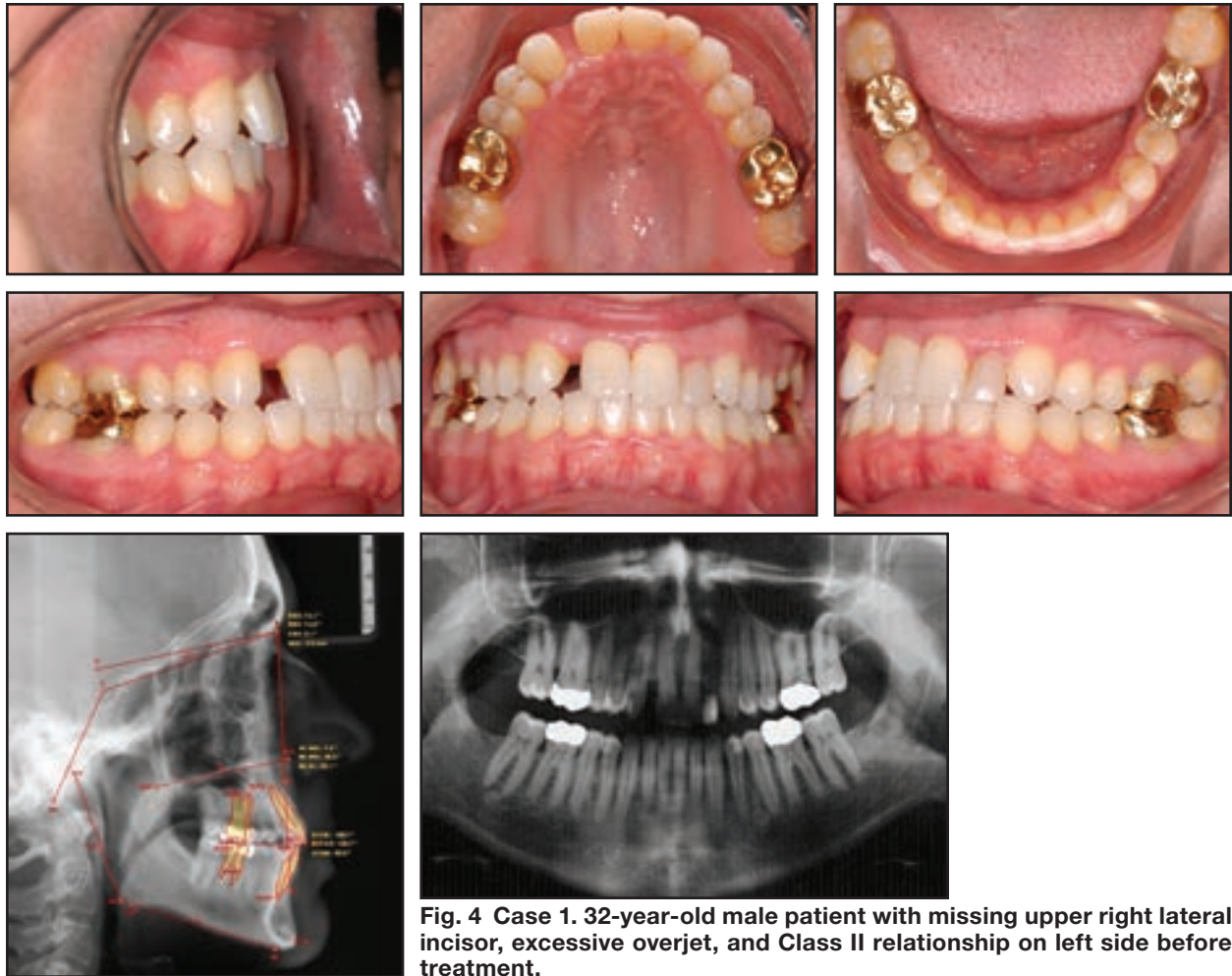


Fig. 4 Case 1. 32-year-old male patient with missing upper right lateral incisor, excessive overjet, and Class II relationship on left side before treatment.

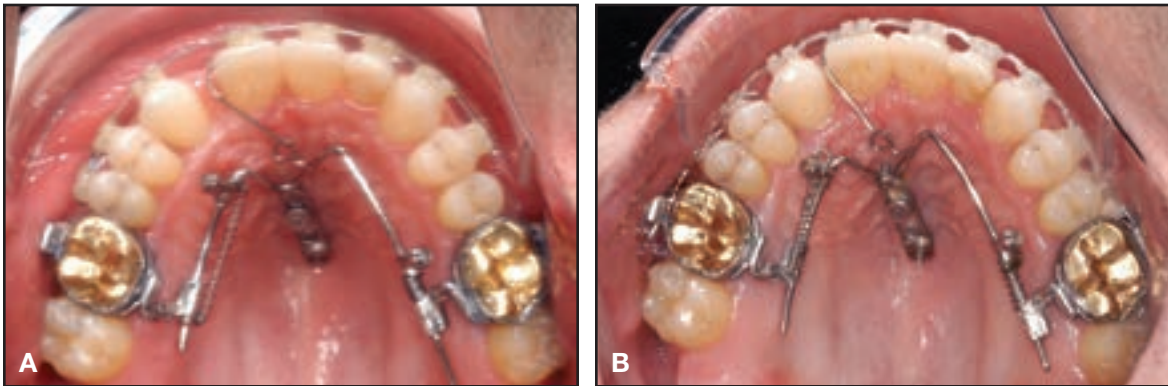


Fig. 5 A. Case 1. Mesial-Distalslider placed for mesialization of upper right quadrant and distalization of upper left quadrant. B. Partial closure of upper right lateral-incisor space after five months of treatment.

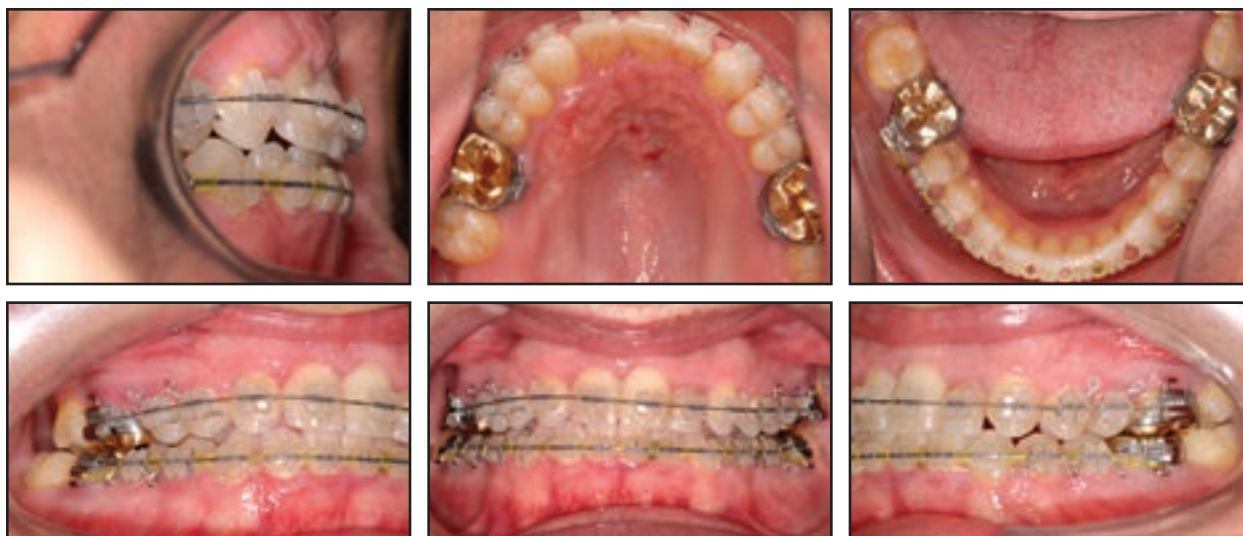

Fig. 6 Case 1. Sagittal movements completed and Mesial-Distalslider removed after seven months of treatment.

The premolars and canines will begin to migrate distally on the distalization side, resulting in the appearance of small spaces, while the premolars are pushed mesially on the opposite side. After completion of these sagittal tooth movements, which require a high degree of anchorage, the case can be finished with labial or lingual fixed appliances or, when feasible, with aligners. In some patients, the Mesial-Distalslider can be used at the same time as bonded brackets. The following cases demonstrate both methods.

Case 1

A 32-year-old male presented with a missing upper right lateral incisor, excessive overjet, and a Class II relationship (one-third of the premolar) on the left side (Fig. 4). He had previously undergone treatment with aligners to open space for a dental implant, but the right central incisor and canine had tipped into the lateral-incisor site, leaving even less space for an implant.

We recommended mesialization and canine substitution on the right side and distalization to correct the Class II malocclusion on the left, using the Mesial-Distalslider and labial brackets. An additional lever arm made of .020" stainless steel

was welded to the anterior section of the Mesial-Distalslider to apply a buccal mesialization force to the central incisor (Fig. 5A). In our experience, this simultaneous application of buccal and lingual force increases the speed of mesial movement.

After five months of treatment, the lateral-incisor space was much smaller, and the right posterior dentition had moved slightly distally (Fig. 5B). Two months later, the sagittal corrections had been completed, and the Mesial-Distalslider was removed to allow molar movement during the finishing stage (Fig. 6). Another two months later, treatment was completed. Figure 7 shows the patient two years after debonding.

Case 2

A 15-year-old male transfer patient was referred to our clinic with a Class III malocclusion (Wits appraisal = -3.4mm), a crossbite on the left side, and a mild centric occlusion-centric relation discrepancy. The upper right canine was absent, resulting in a midline deviation to the right (Fig. 8). The lower left first premolar had been removed previously.

Our treatment plan was to mesialize the upper right quadrant for closure of the canine

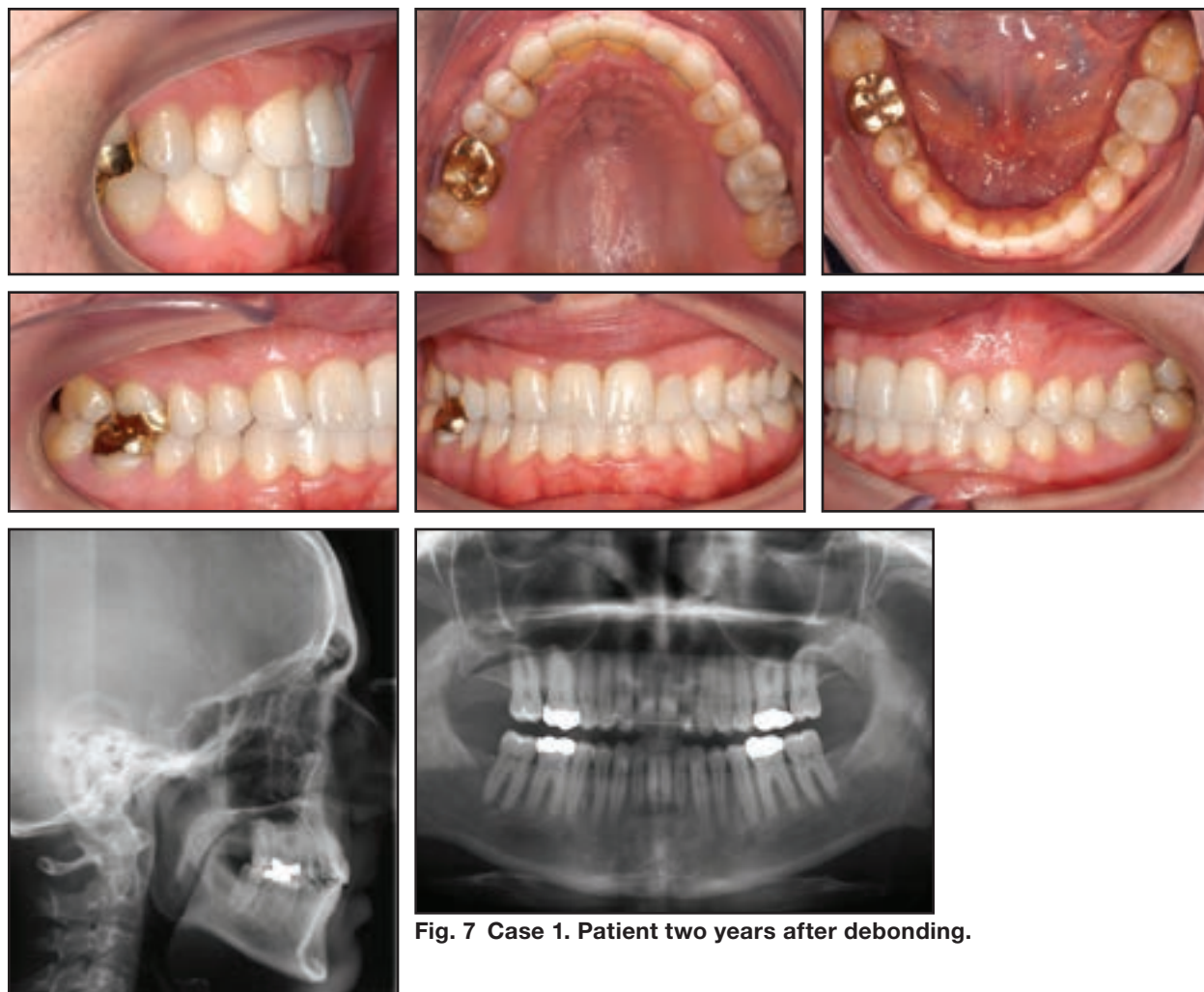


Fig. 7 Case 1. Patient two years after debonding.

space and to distalize the upper left quadrant for midline correction, using the Mesial-Distalslider (Fig. 9A). In the lower arch, the remaining first premolar would also be extracted to compensate for the skeletal Class III.

After seven months of treatment with the Mesial-Distalslider, the upper right canine space was closed, and small spaces had appeared in the upper left quadrant. The force applied to the molar also pushed the premolars mesially, resulting in minor tipping (Fig. 9B) that was corrected in the subsequent leveling phase (Fig. 9C). After reciprocal space closure in the lower arch and finishing,

the brackets were removed (Fig. 10). Total treatment time was four years.

Discussion

The insertion moments of mini-implants in the midpalatal region have been measured at 8-25Ncm, which can be regarded as adequate for primary stability.³ These mini-implants can be inserted close to the suture,^{2,10} where sufficient bone volume is available as far as about 3mm to either side.¹¹

The Mesial-Distalslider can be used either

with (Case 1) or without (Case 2) simultaneously bonded brackets. Although the reduced friction can make it advantageous to begin treatment without fixed appliances, the premolars and canines on the mesialization side may become mesially tipped and thus require later correction,

as in Case 2. To prevent this problem, in a procedure described by Dr. Thomas Banach, Benetubes can be bonded directly to the lingual surfaces of one or more teeth for extra anterior guidance (Case 3, Fig. 11).

Unlike intermaxillary elastics or interarch

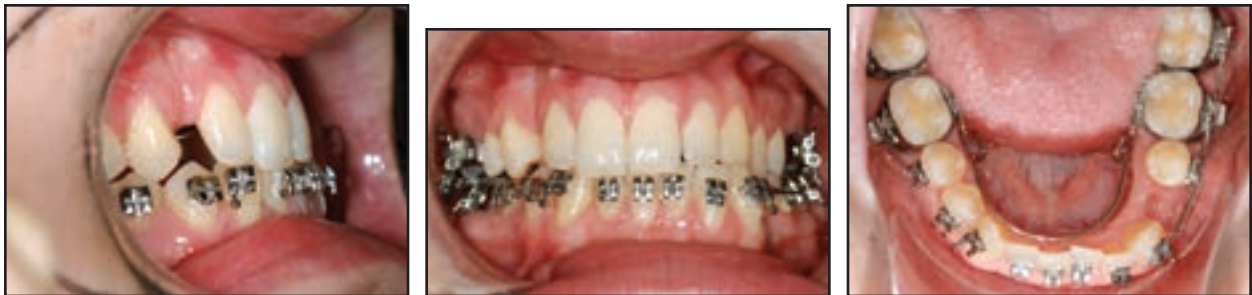


Fig. 8 Case 2. 15-year-old male transfer patient with left crossbite and missing upper right canine, resulting in midline deviation to right.

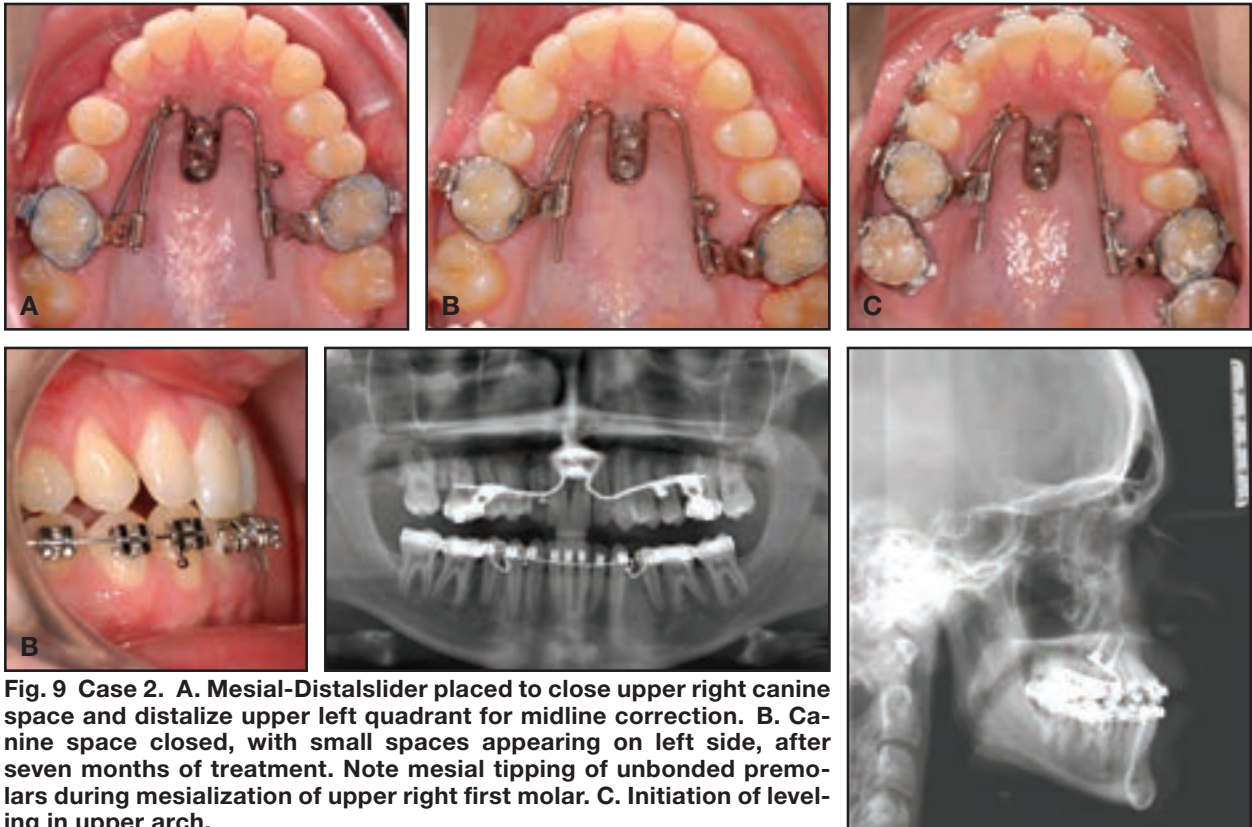


Fig. 9 Case 2. A. Mesial-Distalslider placed to close upper right canine space and distalize upper left quadrant for midline correction. B. Canine space closed, with small spaces appearing on left side, after seven months of treatment. Note mesial tipping of unbonded premolars during mesialization of upper right first molar. C. Initiation of leveling in upper arch.

Correction of Upper-Arch Asymmetries Using the Mesial-Distalslider

devices such as the Herbst** appliance or Jasper Jumper,** the Mesial-Distalslider can correct dental asymmetry in the upper arch without producing any movements of the lower teeth that may cause a patient to finish with a discrepancy between the dental and facial midlines, even if the occlusion seems perfect. It also avoids the need for unilateral Class II or contralateral Class III elas-

tics, which require patient compliance and can cause TMJ discomfort.

Conclusion

The Mesial-Distalslider has proven reliable in delivering unilateral mesialization and contralateral distalization of the upper dentition for correction of dentoalveolar asymmetry or midline deviation. In appropriate cases, it thus reduces the need for compensatory extractions on the distalization side and for dental implants on the mesialization side.

**Registered trademark of Dentaaurum, Inc., Newtown, PA; www.dentaaurum.com.

***Trademark of American Orthodontics, Sheboygan, WI; www.americanortho.com.

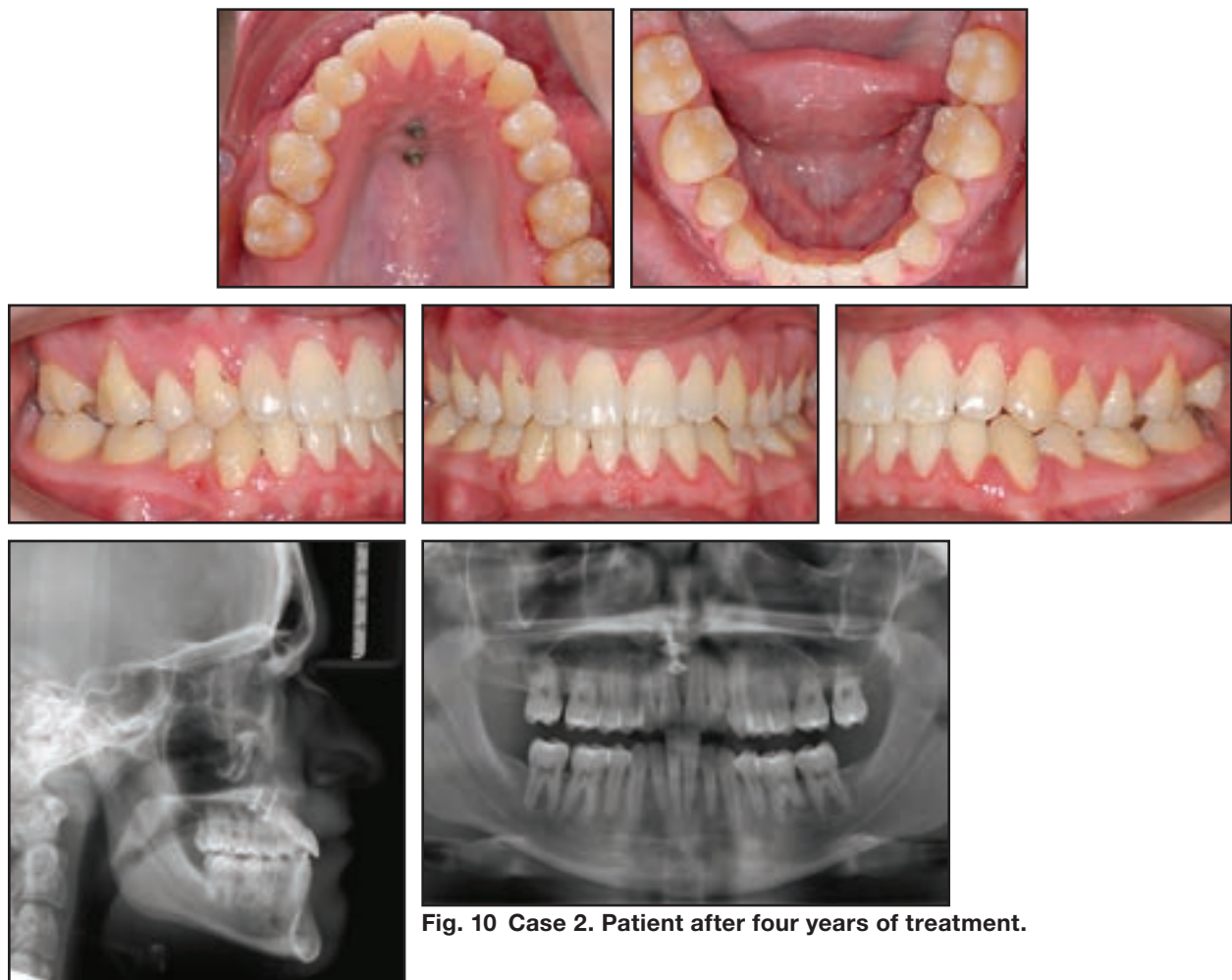


Fig. 10 Case 2. Patient after four years of treatment.

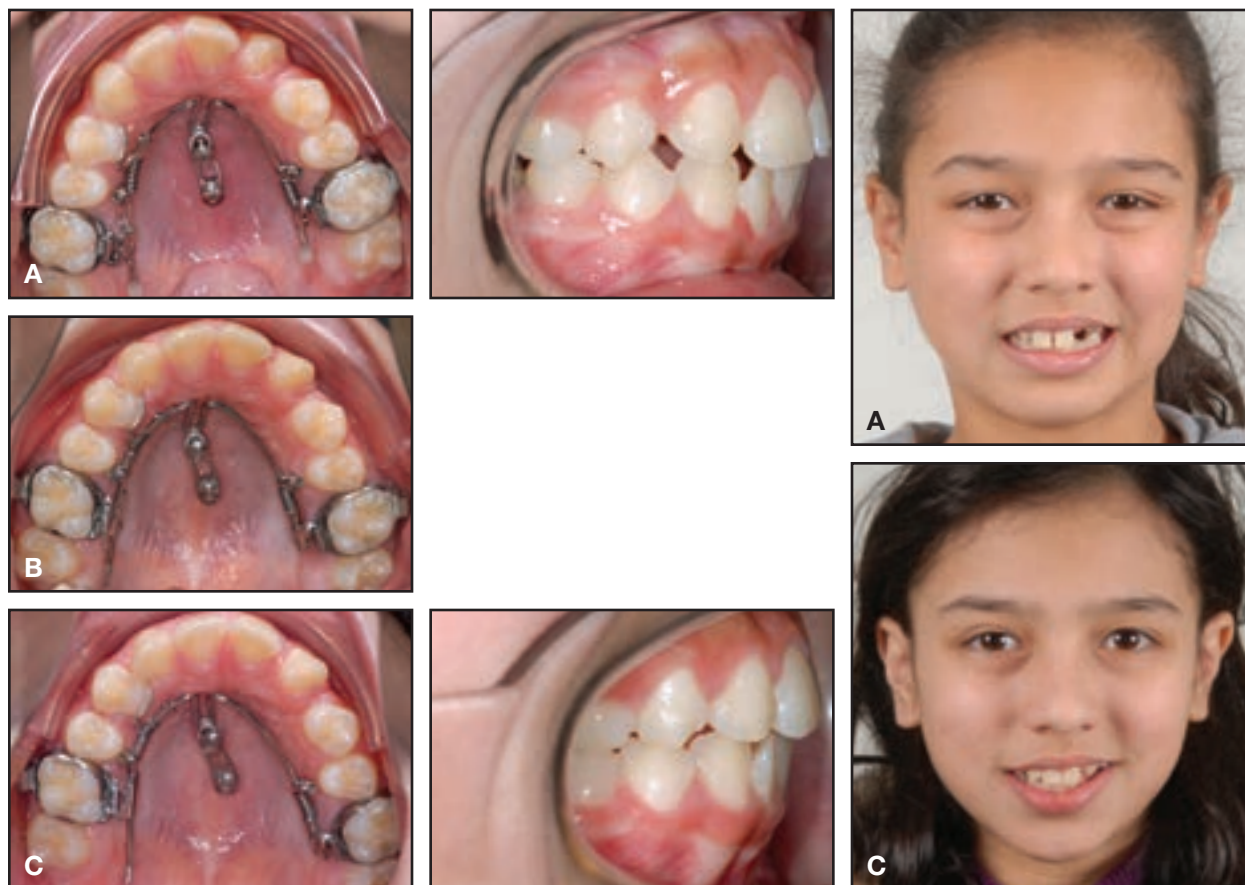

Fig. 11 Case 3. A. Mesial-Distalslider used for treatment of 11-year-old female patient with congenitally missing upper lateral incisors and severe midline deviation to right. Note Benetube bonded to upper right first premolar for guidance of mesialized teeth. B. After five months of treatment. C. After seven months of treatment with Mesial-Distalslider applying forces only to upper first molars and upper right first premolar. Additional Benetube and effects of interdental fibers on distalization side allowed midline correction and bodily mesialization of right premolars without brackets.

REFERENCES

1. Lim, H.J.; Choi, Y.J.; Evans, C.A.; and Hwang, H.S.: Predictors of initial stability of orthodontic miniscrew implants, *Eur. J. Orthod.* 33:528-532, 2011.
2. Ludwig, B.; Glasl, B.; Bowman, S.J.; Wilmes, B.; Kinzinger, G.S.; and Lisson, J.A.: Anatomical guidelines for miniscrew insertion: Palatal sites, *J. Clin. Orthod.* 45:433-441, 2011.
3. Wilmes, B.; Drescher, D.; and Nienkemper, M.: A miniplate system for improved stability of skeletal anchorage, *J. Clin. Orthod.* 43:494-501, 2009.
4. Wilmes, B.; Nienkemper, M.; Ludwig, B.; Kau, C.H.; Pauls, A.; and Drescher, D.: Esthetic Class II treatment with the Beneslider and aligners, *J. Clin. Orthod.* 46:390-398, 2012.
5. Wilmes, B. and Drescher, D.: Application and effectiveness of the Beneslider: A device to move molars distally, *World J. Orthod.* 11:331-340, 2010.
6. Wilmes, B.; Nienkemper, M.; Nanda, R.; Lübberink, G.; and Drescher, D.: Palatally anchored maxillary molar mesialization using the Mesialslider, *J. Clin. Orthod.* 47:172-179, 2013.
7. Wilmes, B. and Drescher, D.: A miniscrew system with interchangeable abutments, *J. Clin. Orthod.* 42:574-580, 2008.
8. Wilmes, B.; Rademacher, C.; Olthoff, G.; and Drescher, D.: Parameters affecting primary stability of orthodontic mini-implants, *J. Orofac. Orthop.* 67:162-174, 2006.
9. Wilmes, B. and Drescher, D.: Impact of insertion depth and predrilling diameter on primary stability of orthodontic mini-implants, *Angle Orthod.* 79:609-614, 2009.
10. Kang, S.; Lee, S.J.; Ahn, S.J.; Heo, M.S.; and Kim, T.W.: Bone thickness of the palate for orthodontic mini-implant anchorage in adults, *Am. J. Orthod.* 131:S74-81, 2007.
11. Bernhart, T.; Freudenthaler, J.; Dörtbudak, O.; Bantleon, H.P.; and Watzek, G.: Short epithetic implants for orthodontic anchorage in the paramedian region of the palate: A clinical study, *Clin. Oral Impl. Res.* 12:624-631, 2001.