

Julia Haubrich, Julia Funke, Werner Schupp, Benedict Wilmes

Approaching complex orthodontic treatment cases using aligners in combination with skeletal anchorage



Julia Haubrich

KEY WORDS aligner orthodontics, anterior open bite, incisor extraction, Invisalign, Mesialslider, mini-implants, molar extraction, reverse articulation, skeletal anchorage, space closure

Within the framework of treatment planning for missing teeth, the fundamental question is how to offer long-term solutions. One option is to close the space with a prosthetic restoration such as a dental implant or fixed or removable partial denture. Another option is orthodontic space closure, which makes it possible to avoid further tooth preparation, thus reducing the tooth substance required, or even generate new bone through the tooth movement into the gap due to the interdental fibres. Compared to space opening, however, space closure has far greater requirements in terms of anchorage. Preservation of the sagittal vertical overlap and adjustment of the dental midlines often necessitates use of skeletal anchorage, especially in cases of dental asymmetry. The present case report demonstrates a complex treatment using aligner orthodontics in combination with the Mesialslider (TADMAN, Gunningen, Germany) after loss of a maxillary molar, including a mandibular incisor extraction approach, closure of anterior open bite and solving of unilateral reverse articulation.

Julia Haubrich, Dr med dent
Private practice, Cologne, Germany

Julia Funke, Dr med dent
Private practice, Cologne, Germany

Werner Schupp, Dr med dent
Private practice, Cologne, Germany

Benedict Wilmes, Prof Dr med dent
University Hospital Dusseldorf, Dusseldorf, Germany

Correspondence to: Dr Julia Haubrich, Hauptstrasse 50, 50996 Cologne, Germany. Email: haubrich@schupp-ortho.de

Introduction

There are several options available for closing spaces after extractions or in cases of missing teeth, such as restorations or implants or orthodontic treatment for space closure¹⁻¹³. In orthodontic treatment, aligner therapy has become increasingly popular in the last decades. Aligners are virtually invisible, using light forces and offering predictable results with fewer potential side effects than other forms of orthodontic therapy¹⁴⁻¹⁸. They are therefore no longer an unusual alternative to fixed appliance treatment, but are rather becoming the 'new normal' in orthodontics. Twenty years ago, it was thought that only simple cases with mild to moderate crowding and spacing could be treated with aligners, but it is now evident that aligners, in combination with attachments and auxiliaries, can resolve almost any orthodontic issue¹⁹⁻³⁵. Precise diagnosis and treatment planning are required to achieve favourable results for both the patient and practitioner, and particularly complex cases need thorough planning to be successful.

Mini-implant-assisted tooth movement has broadened the limits and boundaries of conventional orthodontic treatment and can sometimes even lead to the avoidance of orthognathic surgery in borderline cases. Controlled orthodontic space closure with no anchorage loss is an invasive and time-consuming but effective method that may avoid the necessity for further dental implants or prosthodontic restorations. The present case

report describes the challenges posed by a complex combined treatment with skeletal anchorage and aligner orthodontics.

Mini-implants for anchorage

Orthodontic mini-implants are now the most popular of the skeletal anchorage systems due to their versatility, low surgical invasiveness and relatively low cost³⁶⁻⁴¹. In the first few years after their introduction, placement of mini-implants was initially only interradicular³⁶; however, the alveolar process often proves to be only partially suitable for mini-implant placement. Disadvantages include the higher rate of implant loss in the alveolar process and the risk of root damage⁴². The anterior palate, on the other hand, has proven to be a highly reliable insertion region⁴³. The Mesialslider (TADMAN, Gunningen, Germany) is now used as a standard device for mesialisation in the maxilla^{44,45}.

In addition to anchorage, the second advantage of mini-implants is that they offer physical guidance of the teeth, which appears to be essential in the context of aligner therapy. Due to its prefabricated elements, the Mesialslider can be manufactured directly intraorally, or after a scan or impression has been taken in the laboratory. By using virtual planning and CAD/CAM manufactured insertion guides, the slider can be fabricated prior to mini-implant insertion such that mini-implants and Mesialsliders can be placed in just one session^{46,47}.

CAD/CAM Mesialslider

Until now, the Mesialslider has usually been manufactured through a classical laboratory process with band fitting, impression taking, fabrication of a plaster model and subsequent manufacture of the appliance using prefabricated components⁴⁸. Due to the further development of intraoral scanners and their availability as well as advances in additive manufacturing, digital CAD/CAM workflows have been described for the fabrication of expanders and retainers, for example^{49,50}.

BENEFIT direct coupling

In the conventional BENEFIT system (TADMAN), the mini-implants are inserted first, then an impression or scan is taken to fabricate the appliance. In recent years, insertion guides have also been used increasingly frequently; in this way, the appliance can be fabricated in advance. This means

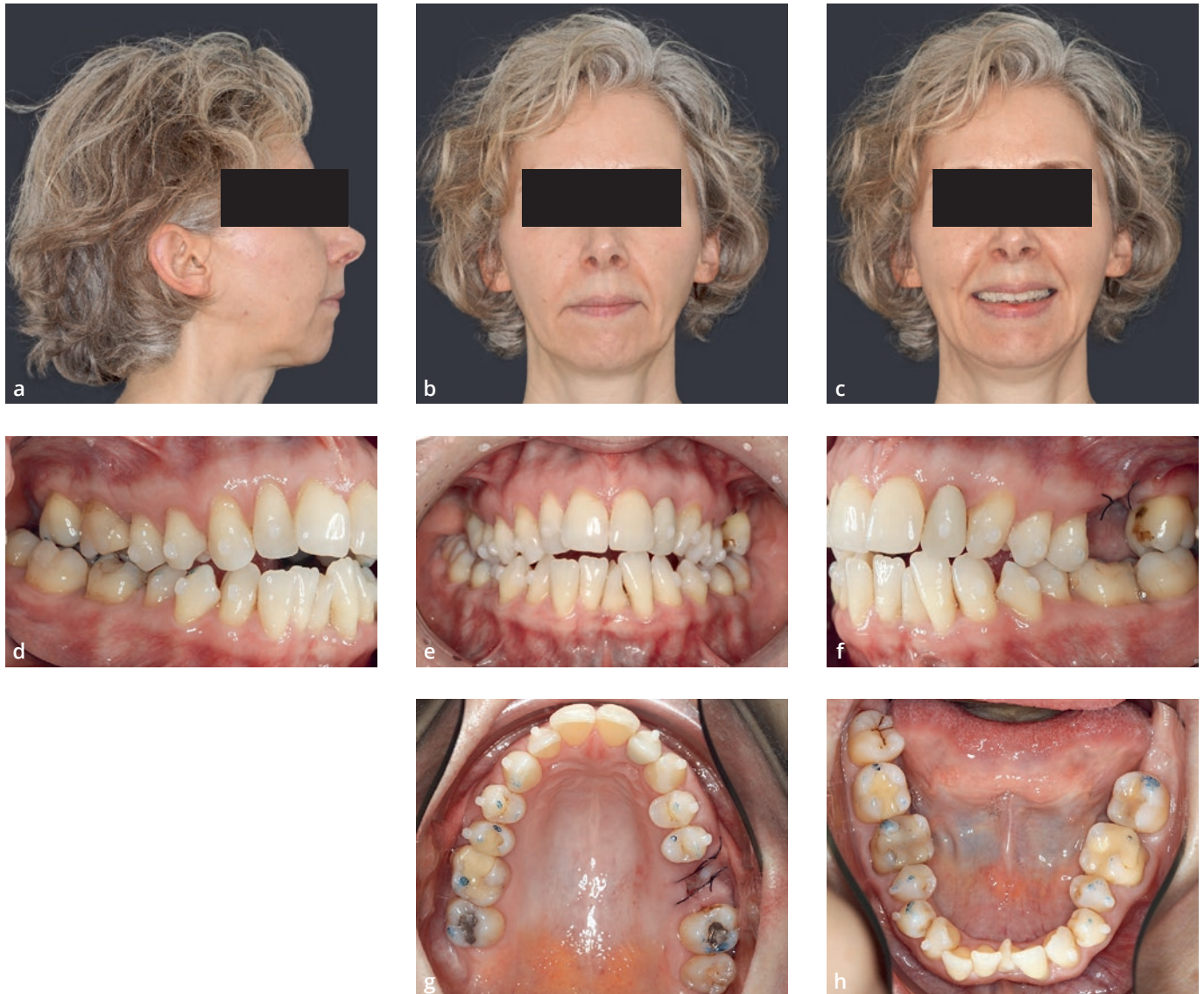the insertion site can be planned optimally and the mini-implants and appliance can be inserted in just one appointment^{47,51}. In both the conventional procedure with an impression or scan and the use of insertion guides, the mini-implants are inserted first, and only then is the orthodontic appliance attached to them. This procedure can be referred to as 'TADs-first'.

The orthodontic appliance may not fit perfectly due to inaccuracies in the process (impression, fabrication, etc.), however, and in such cases it therefore cannot be inserted. Thus, the concept of placing the appliance first and then adding the mini-implants for skeletal anchorage has now attracted interest; this approach can be referred to as the 'appliance-first' concept. For this reason, a new coupling option is now presented by means of a special double-barrel internal thread that allows angular stable coupling of the mini-implant to the orthodontic appliance. Angular stable screw connections allow the mini-implant to be inserted even with a misangulation of up to 15 degrees without compromising stability. This feature makes it possible to place the mini-implants only after the orthodontic appliance has been inserted and, at the same time, to achieve a tilt-stable coupling. This offers a new possibility to implement the appliance-first principle in clinical practice (BENEFIT Direct System, TADMAN).

Case report

A 48-year-old woman first visited the orthodontic practice run by WS, JH and JF in Cologne, Germany, in October 2018. After her dental practitioner told her that her maxillary left first molar needed to be extracted and replaced with a dental implant or fixed prosthodontic restoration, she felt the desire to change her dental and oral situation and requested an invisible orthodontic treatment alternative to resolve the crowding in both arches.

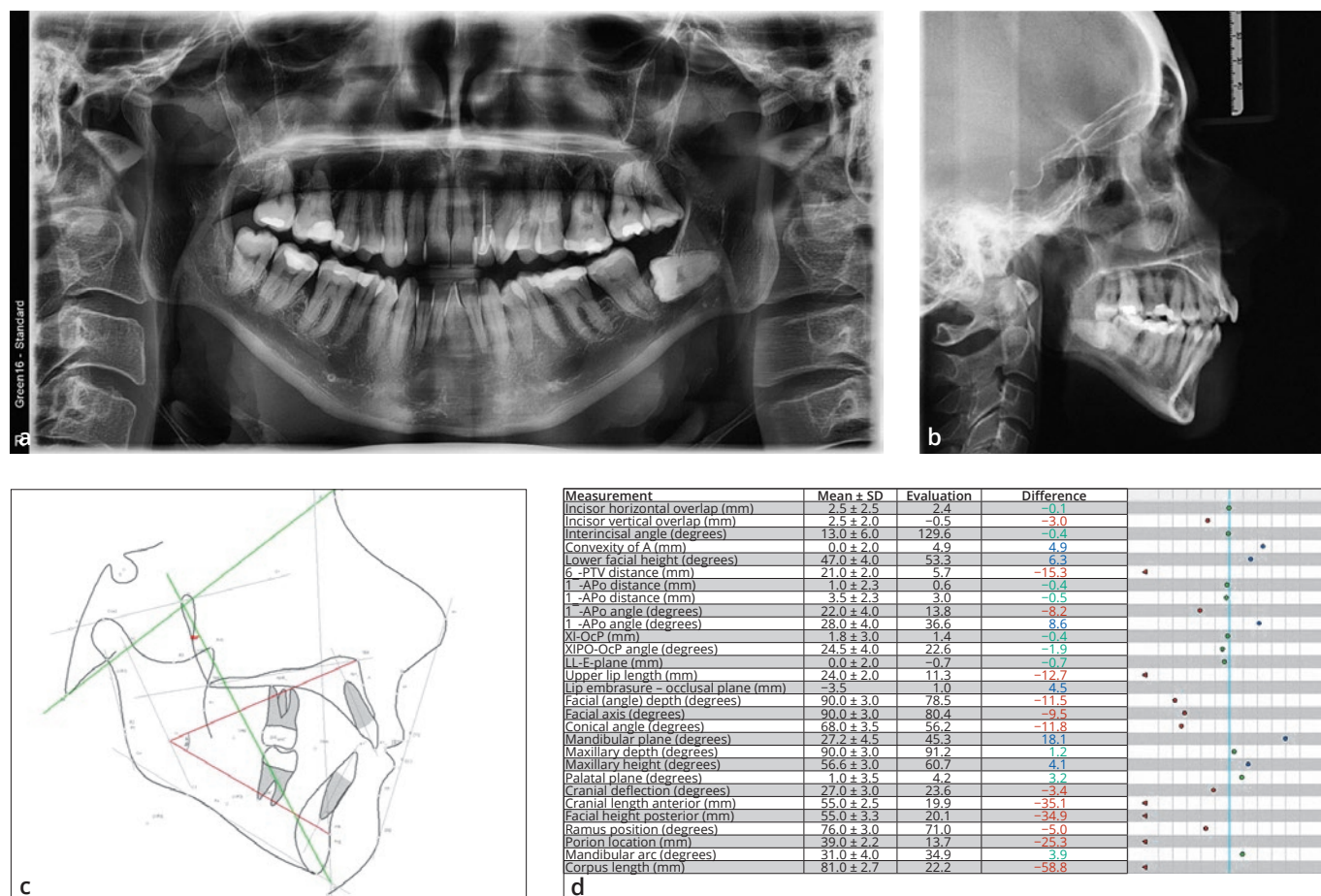
The clinical extraoral examination showed a relatively long face with a reverse smile arc and a large nasolabial angle (Fig 1). Mouth closure revealed severe tension of the lip muscles. Intraoral diagnostics showed a narrow maxilla with moderate crowding and a reverse smile arc. The anterior mandible demonstrated severe crowding, with the mandibular right central incisor in a 90-degree rotated position. Additionally, the patient showed an anterior open bite



Figs 1a-h Pretreatment situation. (a to c) Extraoral records show a reverse smile arc, large nasolabial angle and difficulty in closing the mouth. (d to h) Intraoral records: the maxillary left first molar had just been extracted and suturing material was still in situ. The patient had a narrow maxilla with infraposition of incisors and supraposition of premolars. The mandible showed severe crowding with 90-degree rotation of the mandibular left central incisor. Reverse articulation of the maxillary right second molar/the mandibular right first and second molars and anterior open bite were present. Direct bonded vertical rectangular attachments had already been placed on the maxillary right second premolar to lateral incisor, maxillary left second premolar to lateral incisor, mandibular left canine to second premolar and mandibular right canine to second premolar.

of 2 mm, Angle Class I on the right side and Angle Class II of the width of half a premolar on the left side. The maxillary right second molar and the mandibular right first molar occluded in a reverse articulation. The gingival phenotype was thin and multiple recessions were present (Fig 1). A vertical growth pattern was identified with a bialveolar protrusion in both arches (Fig 2). The short screening test revealed no signs of craniomandibular dysfunction.

As multiple orthodontic problems were present in this case, a decision was made to perform intraoral scanning and finalise the orthodontic treatment planning virtually. Vertical direct bonded attachments (Fig 1) were applied on the maxillary and mandibular canines and premolars prior to intraoral scanning. The scan data as well as intra- and extraoral photographs were then incorporated into the ClinCheck (Align Technology, San Jose, CA, USA) treatment plan.



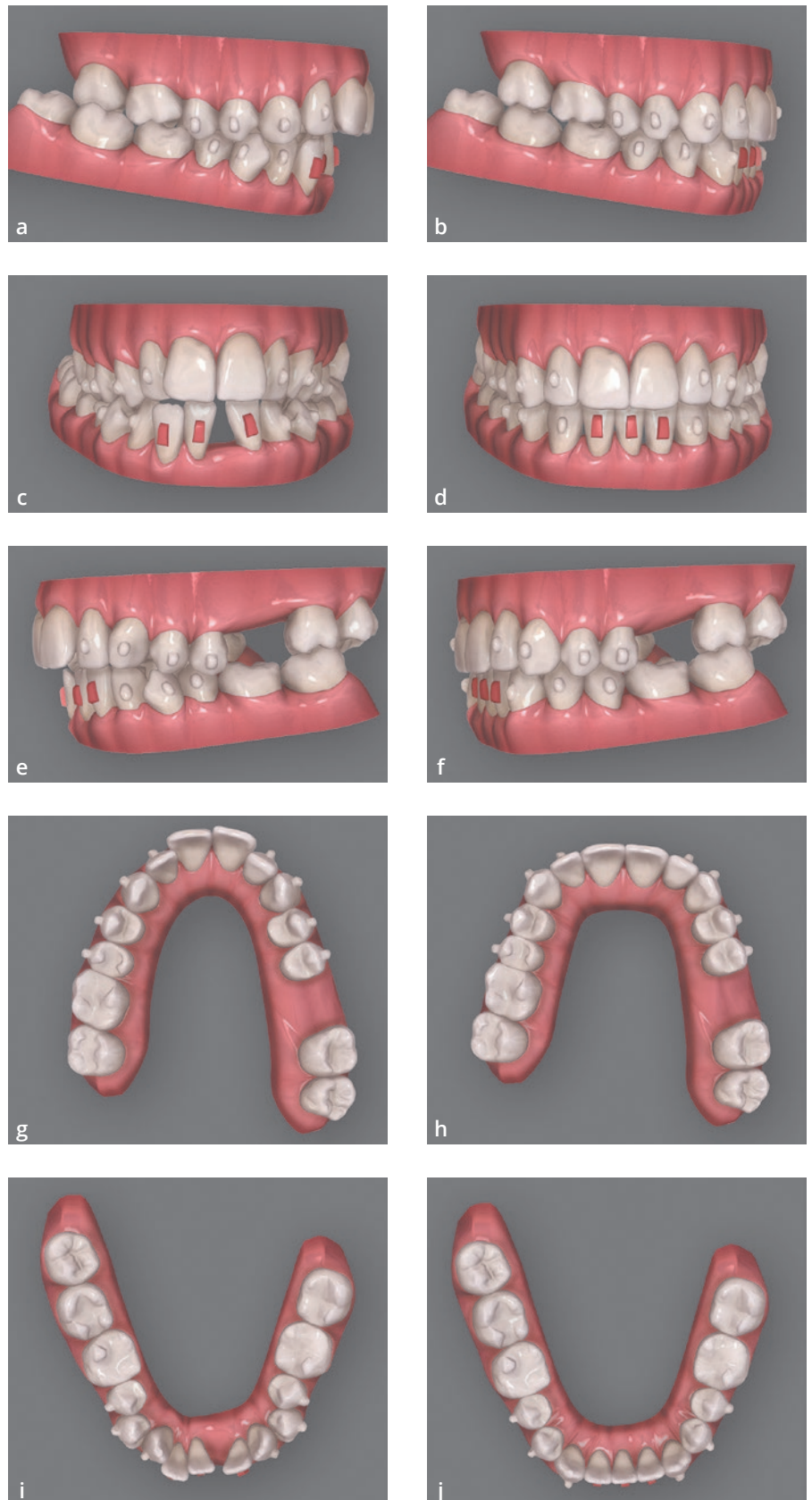
Figs 2a-d (a) Initial panoramic radiograph and (b) lateral cephalogram before extraction of the maxillary left first molar. The mandibular left third molar was displaced and impacted and extraction was advised. (c and d) Values gained on the lateral radiograph. SD, standard deviation.

The patient was informed about different treatment alternatives regarding the extraction space for the maxillary left first molar. Due to the amount of space and the loss of alveolar bone, dental implantation required additional bone augmentation with a more invasive procedure; however, the patient realised that orthodontic space closure was a possibility and therefore specifically requested this treatment option. As skeletal anchorage in combination with a Mesialslider was necessary for a predictable result in the present case, the patient was referred to BW at the University of Dusseldorf, Dusseldorf, Germany for further consultation on this matter and potential collaboration.

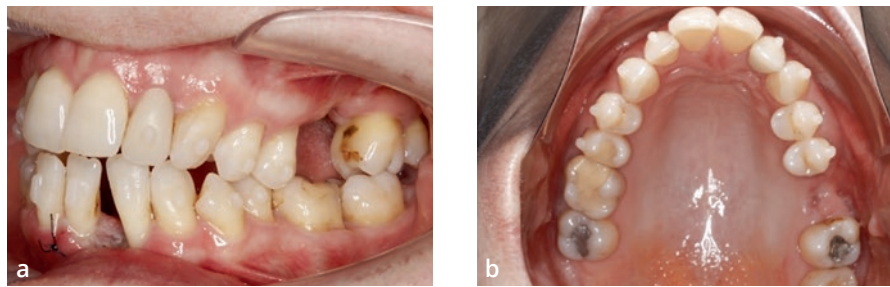
As crowding was only moderate in the maxilla, it was addressed with anterior expansion and interproximal reduction (IPR) only. Anterior retrusion was also planned. No additional incisor extrusion was needed as reclination already provided relative extrusion and thus led to improve-

ment of the open bite and, extraorally, the smile arc. Over the entire course of treatment, the maxillary right second molar to the left second premolar were covered by aligners. The maxillary left second and third molars were mesialised separately with the Mesialslider inserted by BW; aligner treatment was omitted during this phase.

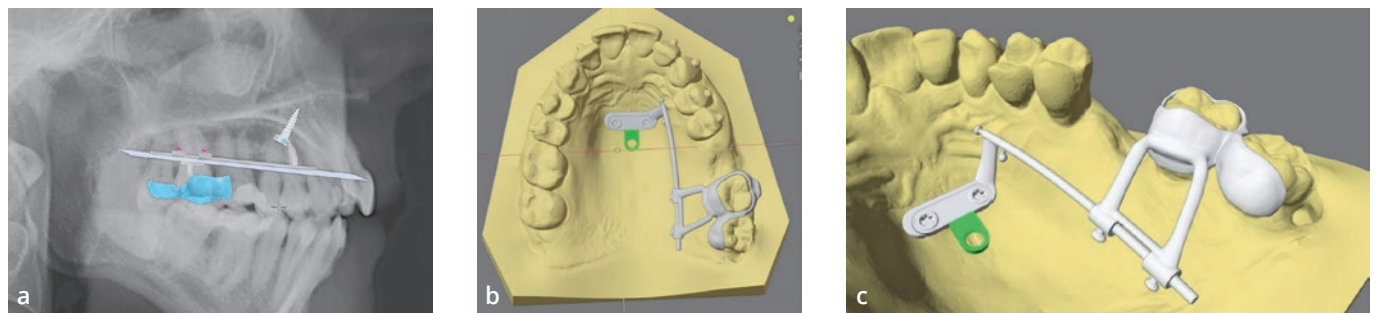
Several virtual treatment simulations were identified to approach the mandibular anterior crowding. As little expansion and incisor proclination as possible were planned to avoid worsening the gingival recession. The patient was informed that incisor extraction would be a feasible treatment alternative to address crowding. It soon became clear that the lack of space was too great for the crowding to be resolved with IPR alone. Due to the severe crowding and the position of the mandibular left central incisor, a single extraction of the mandibular left central incisor was considered the optimal choice (Fig 3).



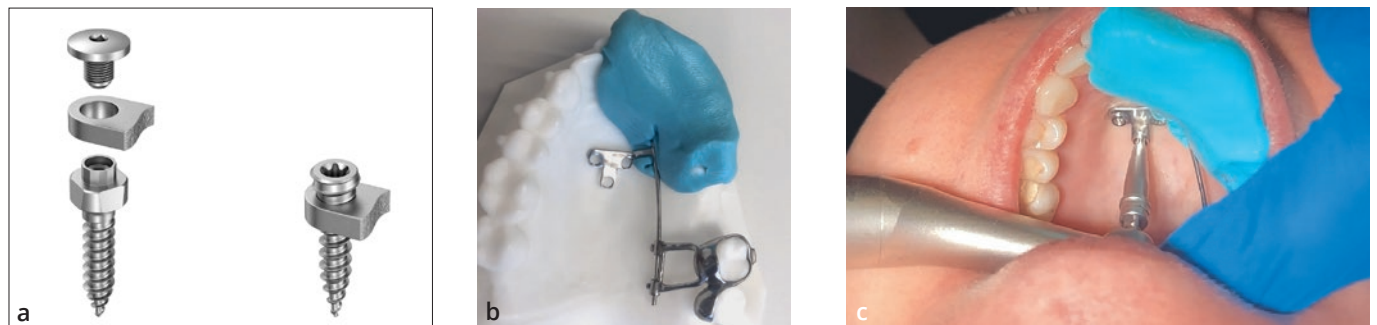
Figs 3a-j Intraoral situation transferred into the ClinCheck and simulation of the potential treatment outcome with extraction of the mandibular left central incisor and space closure with vertical rectangular attachments on all the mandibular anterior teeth.



Figs 4a-b Intraoral situation after extraction of the maxillary left first molar and the mandibular left central incisor with insertion of aligner #1.



Figs 5a-c Virtual implant positioning (a) and design of the Mesialslider (b and c).



Figs 6a-c (a) Comparison of conventional BENEFIT and BENEFIT Direct mini-implants. (b and c) With the BENEFIT Direct system, the slider is positioned correctly using a silicone key. (c) Mini-implants are only placed after insertion of the Mesialslider.

The first virtual treatment plan included 47 aligners. The mandibular left central incisor was extracted just before aligner #1 was inserted (Fig 4). Staging was doubled for uprighting of the roots of the mandibular left lateral incisor and right central incisor. Vertical rectangular attachments were placed on the mandibular right central and left and right lateral incisors for angulation control.

Mesialslider

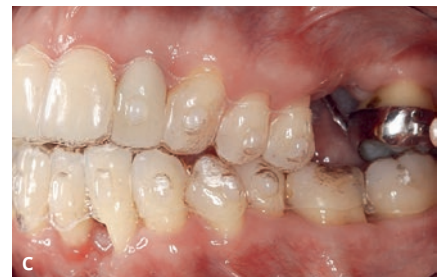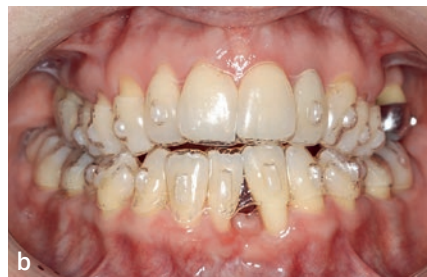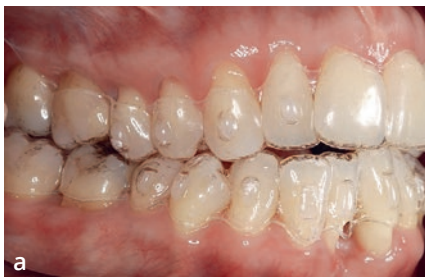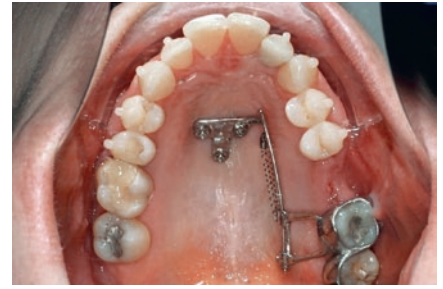For planning and fabrication of the Mesialslider, the maxillary scan and lateral cephalogram were uploaded to the TADMAN.de portal. Virtual implant positioning and design of the Mesialslider (Fig 5) were performed and subse-

quently approved by the dental practitioner. Because of the pronounced and asymmetrical need for anchorage, a median posterior mini-implant (2 × 7 mm, BENEFIT Direct System) was planned for the patient in addition to the two paramedian mini-implants (2 × 9 mm, BENEFIT Direct System) (Fig 6a) (tripodal support).

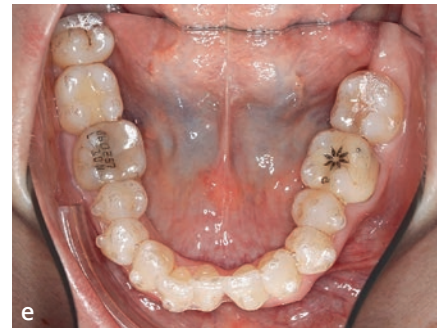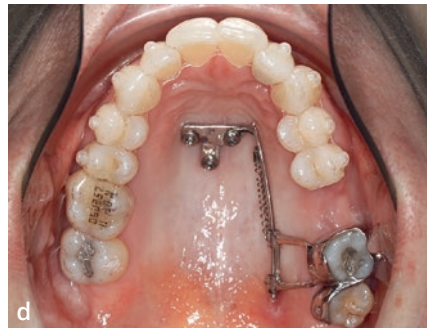The digitally designed Mesialslider consisted of a round slider bar and a double shell for the maxillary left second and third molars with two tubes. The shells were designed with a gap of 0.05 mm between the metal and tooth surfaces to allow space for the adhesive bond (Fig 5).

The Mesialslider was then fabricated by selective laser sintering. Insertion of the mini-implants and incorporation

Fig 7 Mesialslider with a NiTi tension spring (200 g) in situ. Three mini-implants were inserted in the anterior palate to provide maximum anchorage for unilateral mesialisation. The Mesialslider was inserted with occlusal shells at the University of Düsseldorf.



Figs 8a-e Intraoral records with aligner #10 in situ show good aligner fit. Additional vertical rectangular attachments were placed on the mandibular incisors for better angulation control when closing the extraction space. Slight decubitus was visible at the most distal point of the Mesialslider. The slider was covered with Triad Gel (Dentsply Sirona, Charlotte, NC, USA) to avoid further irritation of the palatal mucosa.



of the appliance took place in a single appointment: after local anaesthesia, the Mesialslider was positioned in the correct location using a silicone transfer key, the shells were attached to the molars (Fig 6a) and then the BENEFIT Direct mini-implants were placed (Fig 6c). The appliance was activated with NiTi closing springs (200 g) (Fig 7). The aligners were initially extended only up to the maxillary left second premolar in the second quadrant so that the aligners and Mesialslider could be used without the need for synchronisation (Fig 8).

Due to suboptimal oral hygiene and inadequate cleaning of the region around the mini-implants, chronic inflammation of the mucosa occurred in the anterior palate. If this

inflammation is superficial, the mini-implants remain sufficiently stable. It is not advisable to remove the implants due to chronic inflammation. The patient was motivated to improve her oral hygiene and application of chlorhexidine gel (e.g., Chlorhexamed Mundgel 10 mg/g, GlaxoSmithKline Consumer Healthcare, Munich, Germany) was recommended, which improved the inflammatory state.

Course of treatment

The orthodontic control visits took place every 10 weeks in the office run by WS, JF and JH. At the first control appointment, the patient demonstrated good aligner fit, but mesialisation of the maxillary left molars had not yet started

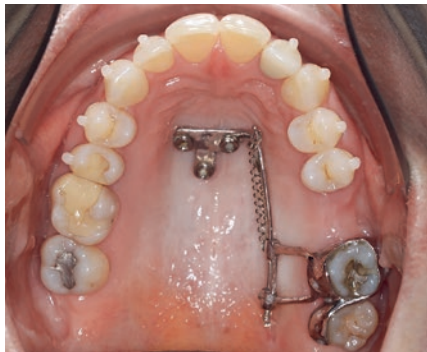

Fig 9 Intraoral situation after 20 weeks of treatment: mesialisation is in process.

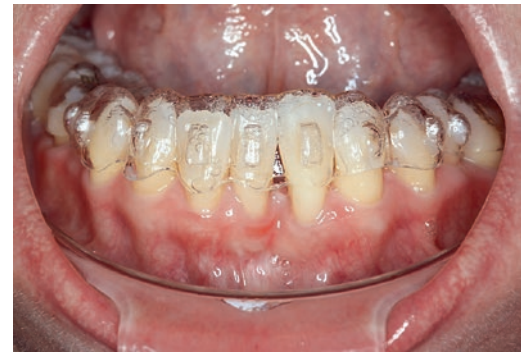
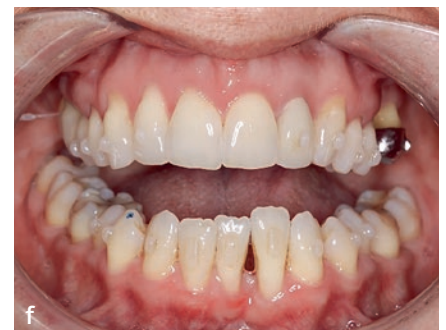
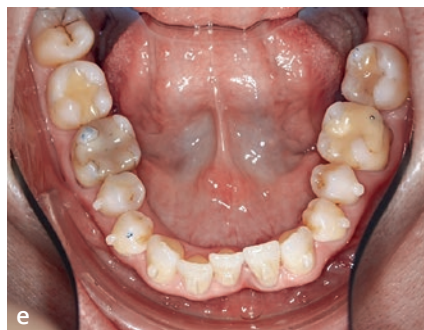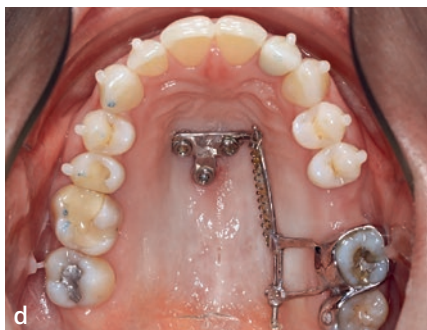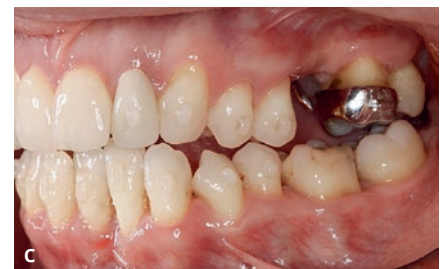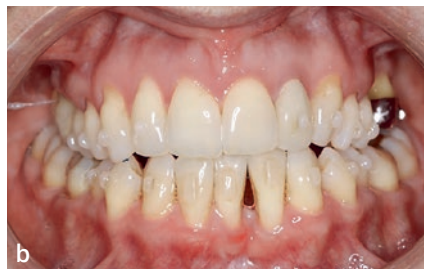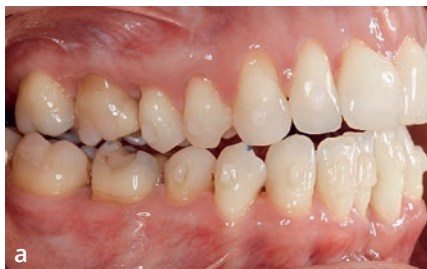Fig 10 The fit was poor with aligner #28, so a new scan was performed for additional aligners.



Figs 11a-f Intraoral records after 28 weeks of treatment for additional aligners. At this stage, around 3 mm mesialisation had occurred. Vertical differences appeared in the mandibular incisor region.

(Fig 8). To supplement the NiTi closing spring, a power chain was added later.

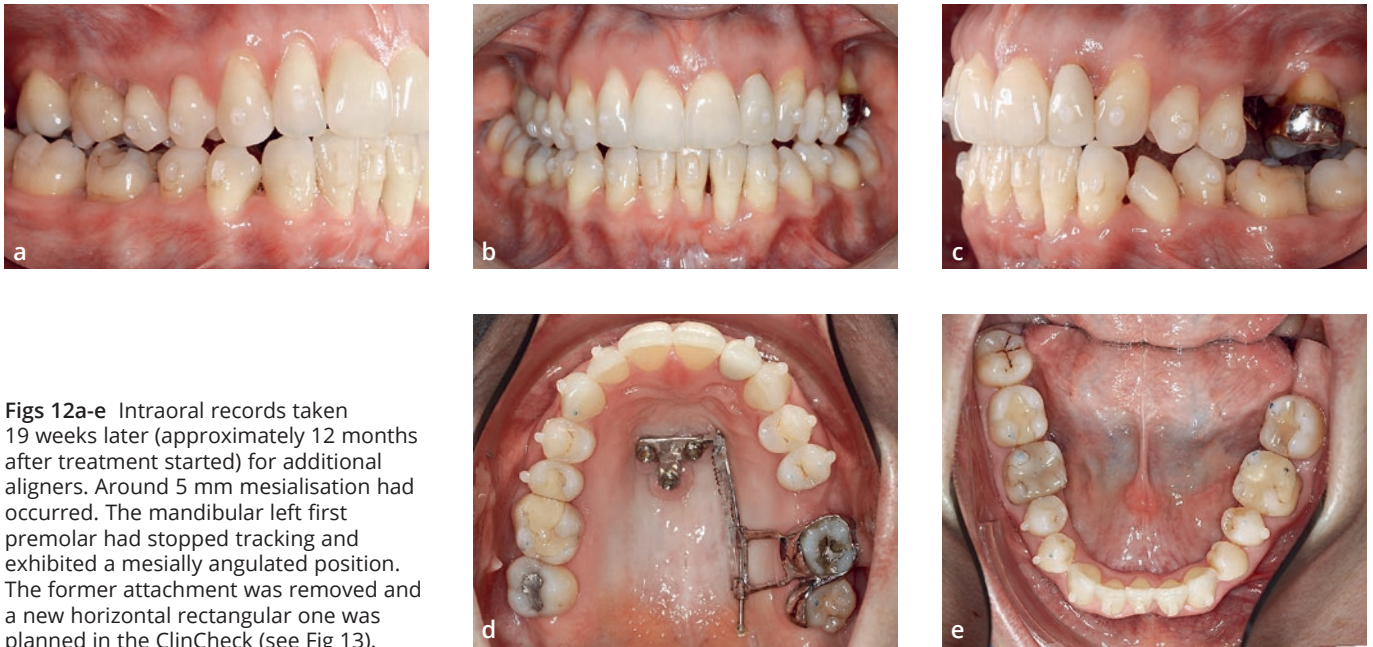
Good aligner fit was also demonstrated at the second control visit. Mesialisation began, with around 1 mm measured at the distal end of the Mesialslider (Fig 9). The NiTi closing spring was activated again.

After a further 8 weeks (aligner #28), another millimetre of mesialisation was recorded, but the aligner fit, particularly in the mandibular anterior region, was insufficient (Figs 10 and 11). A new scan had to be taken and additional aligners with the same therapeutic goal were produced.

Figure 12 shows the result after the first phase of treatment: the extraction gap in the mandibular right central

incisor area had already been closed, but the red-white aesthetic was still insufficient due to a large black triangle in this area (Fig 12b). In addition to the further uprighting of the neighbouring roots, IPR was planned to reduce this black triangle as much as possible and to establish a physiological level of the gingiva.

Following placement of 47 aligners and a total treatment time of approximately 1 year, the patient presented with 5 mm mesialisation of the maxillary left second and third molars and an improperly fitting aligner in the mandible. The mandibular left first premolar was no longer tracking; thus, the attachment was removed and a new intraoral scan was performed for additional aligners



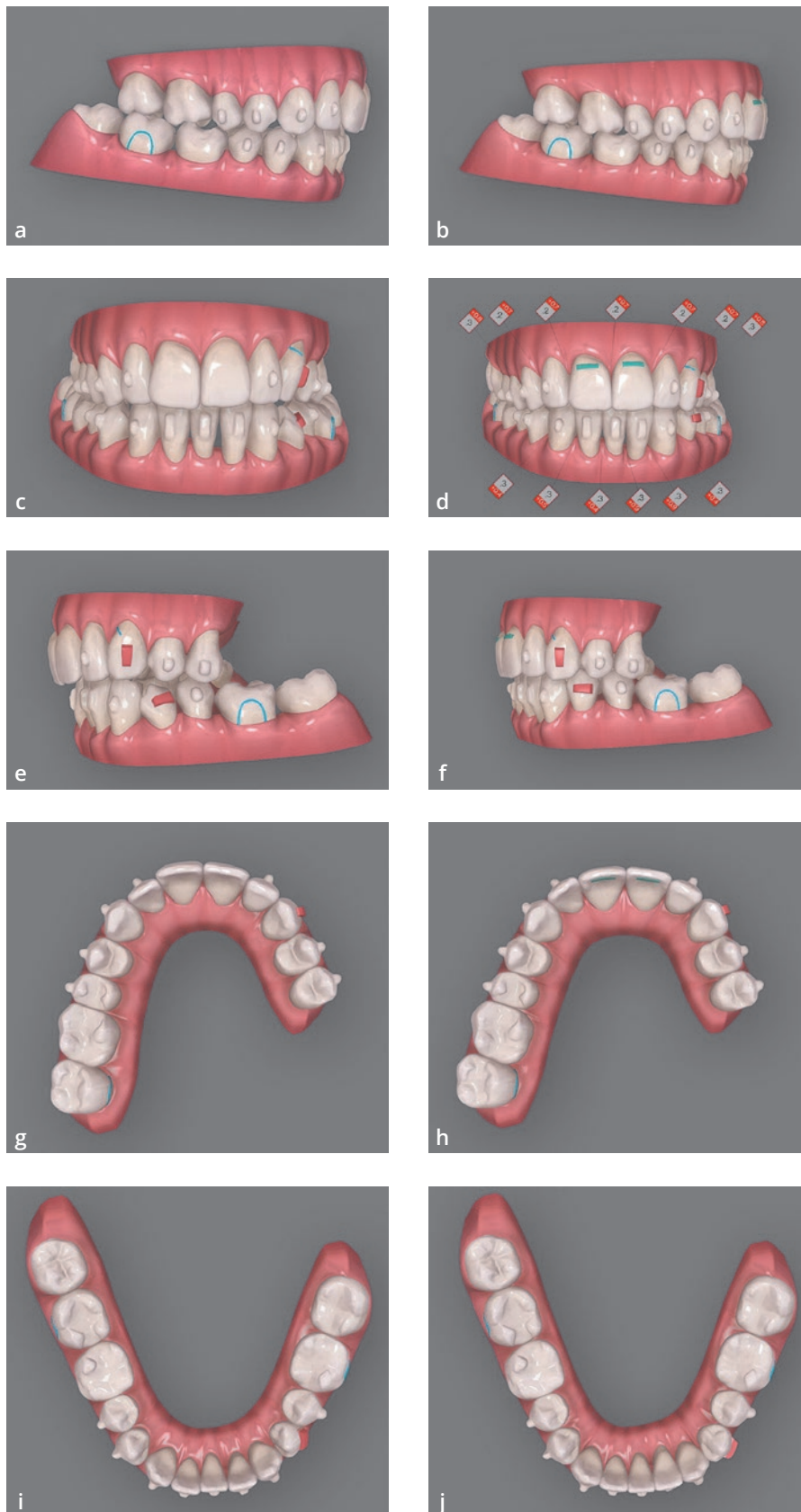
Figs 12a-e Intraoral records taken 19 weeks later (approximately 12 months after treatment started) for additional aligners. Around 5 mm mesialisation had occurred. The mandibular left first premolar had stopped tracking and exhibited a mesially angulated position. The former attachment was removed and a new horizontal rectangular one was planned in the ClinCheck (see Fig 13).

(Fig 12). Button cutouts were added to the palatal surface of the maxillary right first molar and the buccal surfaces of the mandibular first molars for criss-cross elastics and Class II elastics (1/8 medium [4 oz] and 3/16 medium [4 oz]; Forestadent, Pforzheim, Germany) (Fig 13). Figure 14 shows the mesialisation progress of the maxillary left second and third molars after 1 year of treatment. Figure 15 shows the intraoral situation with the mandibular left first premolar still in a mesially tipped position.

The space in the maxillary left first molar area was closed after a total treatment time of 2 years (Fig 16). The Mesialslider was then removed. At the same time, the maxillary left second and third molars exhibited an intruded position; as a result, a further scan and additional aligners with the help of up and down elastics were required to adjust the occlusion. A small black triangle remained in the mandibular incisor region (Fig 17). Further root uprighting and IPR were planned so the papilla could recover even more for an improved red-white aesthetic (Fig 18). An additional phase with 28 aligners for further alignment and improvement of occlusion was planned in the ClinCheck (Fig 18). A gap remained mesial to the maxillary left second and third molars; due to the force component of the Mesialslider, these teeth need further vertical movement to end

in an occlusal relationship. Button cutouts were inserted buccally on all molars on the left side and up and down elastics were worn in addition to aligners (Fig 18f). The panoramic radiograph after removal of the Mesialslider is shown in Fig 19. The maxillary left second and third molars showed good root inclination, as did the roots of the mandibular anterior teeth which were parallel after closure of the extraction space. The mandibular third molar was still in situ and surgical extraction was again advised.

Figures 20a to c present the extraoral records at the end of treatment, showing a harmonious smile arc following the curvature of the lower lip and relaxed lip closure. The post-treatment intraoral records showed well aligned arches with Class I occlusion on both sides (Figs 20d to i). A tuberosion midline was achieved and the periodontal situation in the mandibular incisor region was satisfactory. No final lateral cephalogram was performed for this patient as in Germany, for a radiograph to be taken, there must be a medical reason and a justifying indication under the Radiation Protection Ordinance (X-ray Regulation of the Federal Republic of Germany). Since a surgical procedure was excluded in the treatment of the present patient, cephalometric images were not taken due to the regulation for the protection of patients from damage by x-rays.



Figs 13a-j Additional phase with 28 aligners for further alignment and improvement of occlusion. Button cutouts were planned according to the first treatment phase on the mandibular left first molar and the mandibular right second molar buccally and on the maxillary right second molar. Up to 0.3 mm IPR was necessary on the maxillary and mandibular anterior teeth for further alignment. The patient continued to wear Class II elastics on the left side and crisscross elastics from the maxillary to the mandibular right second molar to improve the reverse articulation situation.

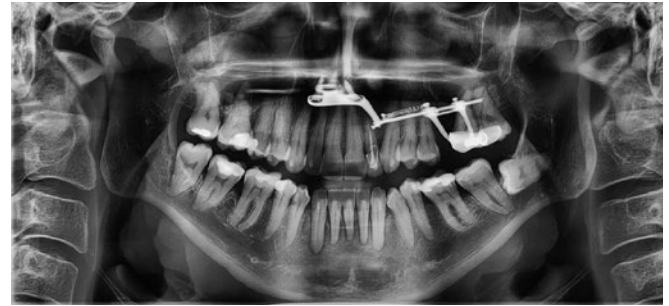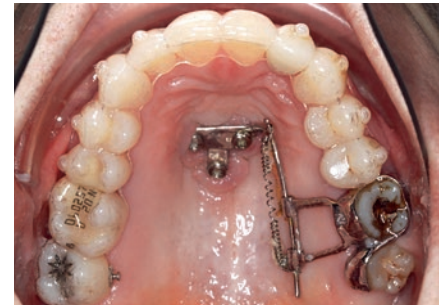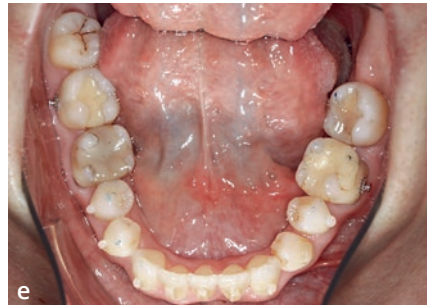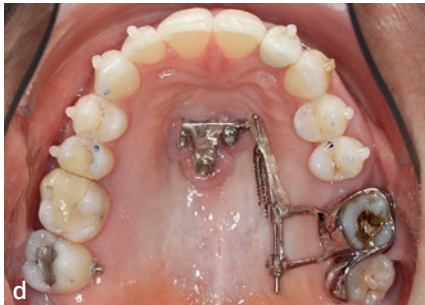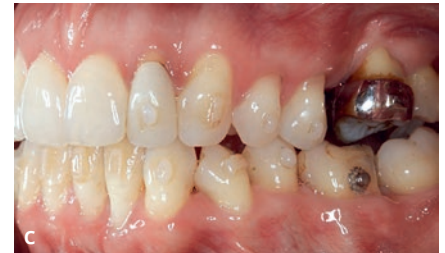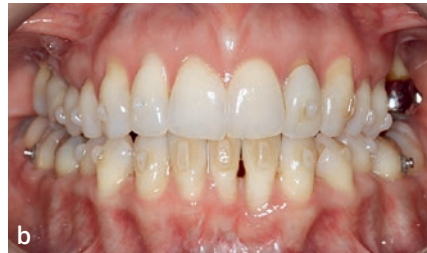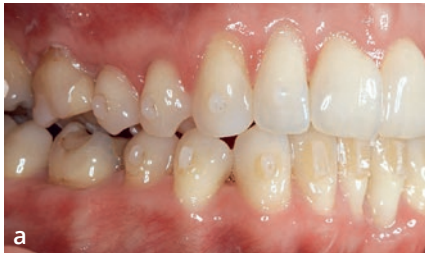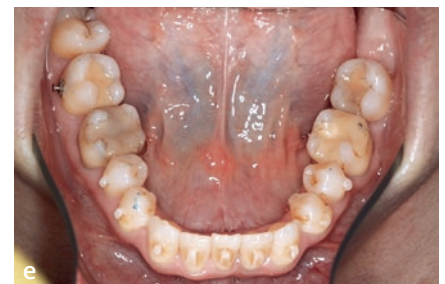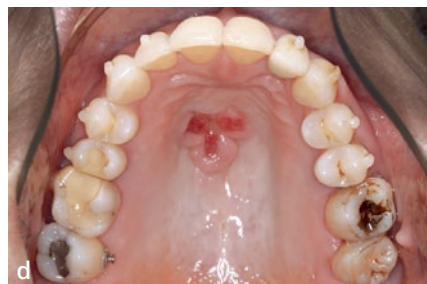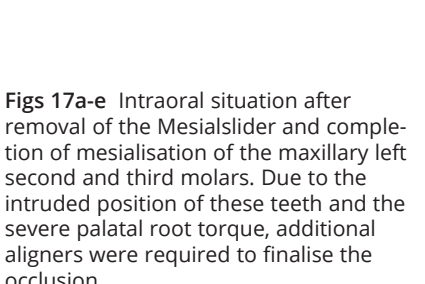


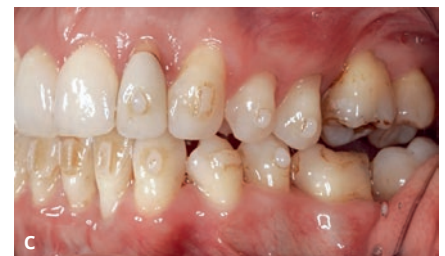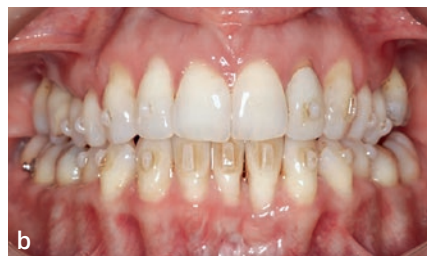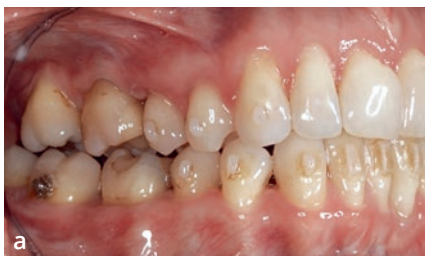Fig 14 Panoramic radiograph after 12 months of treatment.

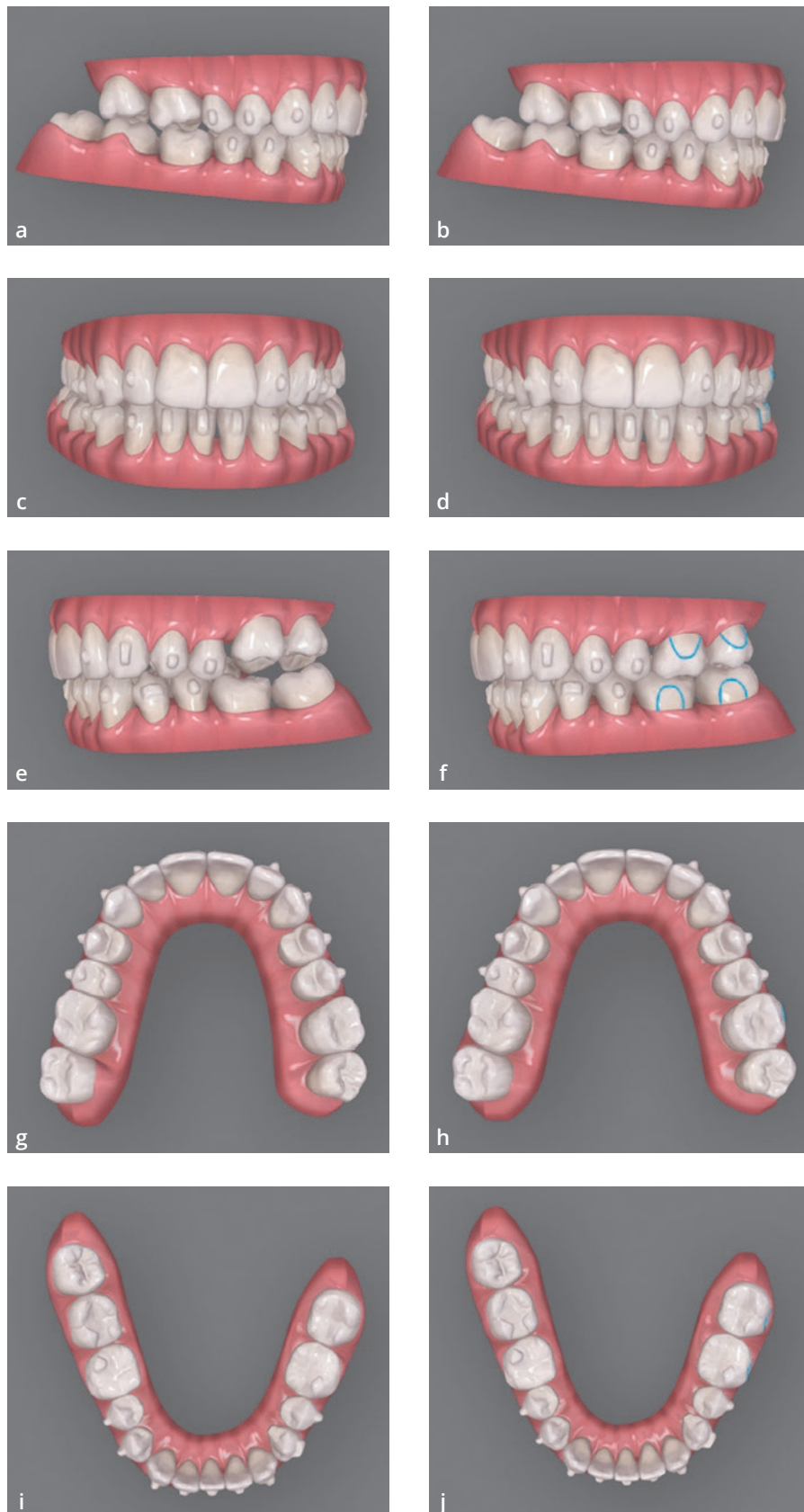


Figs 15a-e Intraoral records for additional aligners. The mandibular left first premolar had stopped tracking again even though there was space for the tooth to be uprighted distally.

Fig 16 After 2 years of treatment, space closure was achieved in the region of the maxillary left first molar and the mini-implants and the Mesialslider were removed.

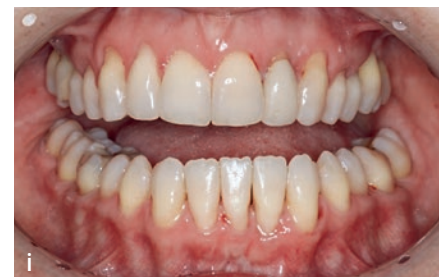
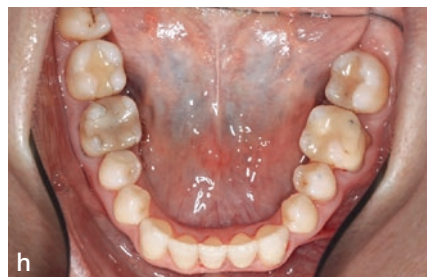
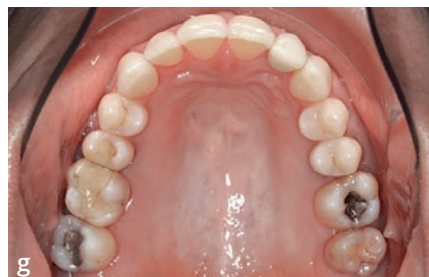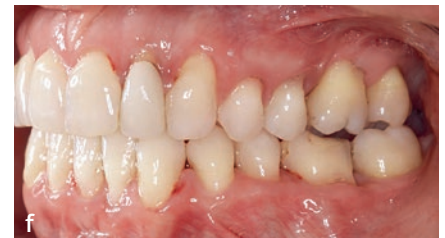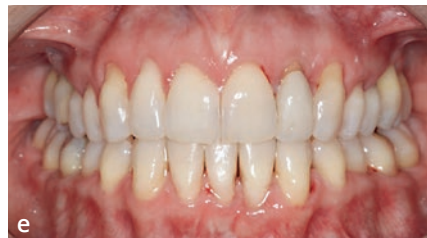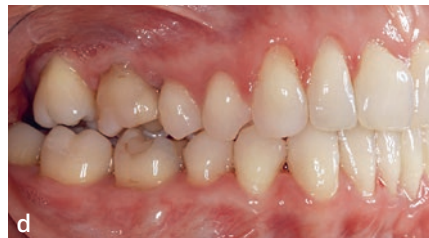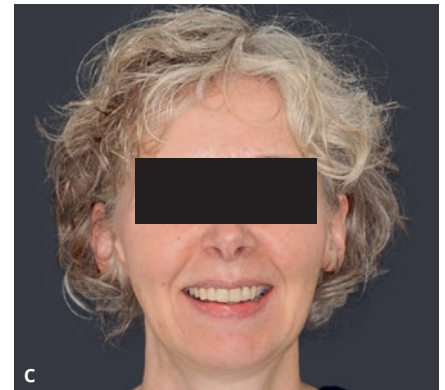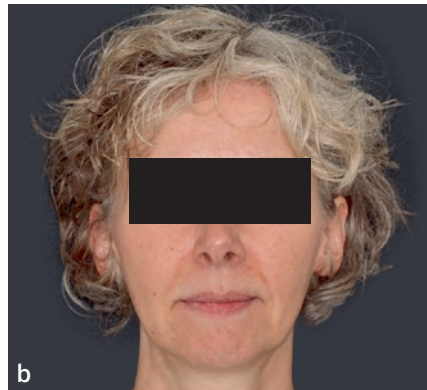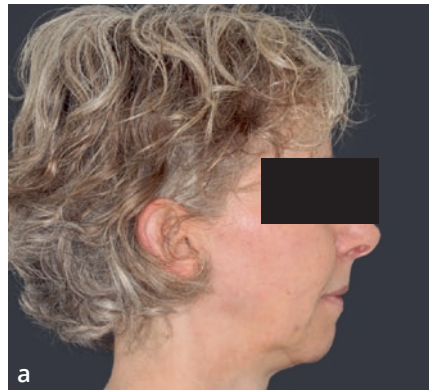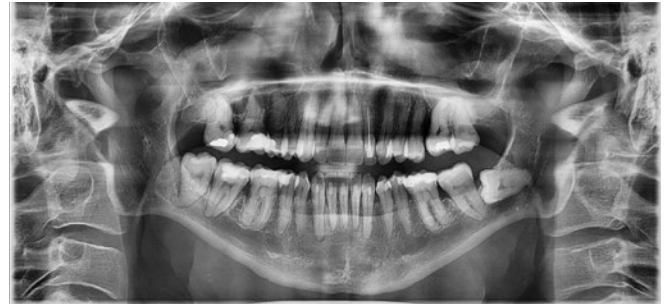Figs 17a-e Intraoral situation after removal of the Mesialslider and completion of mesialisation of the maxillary left second and third molars. Due to the intruded position of these teeth and the severe palatal root torque, additional aligners were required to finalise the occlusion.

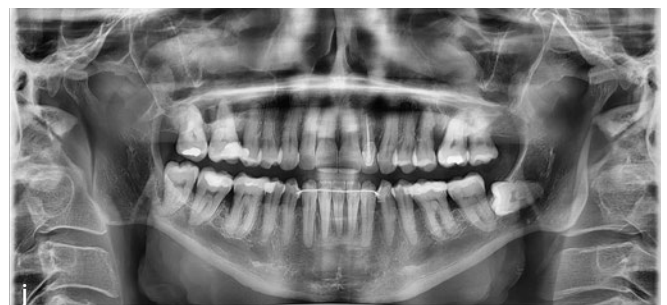

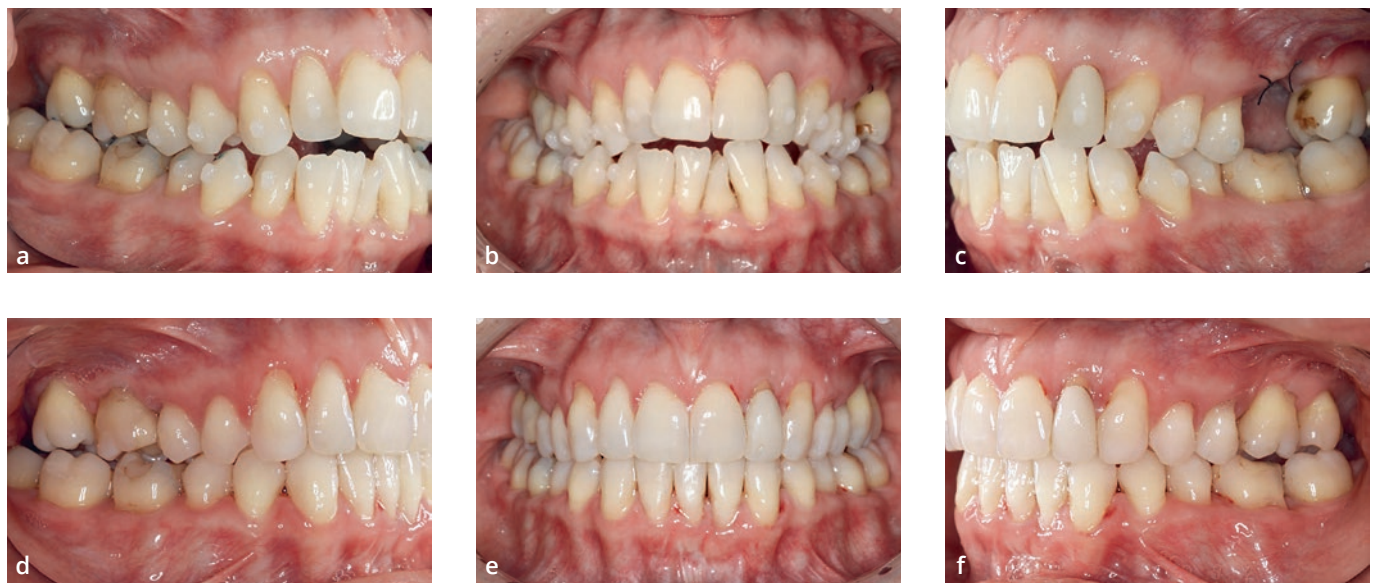Figs 18a-j ClinCheck simulation of the final treatment phase with an additional 25 aligners after removal of the Mesial-slider and including the crowns of the maxillary left second and third molars, comparing the initial situation and the virtually planned treatment outcome. A gap remained mesial to the maxillary left second and third molars due to the force component of the Mesialslider so these teeth required further vertical movement to end in an occlusal relationship. Button cutouts were placed buccally on all molars on the left side and up and down elastics were worn in addition to aligners.

Fig 19 Panoramic radiograph taken after removal of the Mesialslider. The maxillary left second and third molars showed good root inclination, with the roots of the molars and the mandibular anterior teeth being parallel after closure of the extraction space. The mandibular left third molar was still in situ and surgical consultation was again advised.



Figs 20a-j (a to c) Posttreatment extraoral records show a harmonious smile arc following the curvature of the lower lip and relaxed lip closure. (d to i) Posttreatment intraoral records show well aligned arches with Class I occlusion on both sides after aligner treatment. A tuberson midline was achieved and the periodontal situation in the mandibular incisor region was satisfactory, with the black triangles having been closed almost completely. (j) Panoramic radiograph taken 5 months after treatment, showing a stable bone situation after mesialisation of the maxillary left second and third molars into the extraction space of the maxillary left first molar.





Figs 21a-f Comparison of the pretreatment and posttreatment situation after therapy with the Mesialslider and aligners. The gap left by the extracted maxillary left first molar was closed completely, the anterior open bite was closed and, with extraction of the mandibular left central incisor, the mandibular anterior teeth were aligned and a functional anterior relationship was achieved.

A comparison from before and after treatment with a combination of a Mesialslider and aligner orthodontics is shown in Figs 21 and 22. The massive gap left after extraction of the maxillary left first molar was closed completely, the anterior open bite was closed and with the extraction of the mandibular left central incisor, the mandibular anterior teeth were aligned and a functional anterior relationship was achieved. The amount of movement performed including mesialisation and expansion is shown in Fig 23 and in the superimposition of the initial and final scans in Fig 24.

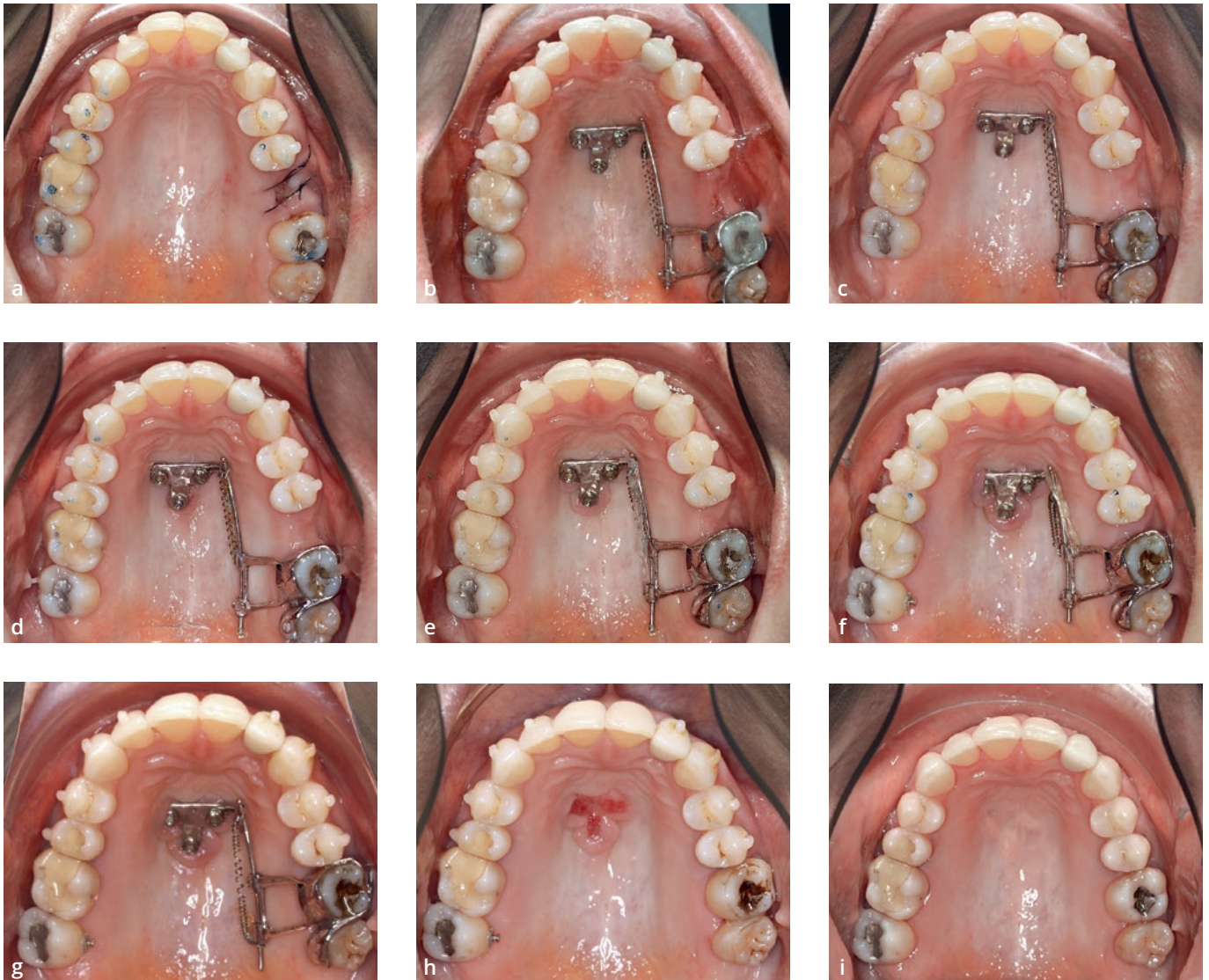The whole treatment procedure included a total of 90 aligners. After a treatment period of 2.5 years, the mandible and maxilla were aligned, the attachments were removed and the retention phase was initiated. A lingual fixed retainer was inserted from the mandibular left first premolar to the mandibular right first premolar and a removable aligner was placed in the maxilla for night-time use.

Discussion

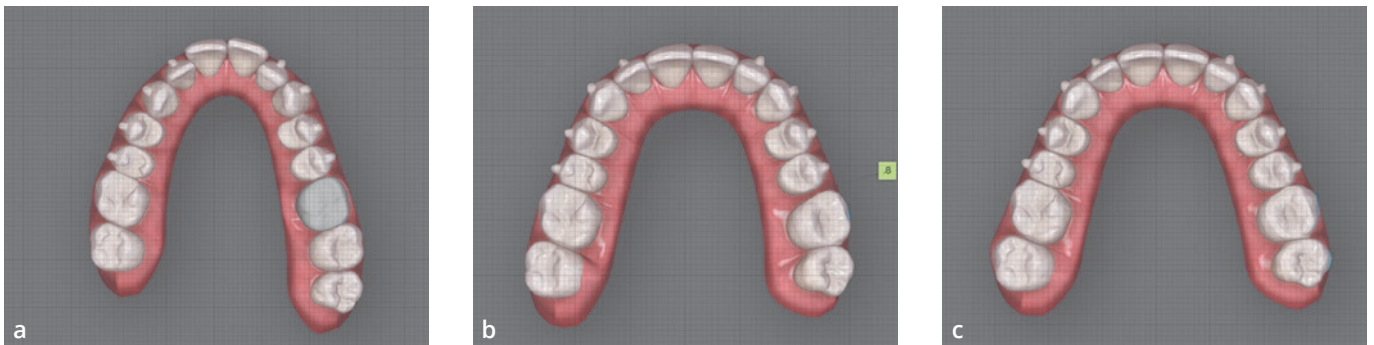
Performing complex orthodontic treatment with aligners is no longer considered an unusual approach; however, precise planning and patient compliance are vital for success. Unfortunately, due to insufficient aligner wear, several phases had to be performed with the present patient to obtain the desired result. Improved compliance could certainly have reduced the number of additional aligner phases.

Particular movements, such as unilateral bodily molar mesialisation of 10 mm, as presented in this patient, are only predictable with skeletally anchored devices that provide maximum anchorage. As the Mesialslider was fixed solely to the mini-implants, there was direct anchorage for mesialisation. Implant loss rates are very low in the anterior palate; thus, the present authors relied on a secure, non-compliance appliance.

Molar mesialisation with use of the Mesialslider (mini-implants and sliding mechanics) has been described



Figs 22a-i Course of treatment after extraction of the maxillary left first molar and a combination of aligner therapy and mesialisation of the maxillary left second and third molars with the Mesialslider and complete space closure.



Figs 23a-c (a) Initial situation transferred into the ClinCheck; (b) situation after removal of the Mesialslider with space remaining mesial to the maxillary left second molar; (c) final planned situation showing the amount of expansion and mesialisation.

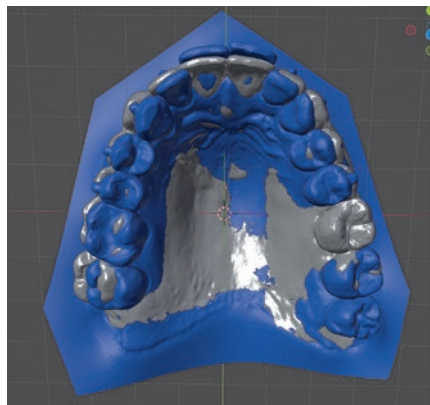


Fig 24 Superimposition of the initial and final scans showing the amount of mesialisation performed on the maxillary left second and third molars.

in the literature and has been promoted particularly in case reports for bilateral use^{45,52}. The present report demonstrated that unilateral space closure is also possible, and illustrated the new concept of an ‘appliance-first’ method for the use of a Mesialslider.

The advantages offered by the ‘appliance-first’ method are that insertion of mini-implants and placement of the appliance can be performed in just one appointment (however, the one-day procedure is also possible if an insertion guide is used⁴⁷), and that there is no risk of misfit of the appliance and the mini-implants. On the other hand, the appliance cannot be removed and reinserted easily for modifications or repairs, for example, and an additional device is needed to hold the appliance in place during mini-implant insertion.

It is important to be aware that when a bodily movement is desired, clinicians usually often see nothing for 2 to 3 months until movement starts. This could be due to the heavy forces that are applied initially with skeletally anchored sliding devices. Tooth movement is interrupted as hyalinisation occurs within the periodontal ligament. Once this phenomenon has been overcome, movement appears to happen relatively fast.

As a point of criticism, extraction of the maxillary left first molar should have ideally taken place only shortly before insertion of the Mesialslider so the regional acceleratory phenomenon could have been better exploited⁵³, and the present authors would take this approach if they were to repeat the treatment procedure.

According to the literature, incisor extraction is effective for the correction of malocclusions, such as moderate to severe anterior crowding^{32,54-56}. It is a treatment alternative

that corrects problems quickly and effectively without compromising the profile. The question of which tooth is extracted requires careful evaluation, and the decision is based on general considerations. Incisor extraction risks loss of the papilla⁵⁷; however, one of the most significant advantages of this treatment method is the treatment time, which can be reduced considerably⁵⁸⁻⁶⁰.

Conclusion

Mini-implant-assisted tooth movement has broadened the limits and boundaries of conventional orthodontic therapy and is being used increasingly as an additional tool in fixed and aligner orthodontics. The combination of the fixed Mesialslider appliance and removable aligners allows bodily movement of the posterior teeth even in large spaces like the one described. Further treatment experience using this combination and further publications about it are required so that deeper knowledge can be gained and it can be included as part of modern orthodontics more often in the future.

Declaration

Prof Dr Benedict Wilmes is the cofounder of TADMAN. The other authors declare that they have no competing interests.

References

1. Robertsson S, Mohlin B. The congenitally missing upper lateral incisor. A retrospective study of orthodontic space closure versus restorative treatment. *Eur J Orthod* 2000;22:697–710.
2. Zachrisson BU. Improving orthodontic results in cases with maxillary incisors missing. *Am J Orthod* 1978;73:274–289.
3. Zachrisson BU, Rosa M, Toreskog S. Congenitally missing maxillary lateral incisors: Canine substitution. *Point. Am J Orthod Dentofacial Orthop* 2011;139:434–438.
4. Kern M. Adhesive bridges today. *Quintessenz* 1990;41:1145–1157.
5. Kern M, Passia M, Sasse M, Yazigi C. Ten-year outcome of zirconia ceramic cantilever resin-bonded fixed dental prostheses and the influence of the reasons for missing incisors. *J Dent* 2017;65:51–55.
6. Re S, Cardaropoli D, Corrente G, Abundo R. Bodily tooth movement through the maxillary sinus with implant anchorage for single tooth replacement. *Clin Orthod Res* 2001;4:177–181.
7. Svejda M, Stobl N, Bantleon HP. Zahnbewegung durch die Kieferhöhle – ein Fallbericht. *Inf Orthod Kieferorthop* 2008;40:249–254.

8. Wehrbein H, Riess H, Meyer R, Schneider B, Diedrich P. Bodily movement of teeth in atrophic jaw segments [in German]. *Dtsch Zahnarztl Z* 1990;45:168–171.
9. Lindskog-Stokland B, Hansen K, Ekestubbe A, Wennström JL. Orthodontic tooth movement into edentulous ridge areas – A case series. *Eur J Orthod* 2013;35:277–285.
10. Lindskog-Stokland B, Wennström JL, Nyman S, Thilander B. Orthodontic tooth movement into edentulous areas with reduced bone height. An experimental study in the dog. *Eur J Orthod* 1993;15:89–96.
11. Hom BM, Turley PK. The effects of space closure of the mandibular first molar area in adults. *Am J Orthod* 1984;85:457–469.
12. Stepovich ML. A clinical study on closing edentulous spaces in the mandible. *Angle Orthod* 1979;49:227–233.
13. Ludwig B, Zachrisson BU, Rosa M. Non-compliance space closure in patients with missing lateral incisors. *J Clin Orthod* 2013;47:180–187.
14. Buschang PH, Chastain D, Keylor CL, Crosby D, Julien KC. Incidence of white spot lesions among patients treated with clear aligners and traditional braces. *Angle Orthod* 2019;89:359–364.
15. White DW, Julien KC, Jacob H, Campbell PM, Buschang PH. Discomfort associated with Invisalign and traditional brackets: A randomized, prospective trial. *Angle Orthod* 2017;87:801–808.
16. Abbate GM, Caria MP, Montanari P, et al. Periodontal health in teenagers treated with removable aligners and fixed orthodontic appliances. *J Orofac Orthop* 2015;76:240–250.
17. Miethke RR, Vogt S. A comparison of the periodontal health of patients during treatment with the Invisalign system and with fixed orthodontic appliances. *J Orofac Orthop* 2005;66:219–229.
18. Husari A, Dieterle MP, Jung BA. Insights into the mechanobiology of the periodontium. *J Aligner Orthod* 2021;5:91–97.
19. Robertson L, Lee D, Eimar H, El-Bialy T. Treatment of a challenging Class III malocclusion case using Invisalign clear aligners and micro-osteoperforation: A case report. *J Aligner Orthod* 2019;3:229–241.
20. Schupp W, Haubrich J (eds). *Aligner Orthodontics: Diagnostics, Biomechanics, Planning, and Treatment*. Berlin: Quintessence Publishing, 2015.
21. Rossini G, Parrini S, Castorflorio T, Deregibus A, Debernardi CL. Efficacy of clear aligners in controlling orthodontic tooth movement: A systematic review. *Angle Orthod* 2015;85:881–889.
22. Dayan W, Aliaga-Del Castillo A, Janson G. Open-bite treatment with aligners and selective posterior intrusion. *J Clin Orthod* 2019;53:53–54.
23. Chang S, Schupp W, Haubrich J, Yeh WC, Tsai MS, Tabancis M. Aligner therapy in treating bimaxillary dentoalveolar protrusion. *J Aligner Orthod* 2019;3:277–301.
24. Couchat D. Prevention of tooth impaction with Invisalign: A case report. *J Aligner Orthod* 2017;1:59–64.
25. Einy S, Elianov O, Aizenbud D. A nonsurgical approach to treat mandibular incisor gingival recession by clear aligners for effective torque correction. *J Aligner Orthod* 2020;4:43–52.
26. Haubrich J, Schupp W. Invisalign treatment in early years to avoid potential extraction treatments – Case reports. *J Aligner Orthod* 2018;2:39–52.
27. Haubrich J, Schupp W. Orofacial orthopaedics: Background and possibility of combination with aligners. *J Aligner Orthod* 2020;4:111–142.
28. Iaracitano B, Gazzotti P, Gazzotti ML, La Valle M, Salas F, Orbez N. Orthodontic aligners in oral rehabilitation. *J Aligner Orthod* 2020;4:143–152.
29. La Valle M, Iaracitano B, Basilico M. Use of aligners to treat buccal bone loss. *J Aligner Orthod* 2020;4:311–330.
30. Mah JK. Clear aligner therapy (CAT) in two hyperdivergent patients. *J Aligner Orthod* 2019;3:107–118.
31. Malekian K, Parrini S, Garino F, Deregibus A, Castorflorio T. Mandibular molar distalization with clear aligners in Class III patients. *J Aligner Orthod* 2019;3:7–14.
32. Palikaraki G, Karamesinis K, Damanakis G. Orthodontic treatment in a periodontal patient with incisor extraction using Invisalign clear aligner system: A case report. *J Aligner Orthod* 2018;2:317–323.
33. Pavone AF, Bazzucchi A, Mancini M, Pasquantonio G. Anterior dental spacing: Invisalign and restorative synergy for tooth size discrepancy management. Two case reports. *J Aligner Orthod* 2018;2:227–237.
34. Schupp W, Haubrich J, Ojima K, Dan C, Kumagai Y, Otsuka S. Accelerated Invisalign treatment of patients with a skeletal Class III. *J Aligner Orthod* 2017;1:37–57.
35. Giancotti A, Mampieri G. Unilateral canine crossbite correction in adults using the Invisalign method: A case report. *Orthodontics (Chic.)* 2012;13:122–127.
36. Kanomi R. Mini-implant for orthodontic anchorage. *J Clin Orthod* 1997;31:763–767.
37. Melsen B, Costa A. Immediate loading of implants used for orthodontic anchorage. *Clin Orthod Res* 2000;3:23–28.
38. Park HS, Bae SM, Kyung HM, Sung JH. Micro-implant anchorage for treatment of skeletal class I bialveolar protrusion. *J Clin Orthod* 2001;35:417–422.
39. Freudenthaler JW, Haas R, Bantleon HP. Bicortical titanium screws for critical orthodontic anchorage in the mandible: A preliminary report on clinical applications. *Clin Oral Implants Res* 2001;12:358–363.
40. Fritz U, Ehmer A, Diedrich P. Clinical suitability of titanium microscrews for orthodontic anchorage-Preliminary experiences. *J Orofac Orthop* 2004;65:410–418.
41. Wilmes B, Rademacher C, Olthoff G, Drescher D. Parameters affecting primary stability of orthodontic mini-implants. *J Orofac Orthop* 2006;67:162–174.
42. Hourfar J, Bister D, Kanavakis G, Lisson JA, Ludwig B. Influence of interradicular and palatal placement of orthodontic mini-implants on the success (survival) rate. *Head Face Med* 2017;13:1–6.
43. Züger J, Pandis N, Wallkamm B, Grossen J, Katsaros C. Success rate of paramedian palatal implants in adolescent and adult orthodontic patients: A retrospective cohort study. *Eur J Orthod* 2014;36:22–25.
44. Wilmes B, Vasudavan S, Drescher D. Maxillary molar mesialization with the use of palatal mini-implants for direct anchorage in an adolescent patient. *Am J Orthod Dentofacial Orthop* 2019;155:725–732.
45. Wilmes B, Nienkemper M, Nanda R, Lübberink G, Drescher D. Palatally anchored maxillary molar mesialization using the mesialslider. *J Clin Orthod* 2013;47:172–179.
46. Willmann JH, Wilmes B, Drescher D. Digitale Mini-implantat getragene Suprakonstruktionen – Design und Workflows. *J Compr Dentof Orthod + Orthop (COO) Umf Dentof Orthod u Kieferorthop* 2019;3–4:16–20.
47. Wilmes B, Vasudavan S, Drescher D. CAD-CAM-fabricated mini-implant insertion guides for the delivery of a distalization appliance in a single appointment. *Am J Orthod Dentofacial Orthop* 2019;156:148–156.
48. Wilmes B, Drescher D. A miniscrew system with interchangeable abutments. *J Clin Orthod* 2008;42:574–580.
49. Willmann JH, Chhatwani S, Drescher D. Blender- Freeware als dentales CAD-Programm. *Kieferorthop* 2018;32:161–165.
50. Graf S, Cornelis MA, Hauber Gameiro G, Cattaneo PM. Computer-aided design and manufacture of hyrax devices: Can we really go digital? *Am J Orthod Dentofacial Orthop* 2017;152:870–874.
51. De Gabriele O, Dallatana G, Riva R, Vasudavan S. The easy driver for placement of palatal mini-implants and a maxillary expander in a single appointment. *J Clin Orthod* 2017;51:728–737.
52. Becker K, Wilmes B, Grandjean C, Vasudavan S, Drescher D. Skeletally anchored mesialization of molars using digitized casts and two surface-matching approaches: Analysis of treatment effects. *J Orofac Orthop* 2018;79:11–18.
53. Verna C. Regional acceleratory phenomenon. *Front Oral Biol* 2016;18:28–35.

54. Zawawi KH. Orthodontic treatment of a mandibular incisor extraction case with Invisalign. *Case Rep Dent* 2014;2014:657657.
55. Almeida NV, Silveira GS, Pereira DM, Mattos CT, Mucha JN. Interproximal wear versus incisors extraction to solve anterior lower crowding: A systematic review. *Dental Press J Orthod* 2015;20:66–73.
56. Ileri Z, Basciftci FA, Malkoc S, Ramoglu SI. Comparison of the outcomes of the lower incisor extraction, premolar extraction and non-extraction treatments. *Eur J Orthod* 2012;34:681–685.
57. Faerovig E, Zachrisson BU. Effects of mandibular incisor extraction on anterior occlusion in adults with Class III malocclusion and reduced overbite. *Am J Orthod Dentofacial Orthop* 1999;115:113–124.
58. Kokich VG, Shapiro PA. Lower incisor extraction in orthodontic treatment. Four clinical reports. *Angle Orthod* 1984;54:139–153.
59. Valinoti JR. Mandibular incisor extraction therapy. *Am J Orthod Dentofacial Orthop* 1994;105:107–116.
60. Bahreman AA. Lower incisor extraction in orthodontic treatment. *Am J Orthod* 1977;72:560–567.