
Mini-implant-borne Pendulum B appliance for maxillary molar distalisation: design and clinical procedure

Benedict Wilmes, Vandana Katyal and Dieter Drescher

Department of Orthodontics, University of Duesseldorf, Germany

A treatment objective of upper molar distalisation may often be required during the correction of a malocclusion. Distalisation is not only indicated for the management of Class II patients, but also for Class III surgery patients who require decompensation in the upper arch if upper incisor retrusion is needed. Unfortunately, most conventional intra-oral devices for non-compliance maxillary molar distalisation experience anchorage loss. A Pendulum type of appliance and a mini-implant-borne distalisation mechanism have been designed which can be inserted at chair-side, without a prior laboratory procedure and immediately after mini-implant placement. For re-activation purposes, a distal screw may be added to the Pendulum B appliance.

[Aust Orthod J 2014; 30: 230–239]

Received for publication: August 2014

Accepted: October 2014

Benedict Wilmes: wilmes@med.uni-duesseldorf.de; Vandana Katyal: vandykatyal@gmail.com; Dieter Drescher: d.drescher@uni-duesseldorf.de

Introduction

A treatment objective of upper molar distalisation may often be indicated for the correction of a dentoalveolar Class II malocclusion with an associated increased overjet and/or anterior crowding. Another less frequent indication may be the removal of dentoalveolar compensation in Class III patients who require orthognathic surgery. Due to aesthetic concerns and the duration of treatment, molar distalisation using headgear is unacceptable for many patients.^{1,2} This has resulted in a preference for purely intra-oral distalisation appliances which require minimal patient cooperation. Unfortunately, most conventional devices for non-compliance maxillary molar distalisation produce unwanted side effects, such as anchorage loss, especially when distalisation forces are applied buccally.³ One option to reduce the unwanted effects generated by reciprocal orthodontic forces is the use of palatal acrylic pads (Nance-buttons). However, the anchorage stability of this soft tissue-borne element is not always certain. Moreover, oral hygiene is impaired due to the partial coverage of the palatal tissues. If the anchorage unit includes

teeth, mesial migration and/or protrusion of the anterior dentition need to be considered as major disadvantages.^{4,5} The amount of anchorage loss of conventional intra-oral devices is reported to range from 24 to 55%.⁶

To minimise or eliminate anchorage loss related to the anterior teeth, skeletal anchorage has been integrated into distalisation appliances.⁷⁻¹⁶ In particular, mini-implants have attracted attention because of their versatility, minimal surgical invasiveness and low cost.¹⁷⁻²¹ Recently, various distalisation mechanisms for different insertion sites have been suggested.

The retromolar region has proved to be unsuitable for mini-implant placement due to unfavourable anatomy related to poor bone quality and thick soft tissue. The anterior palate has proved to be an ideal site for miniscrew placement for the distalisation of upper teeth. The good bone quality, the attached mucosa, and the minimal risk of injury to nearby teeth have been suggested as major advantages of miniscrew placement in this region.²² Furthermore, the mini-implants are unlikely to be in the path of tooth movement. This is critical, since premolars

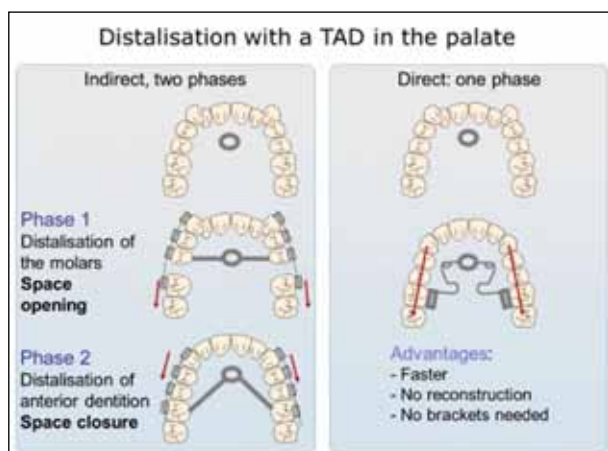


Figure 1. Different strategies for maxillary molar distalisation using TADs in the anterior palate. *Left:* Indirect anchorage with the need for a two-phase clinical procedure: Phase 1, distalisation of the molars; Phase 2, stabilisation of the molars and retraction of the anterior dental segment. *Right:* Direct anchorage with one-phase treatment.

move distally with the molars due to the pull of the interdental fibres. Hence, mini-implant insertion in the alveolar process is inappropriate for molar distalisation.

Skeletal anchorage mechanics can be divided into two groups (Figure 1):²¹

- Indirect anchorage: a temporary anchorage device (TAD) is coupled with a dental unit which immobilises one tooth or a group of teeth. An orthodontic force is then applied against this coupled unit and the teeth.
- Direct anchorage: a force is applied from a TAD directly to the teeth to be mobilised.

If the maxillary molars are to be distalised, *direct* anchorage is advantageous, since a major disadvantage of devices employing *indirect* anchorage is the need for a two-phase clinical procedure: (a) distalisation of the molars, and (b) stabilisation of the molars while retraction of the anterior dental segment occurs. A major adjustment of the appliance and the applied biomechanics is therefore necessary when starting the second phase of treatment.

A distalisation device which establishes *direct* anchorage from a mini-implant is advantageous for the following reasons:

- the treatment task can be completed in one phase and therefore avoids a refabrication of the appliance;
- a Nance button or similar supporting component is no longer needed, which enhances patient comfort and hygiene;

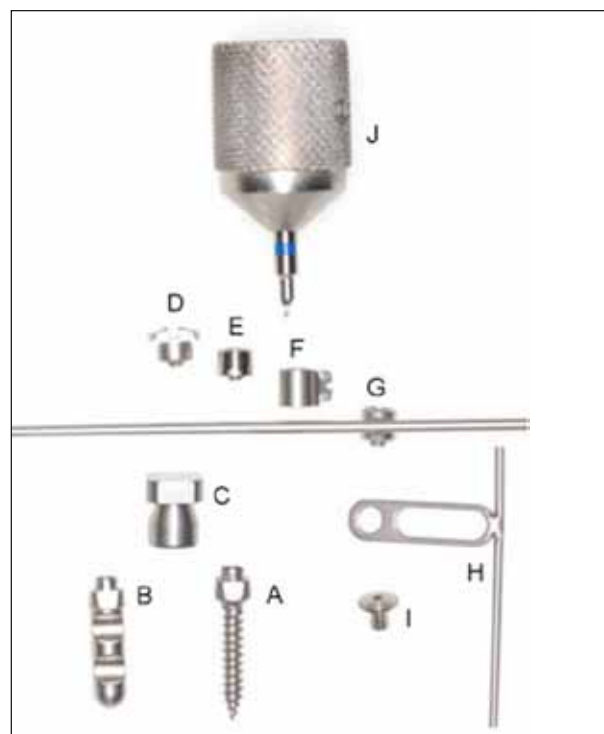


Figure 2. The Benefit system: (A) Miniscrew implant; (B) Laboratory analog; (C) Impression cap; (D) Slot abutment; (E) Standard abutment; (F) Bracket abutment; (G) Abutment with a wire in place (1.1 or 0.8 mm); (H) Beneplate with a wire in place (1.1 or 0.8 mm); (I) Fixing screw for the Beneplate; (J) Screwdriver for fixation of the abutments/Beneplates.

- as teeth are not included in the anchorage unit, anchorage loss is avoided; and
- there is no need for the bonding of brackets during the distalisation phase.

To benefit from the advantages of *direct* anchorage mechanics and use the anterior palate as the most suitable mini-implant insertion site, the Beneslider^{21,23-26} appliance has been designed to attach over mini-implants with exchangeable abutments. The Beneslider utilises sliding mechanics and has proved to be a reliable distalisation mechanism.²⁶

However, if frictionless mechanics are required and/or the molars are to be uprighted or derotated during distalisation, Pendulum mechanics may be employed and preferred.²⁷ There are reports of skeletally-supported Pendulum appliances which avoid anchorage loss.^{12,28-30} However, all described appliances require the need for additional laboratory work. The Pendulum B is designed to adapt to a skeletal-borne Pendulum device at chair-side, immediately after mini-implant placement and without a prior laboratory procedure.

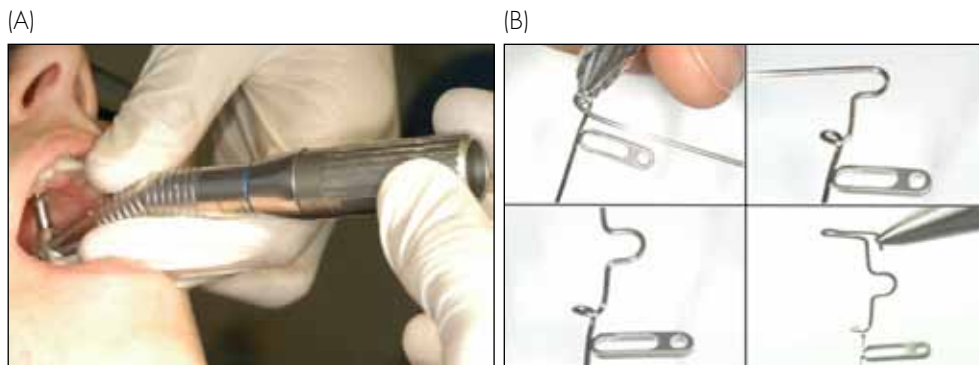


Figure 3. (A) A PSM handpiece is adapted to a commonly used contra angle (ratio 1:1) for pre-drilling and insertion of a mini-implant in the anterior palate; (B) Bending of the β -Titanium wire of the Pendulum.

Methods

After local or topical anaesthesia, pre-drilling of bone to a depth of 3 mm is recommended in adult patients. In young patients, pre-drilling is not required due to a lower bone density. Following bone preparation, two Benefit mini-implants (Figure 2A) are inserted into the palate. An anterior mini-implant (2x9 mm) is placed close to the third palatal rugae, a second mini-implant (2x7 or 2x9 mm) is inserted 7–14 mm posterior to the rugal implant. Pre-drilling and insertion can be done with a contra-angle handpiece (Figure 3A). Cooling is not needed either for pre-drilling or for insertion, due to the low handpiece speed. It is recommended that mini-implants with a wide diameter are used, because they provide greater stability.³¹⁻³⁴ To minimise the risk of mini-implant tipping or failure, the coupling of two mini-implants in the line of the force in the sagittal direction is advantageous. A Beneplate with a connected 0.8 mm β -Titanium wire (Figure 2H) is adapted to the curvature of the palate and connects the TADs with the molars. The active part of the Pendulum consists of a helix, a U-form bend, and a distal end which is inserted into a palatal molar sheath (Figure 3B). The Beneplate is secured with two fixing screws (Figure 2I). The Pendulum B can be bent at chair side (Case 1) or after an impression and subsequent manufacture on a cast in the laboratory (Case 2).

Kinzinger introduced the Pendulum K appliance, which incorporates a distal re-activation screw designed to avoid a potential crossbite as the molars distalise.³⁵ In concert with this design, the mini-implant-borne Pendulum B mechanism can be applied with an incorporated re-activation distal screw (Case 2).

Pendulum B, Case 1

As a clinical example, a 39-year-old male patient with a Class II malocclusion and upper and lower anterior crowding is presented (Figures 4 and 5). After the insertion of two Benefit mini-implants and the adaption and fixation of two molar bands with palatal sheaths, a Beneplate with an attached 0.8 mm wire was bent and adapted. To avoid molar tipping and rotation during distalisation, the Pendulum B appliance was pre-activated by the inclusion of uprighting and anti-rotation bends (Figures 6 and 7). After six months, a distalisation movement of approximately 5 mm was considered sufficient (Figures 8 and 9, Table I). The subsequent treatment steps included levelling and retraction of the anterior teeth by means of fixed appliances and power chain (Figure 10). The panoramic radiograph taken after the retraction of the anterior teeth indicated impressive bodily distalisation of the molars (Figure 11). The total treatment time was 14 months (six months distalisation and eight months levelling and retraction of the anterior teeth) (Figure 12). After fixed appliance removal, bonded retainers were placed and the mini-implants were removed without anaesthesia. A review after two years showed a stable treatment result (Figure 13). No complications or untoward sequelae were reported during treatment and thereafter.

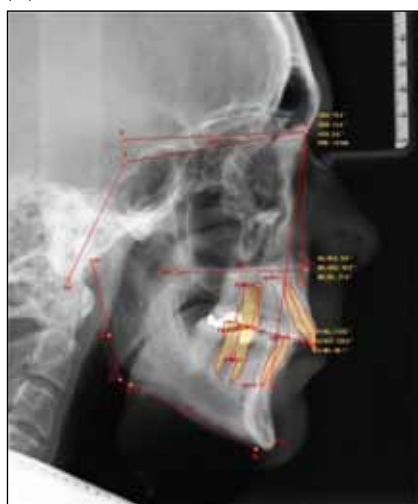
Pendulum B with an additional distal screw for re-activation, Case 2

As a second clinical example, an 18-year-old male patient with a severe skeletal Class III malocclusion with dentoalveolar compensation is presented (Figures 14–16). The treatment plan involved dentoalveolar decompensation involving upper incisor retrusion

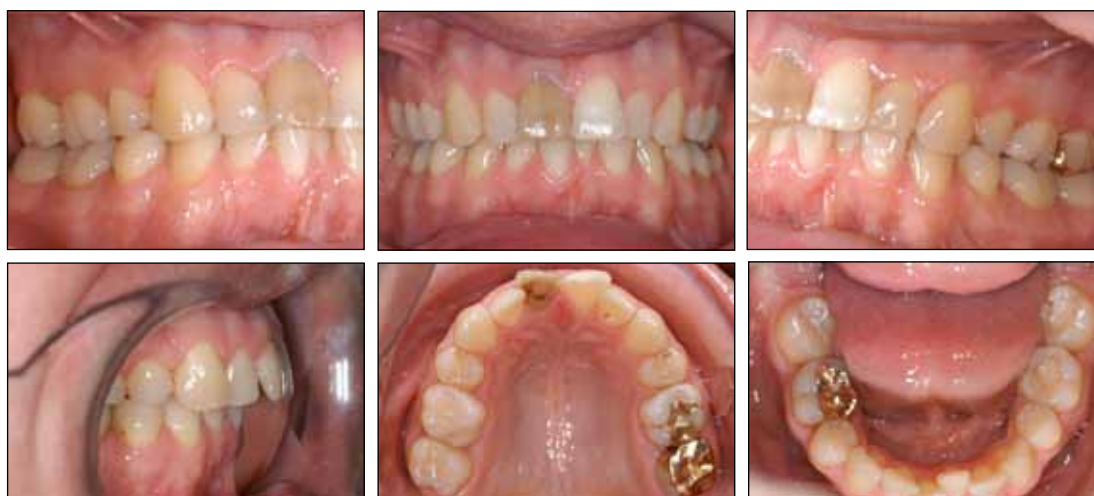

Figure 4. A 39-year-old male patient with a Class II malocclusion and upper and lower anterior crowding.

(A)



(B)

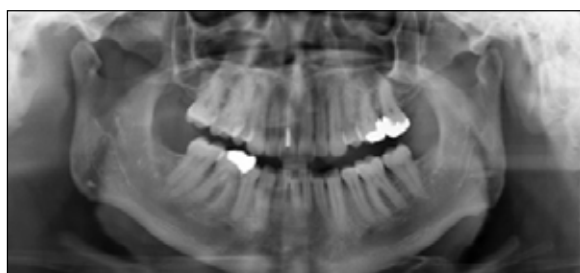

Figure 5. (A) The initial lateral cephalometric radiograph shows a large overjet and a dentoalveolar Class II relationship; the WITS appraisal is 1.6 mm; (B) Initial panoramic radiograph: Four premolars had been extracted when the patient was younger.

and lower incisor protrusion, followed by surgical correction of the underlying Class III malocclusion. The decompensation of the upper arch could be achieved by extraction or molar distalisation. Due to a missing upper left third molar and a hypoplastic and

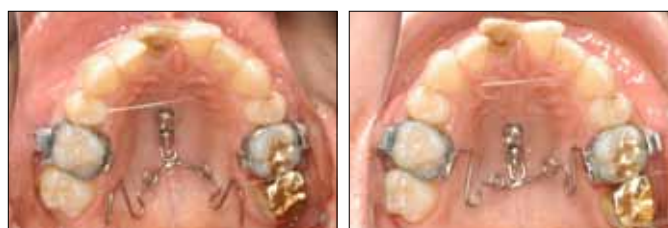

Figure 6. The Pendulum B appliance fixed on two mini-implants. To avoid tipping and severe rotations during distalisation, the Pendulum mechanics was pre-activated by uprighting and anti-rotation bends.

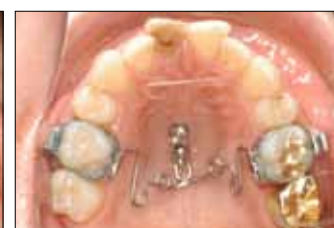

Figure 7. Active parts of the Pendulum inserted into the sheaths.

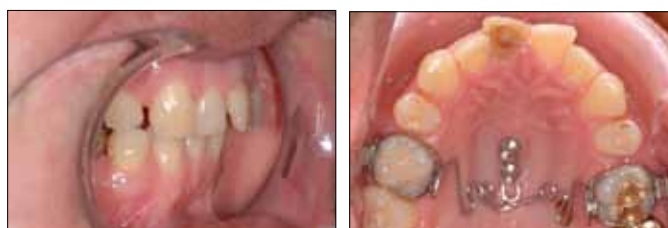

Figure 8. Distalisation effect after six months with the Pendulum B appliance. Due to interdental fibres, spaces are opening in the posterior as well as in the anterior region.

impacted upper right third molar, distalisation was the preferred option.

After the insertion of two Benefit mini-implants and the adaption of two upper molar bands with palatal sheaths, an impression was taken in order to construct the Pendulum B appliance on a plaster model. This required the use of impression caps and laboratory analogs (Figures 2C and 2B). A Beneplate was adapted relative to the mini-implant positions and connected to a distal screw (Dentaurum, Ispringen, Germany). Subsequently, two 0.8 mm β -Titanium springs were bent and connected with composite resin to the distal

screw (Figure 17). To avoid molar tipping and rotation during distalisation, the Pendulum B appliance was pre-activated by uprighting and anti-rotation bends (Figures 17 and 18). Once inserted, the distal screw was re-activated every six weeks, which involved four 0.6 mm quarter turns. The upper right third molar was extracted and after 10 months the molar distalisation was considered sufficient (Figure 19, approximately 4 mm) and brackets were bonded to the remaining teeth (Figure 20). The finishing steps included

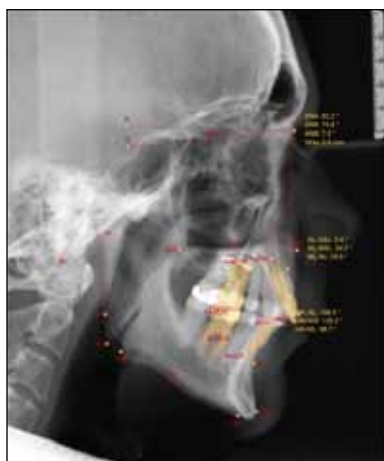

Figure 9. Cephalometric radiograph showing the distalisation effect (approximately 5 mm) after six months of treatment. Note that the posterior TAD did not penetrate the nasal cavity, since the median part of the maxilla extends more cranially than the lateral nasal floor.

levelling and retraction of the anterior teeth by means of loop mechanics. The Pendulum appliance was left in place to serve as a molar anchorage device while anterior retraction was taking place. A post-treatment panoramic radiograph indicated considerable bodily distalisation of the first molars (Figure 21). After anterior tooth retraction, adequate negative overjet was created (Figure 22) and the Pendulum appliance was removed prior to orthognathic surgery (Figure 23), which involved maxillary advancement and a mandibular set back (Figures 24 and 25). After finishing and debanding, fixed retainers were bonded and the mini-implants were removed (Table II). The post-treatment review, two years later, showed a stable treatment result (Figures 26 and 27). No complications or unfavourable sequelae were reported during the treatment and post-treatment phases.

Results and discussion

In the presented cases, the upper molars were distalised successfully into desired positions. The Pendulum B proved to be an effective and manageable upper molar distalisation mechanism. Compared with conventional Pendulum devices, no anchorage loss related to mesial migration of the anterior teeth occurred.

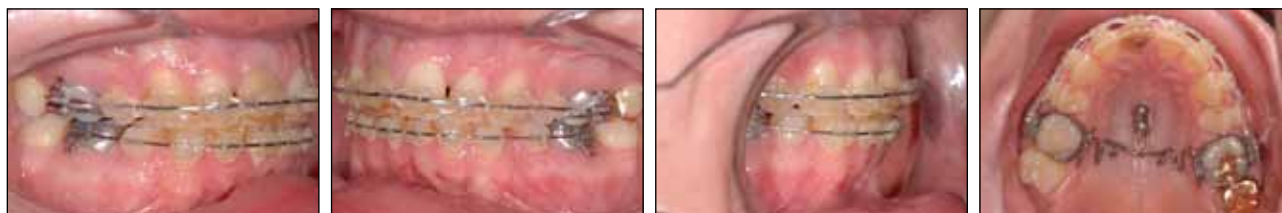

Figure 10. After levelling and aligning, the anterior dentition was retracted by a power chain. During this retraction phase the Pendulum B appliance was reactivated for molar anchorage purposes.

Table I. Lateral cephalometric variables changes of Case 1 before and after distalisation.

| Lateral cephalometric variables | Pretreatment value (1) | Post-distalisation value (2) | Change (2-1) |
|---------------------------------|------------------------|------------------------------|--------------|
| SNA (°) | 81.5 | 82.2 | + 0.7 |
| SNB (°) | 74.0 | 74.9 | + 0.9 |
| ANB (°) | 7.5 | 7.3 | - 0.2 |
| WITS (mm) | 5.1 | 5.5 | + 0.4 |
| NL-ML (°) | 34.4 | 34.2 | - 0.2 |
| UI-NL (°) | 117.1 | 109.5 | -7.6 |
| LI-MP (°) | 90.1 | 90.0 | - 0.1 |
| UI-LI (°) | 125.6 | 125.2 | - 0.4 |

SNA, Angle Sella-Nasion-A point; SNB, Sella-Nasion-B point; ANB, Difference SNB-SNA; NL-ML, Palatal plane to Mandibular plane; UI-NL, Upper incisor long axis to Palatal plane; LI-MP, Lower incisor long axis to Mandibular plane; UI-LI, Upper incisor long axis to lower incisor long axis

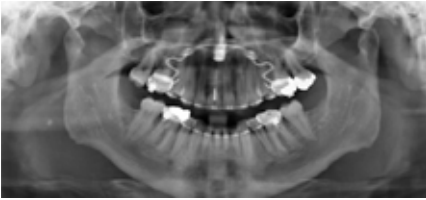


Figure 11. Panoramic radiograph after retraction of the anterior dentition showing bodily distalisation of the upper molars.

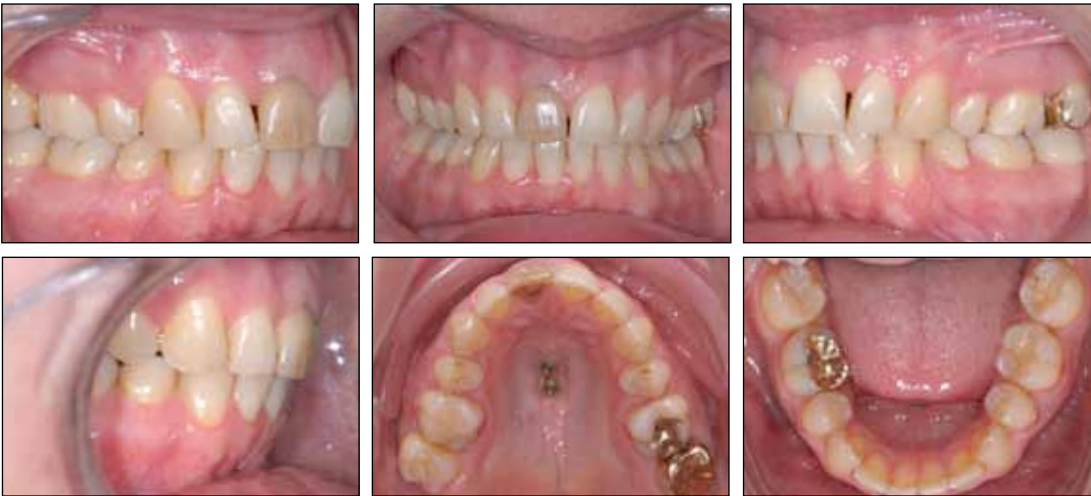

Figure 12. Intra-oral situation after debonding.

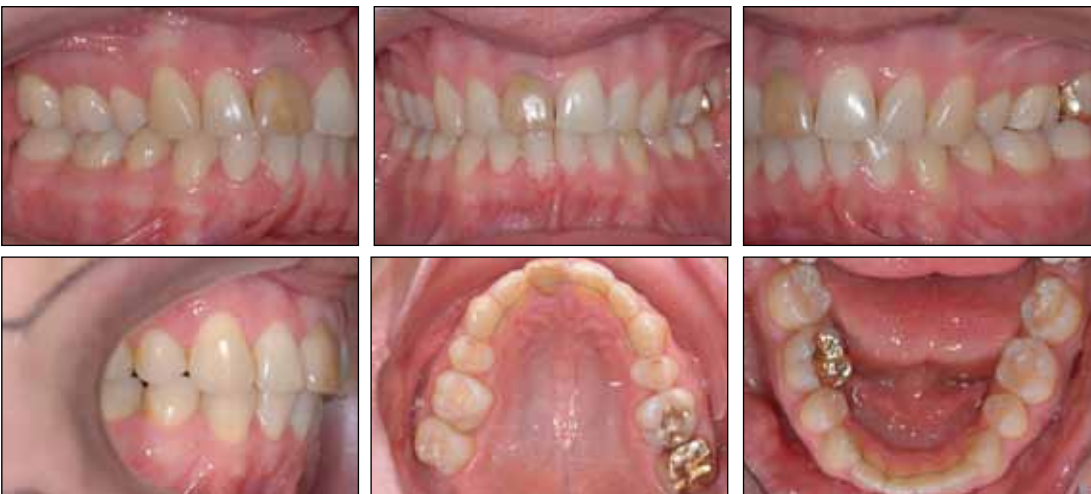

Figure 13. Follow-up photographs two years post-retention.

Direct anchorage mechanics did not require attachments to be bonded during the distalisation phase. Consequently, there was a reduced risk of tooth demineralisation, and treatment was not visible and therefore more aesthetic during the first stage. This was preferred and well accepted by the patients.

The Pendulum B appliance is capable of being bent and adapted intra-orally. However, if an additional Kinzinger distalisation screw is added, an impression

and the adaptation of the appliance on a plaster model is recommended.

The anterior palate is a suitable and recommended insertion site for miniscrews. There is negligible risk of root injury, and mini-implant failure rate has been reported to be very low.²²

If bodily distal movement of the upper molars is desired, the use of sliding mechanics (Beneslider) should also be considered, due to its ease of activation.

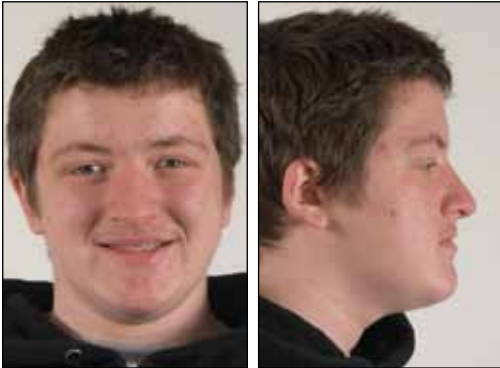

Figure 14. 18-year-old male patient with a severe skeletal Class III malocclusion and dentoalveolar compensations.

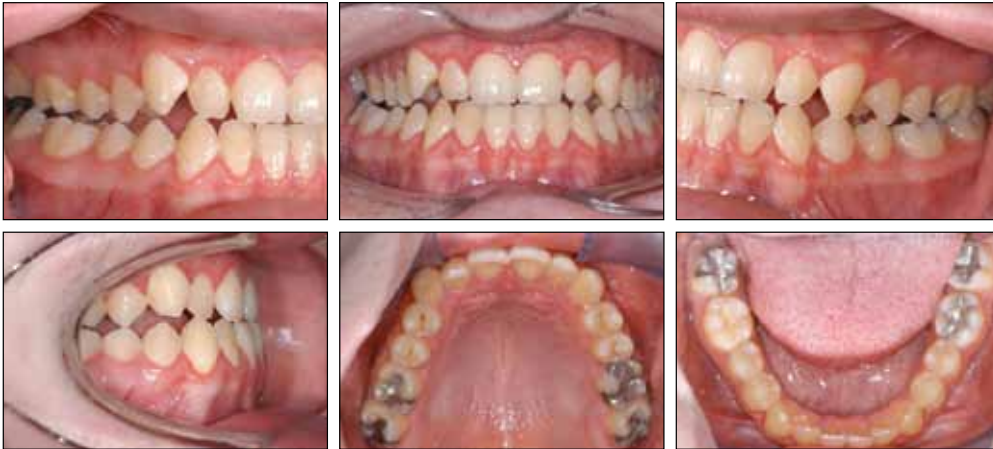

Figure 15. 18-year-old male patient with a severe skeletal Class III malocclusion and dentoalveolar compensations.

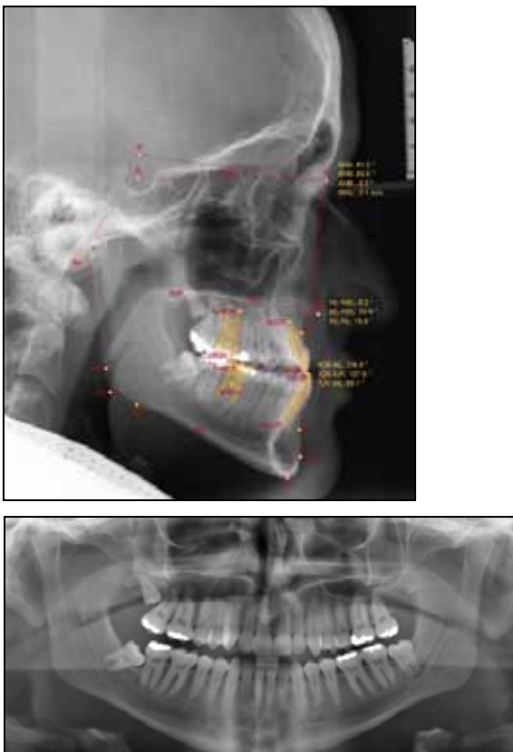


Figure 16. 18-year-old male patient with a severe skeletal Class III malocclusion and dentoalveolar compensations.

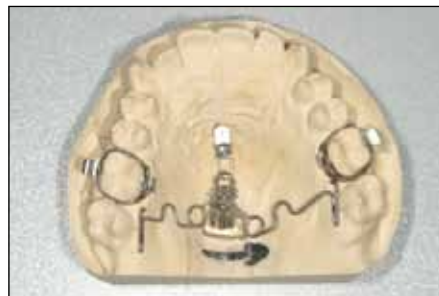

Figure 17. Pendulum B with a distal screw on a plaster model: A Beneplate was adapted according to the mini-implant positions and connected to a distal screw. Two 0.8 mm β -Titanium springs were bent and connected by resin to the distal screw.

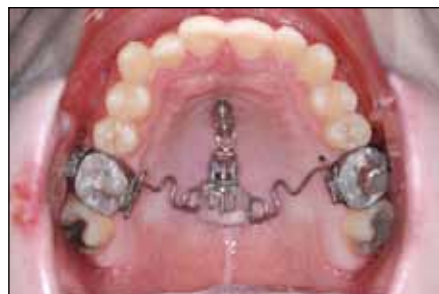

Figure 18. Pendulum B mechanics inserted with pre-activations for uprighting and anti-rotation.

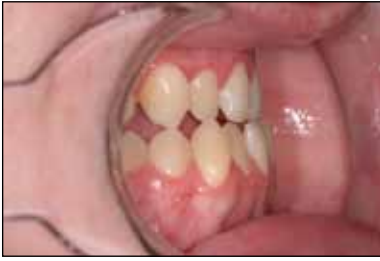

Figure 19. Situation after 10 months of distalisation.

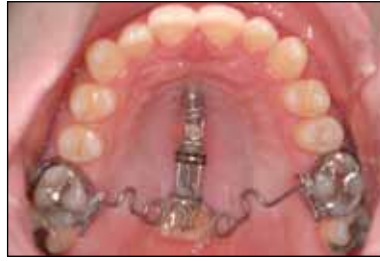

Figure 20. Levelling phase after distalisation.

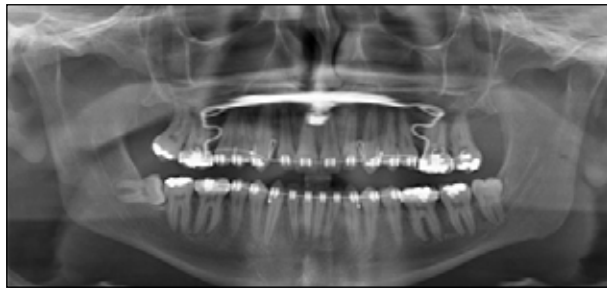
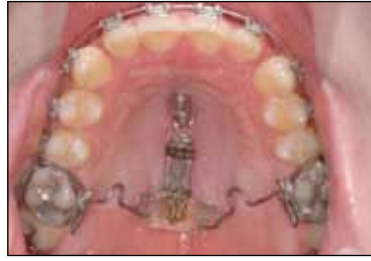

Figure 21. Panoramic radiograph showing good bodily distalisation of the upper first molars.

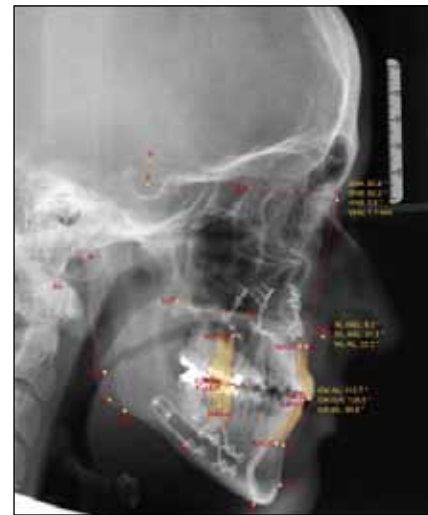


Figure 24. Lateral cephalogram after orthognathic surgery (mandibular set back and maxillary advancement).

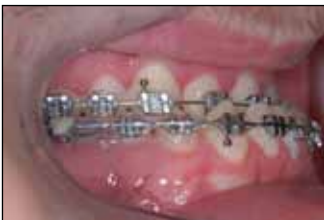

Figure 22. Sufficient negative overjet after retraction.

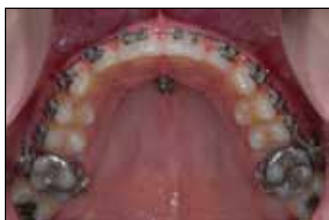
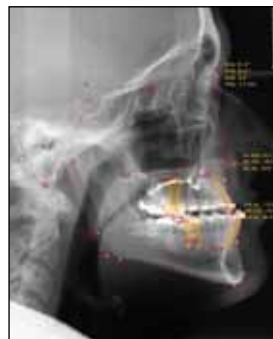
Figure 23. Situation before orthognathic surgery.

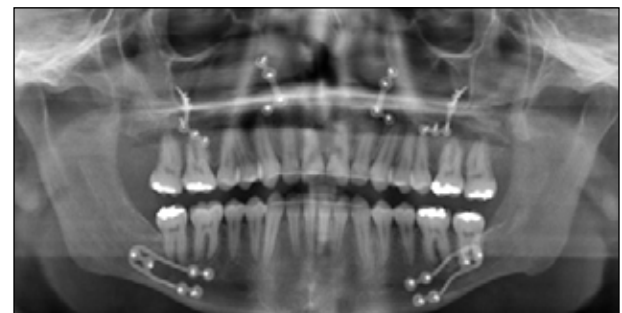
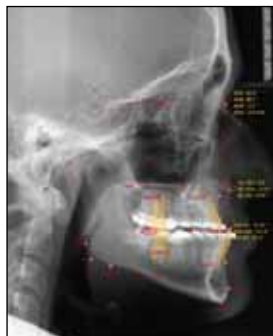

Figure 25. Panoramic radiograph after orthognathic surgery.

By contrast, if upper molars are to be distalised and simultaneously uprighted and/or derotated, the Pendulum B is the preferred appliance.

The distalisation of upper molars is not only indicated for Class II patients, but also for Class III surgery patients in whom decompensation in the upper arch involving upper incisor retraction is needed. As an alternative to distalisation, decompensation can be

achieved by the extraction of premolars. However, there may also be an increased requirement for molar anchorage when the anterior teeth are retracted.³⁶

Conclusion

The results of molar distalisation were stable in the presented cases two years following treatment. However, prospective clinical studies which examine larger sample sizes and longer review periods are required to further evaluate the efficacy and efficiency of the Pendulum B appliance in comparison with conventional mechanics.



Figure 26. Extra-oral situation after the treatment.

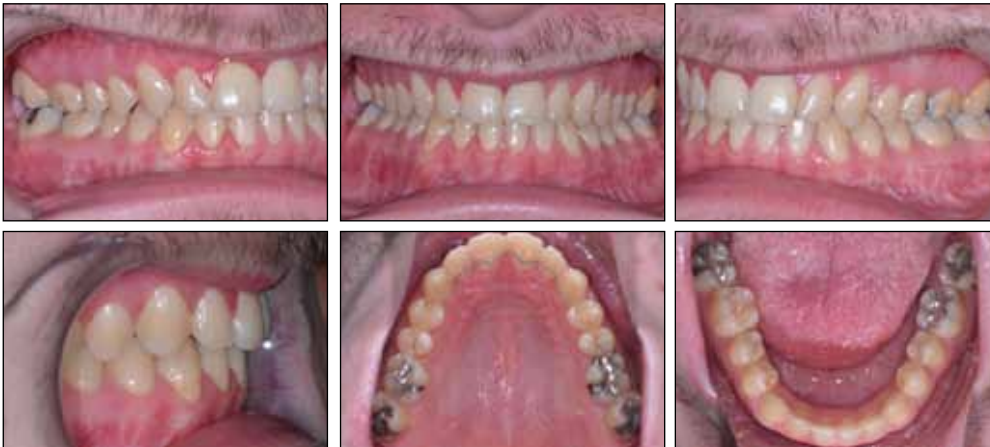

Figure 27. Intra-oral situation two years post-retention.

Table II. Lateral cephalometric variables changes of Case 2 before and after distalisation.

| Lateral cephalometric variables | Pretreatment value (1) | Post-treatment value (2) | Change (2-1) |
|---------------------------------|------------------------|--------------------------|--------------|
| SNA (°) | 81.5 | 82.8 | + 1.3 |
| SNB (°) | 84.6 | 82.3 | - 3.3 |
| ANB (°) | -3.2 | 0.5 | + 3.7 |
| WITS (mm) | -7.1 | 1.1 | + 8.2 |
| NL-ML (°) | 19.6 | 22.2 | + 2.6 |
| UI-NL (°) | 116.5 | 112.7 | -3.8 |
| LI-MP (°) | 86.0 | 85.6 | - 0.4 |
| UI-LI (°) | 137.9 | 139.5 | + 1.6 |

SNA, Angle Sella-Nasion-A point; SNB, Sella-Nasion-B point; ANB, Difference SNB-SNA; NL-ML, Palatal plane to Mandibular plane; UI-NL, Upper incisor long axis to Palatal plane; LI-MP, Lower incisor long axis to Mandibular plane; UI-LI, Upper incisor long axis to Lower incisor long axis

Corresponding author

Professor Benedict Wilmes
 Department of Orthodontics
 University of Duesseldorf
 Moorenstr. 5
 40225 Duesseldorf
 Germany
 Email: wilmes@med.uni-duesseldorf.de

References

1. Clemmer EJ, Hayes EW. Patient cooperation in wearing orthodontic headgear. *Am J Orthod* 1979;75:517-24.
2. Egolf RJ, BeGole EA, Upshaw HS. Factors associated with orthodontic patient compliance with intraoral elastic and headgear wear. *Am J Orthod Dentofacial Orthop* 1990;97:336-48.
3. Antonarakis GS, Kiliaridis S. Maxillary molar distalization with noncompliance intramaxillary appliances in Class II malocclusion. A systematic review. *Angle Orthod* 2008;78:1133-40.
4. Bussick TJ, McNamara JA Jr. Dentoalveolar and skeletal changes associated with the pendulum appliance. *Am J Orthod Dentofacial*

- Orthop 2000;117:333-43.
5. Ghosh J, Nanda RS. Evaluation of an intraoral maxillary molar distalization technique. *Am J Orthod Dentofacial Orthop* 1996;110:639-46.
 6. Fortini A, Lupoli M, Giuntoli F, Franchi L. Dentoskeletal effects induced by rapid molar distalization with the first class appliance. *Am J Orthod Dentofacial Orthop* 2004;125:697-704; discussion 704-5.
 7. Byloff FK, Kärcher H, Clar E, Stoff F. An implant to eliminate anchorage loss during molar distalization: a case report involving the Graz implant-supported pendulum. *Int J Adult Orthodon Orthognath Surg* 2000;15:129-37.
 8. Gelgör IE, Büyükyılmaz T, Karaman AI, Dolanmaz D, Kalayci A. Intraosseous screw-supported upper molar distalization. *Angle Orthod* 2004;74:838-50.
 9. Karaman AI, Basciftci FA, Polat O. Unilateral distal molar movement with an implant-supported distal jet appliance. *Angle Orthod* 2002;72:167-74.
 10. Kyung SH, Hong SG, Park YC. Distalization of maxillary molars with a midpalatal miniscrew. *J Clin Orthod* 2003;37:22-6.
 11. Sugawara J, Kanzaki R, Takahashi I, Nagasaka H, Nanda R. Distal movement of maxillary molars in nongrowing patients with the skeletal anchorage system. *Am J Orthod Dentofacial Orthop* 2006;129:723-33.
 12. Kircelli BH, Pektaş ZO, Kircelli C. Maxillary molar distalization with a bone-anchored pendulum appliance. *Angle Orthod* 2006;76:650-9.
 13. Escobar SA, Tellez PA, Moncada CA, Villegas CA, Latorre CM, Oberti G. Distalization of maxillary molars with the bone-supported pendulum: a clinical study. *Am J Orthod Dentofacial Orthop* 2007;131:545-9.
 14. Kinzinger G, Gülnden N, Yildizhan F, Hermanns-Sachweh B, Diedrich P. Anchorage efficacy of palatally-inserted miniscrews in molar distalization with a periodontally/miniscrew-anchored distal jet. *J Orofac Orthop* 2008;69:110-20.
 15. Velo S, Rotunno E, Cozzani M. The Implant Distal Jet. *J Clin Orthod* 2007;41:88-93.
 16. Kinzinger GS, Diedrich PR, Bowman SJ. Upper molar distalization with a miniscrew-supported Distal Jet. *J Clin Orthod* 2006;40:672-8.
 17. Costa A, Raffaini M, Melsen B. Miniscrews as orthodontic anchorage: a preliminary report. *Int J Adult Orthodon Orthognath Surg* 1998;13:201-9.
 18. Freudenthaler JW, Haas R, Bantleon HP. Bicortical titanium screws for critical orthodontic anchorage in the mandible: a preliminary report on clinical applications. *Clin Oral Implants Res* 2001;12:358-63.
 19. Kanomi R. Mini-implant for orthodontic anchorage. *J Clin Orthod* 1997;31:763-7.
 20. Melsen B, Costa A. Immediate loading of implants used for orthodontic anchorage. *Clin Orthod Res* 2000;3:23-8.
 21. Wilmes B. Fields of application of mini-implants. In: Ludwig B, Baumgaertel S, Bowman J, eds. *Mini-implants in orthodontics: innovative anchorage concepts*. London: Quintessence, 2008;91-122.
 22. Karagiolidou A, Ludwig B, Pazera P, Gkantidis N, Pandis N, Katsaros C. Survival of palatal miniscrews used for orthodontic appliance anchorage: a retrospective cohort study. *Am J Orthod Dentofacial Orthop* 2013;143:767-72.
 23. Wilmes B, Drescher D. Application and effectiveness of the Beneslider: a device to move molars distally. *World J Orthod* 2010;11:331-40.
 24. Wilmes B, Drescher D, Nienkemper M. A miniplate system for improved stability of skeletal anchorage. *J Clin Orthod* 2009;43:494-501.
 25. Wilmes B, Drescher D. A miniscrew system with interchangeable abutments. *J Clin Orthod* 2008;42:574-80; quiz 595.
 26. Nienkemper M, Wilmes B, Pauls A, Yamaguchi S, Ludwig B, Drescher D. Treatment efficiency of mini-implant-borne distalization depending on age and second-molar eruption. *J Orofac Orthop* 2014;75:118-32.
 27. Hilgers JJ. The pendulum appliance for Class II non-compliance therapy. *J Clin Orthod* 1992;26:706-14.
 28. Kärcher H, Byloff FK, Clar E. The Graz implant supported pendulum, a technical note. *J Craniomaxillofac Surg* 2002;30:87-90.
 29. Kinzinger G, Wehrbein H, Byloff FK, Yildizhan F, Diedrich P. Innovative anchorage alternatives for molar distalization - an overview. *J Orofac Orthop* 2005;66:397-413.
 30. Oncağ G, Akyalçın S, Arikan F. The effectiveness of a single osteointegrated implant combined with pendulum springs for molar distalization. *Am J Orthod Dentofacial Orthop* 2007;131:277-84.
 31. Wilmes B, Rademacher C, Olthoff G, Drescher D. Parameters affecting primary stability of orthodontic mini-implants. *J Orofac Orthop* 2006;67:162-74.
 32. Wilmes B, Ottenstreuer S, Su YY, Drescher D. Impact of implant design on primary stability of orthodontic mini-implants. *J Orofac Orthop* 2008;69:42-50.
 33. Wilmes B, Su YY, Sadigh L, Drescher D. Pre-drilling force and insertion torques during orthodontic mini-implant insertion in relation to root contact. *J Orofac Orthop* 2008;69:51-8.
 34. Wilmes B, Su YY, Drescher D. Insertion angle impact on primary stability of orthodontic mini-implants. *Angle Orthod* 2008;78:1065-70.
 35. Kinzinger GS, Diedrich PR. Biomechanics of a modified Pendulum appliance -theoretical considerations and in vitro analysis of the force systems. *Eur J Orthod* 2007;29:1-7.
 36. Wilmes B, Olthoff G, Drescher D. Comparison of skeletal and conventional anchorage methods in conjunction with pre-operative decompensation of a skeletal class III malocclusion. *J Orofac Orthop* 2009;70:297-305.