

Non-Compliance Space Closure in Patients with Missing Maxillary Lateral Incisors

BJÖRN LUDWIG, DMD, MSD
BJORN U. ZACHRISSON, DDS, MSD, PHD
MARCO ROSA, MD, DDS, DO

Mesial space closure is an attractive method for resolving malocclusions associated with agenesis of the maxillary lateral incisors, since it requires no prosthetic implants.¹ Key factors for success are anchorage control and detailed finishing, including interdisciplinary cooperation with esthetic dentistry.¹⁻⁴ Protraction of the entire maxillary arch may be difficult to achieve with conventional techniques, due to the anchorage demands of moving the posterior dentition forward. In addition, it is time-consuming to execute routine tooth-by-tooth mesial movement using push-and-pull mechanics, and Class III elastics are generally needed during a portion of treatment.⁵

These problems can now be solved by taking advantage of the quality and quantity of palatal bone for skeletal anchorage. A miniplate secured to the palatal bone by two in-line miniscrews allows the use of a variety of attachments for maxillary protraction,⁶⁻⁸ without the high failure rates associated with the more common interradicular miniscrew placement sites.⁹

Wilmes and colleagues⁶⁻⁸ and Baumgaertel and colleagues^{10,11} have described the miniscrew-supported T-wire, which is bonded to the central incisors for indirect anchorage and thus avoids lingual tipping of these teeth during space closure. The T-wire maintains the incisor positions while minor space closure is performed by means of step-by-step, segmented mesial tooth movement from posterior to anterior. For closure of wider spaces and even incisor protraction—due to the “reverse anchorage loss phenomenon”—the miniscrew-supported Mesialslider has been proposed by Wilmes and Drescher⁷ and Wilmes and colleagues.⁸ This non-compliance system utilizes a prefabricated, fixed U-shaped wire welded to a

miniplate splinting the two palatally inserted miniscrews, providing stationary skeletal anchorage for various forms of protraction mechanics. A somewhat similar system using slightly different biomechanics was later shown by Kim and colleagues.¹²

This article introduces the T-Mesialslider, which combines the elements and properties of the T-wire and the Mesialslider for treatment of patients with missing maxillary lateral incisors.

Appliance Design

The T-Mesialslider provides posterior and anterior anchorage for protraction of posterior teeth with heavy forces while allowing adjustments of anterior tooth positions. The base of the T-Mesialslider is a prefabricated abutment plate with two laser-welded stainless steel wires (Fig.

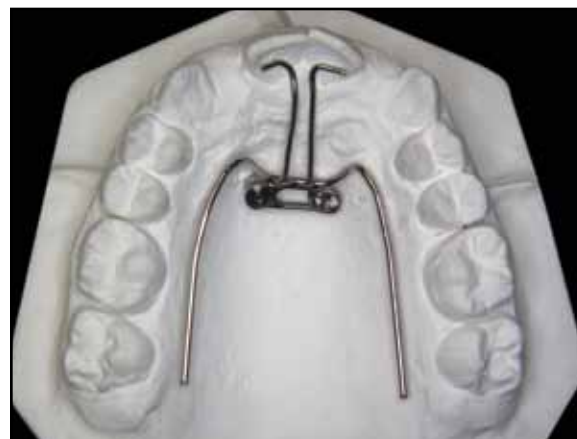

Fig. 1 Prefabricated T-Mesialslider: U-shaped stainless steel framework and anterior T-wire with two arms, laser-welded to miniplate abutment anchored by two palatal miniscrews.

Dr. Ludwig is a Contributing Editor of the *Journal of Clinical Orthodontics*; an Instructor, Department of Orthodontics, University of Homburg, Saar, Germany; and in the private practice of orthodontics at Am Bahnhof 54, 56841 Traben-Trarbach, Germany; e-mail: bludwig@kieferorthopaedie-mosel.de. Dr. Zachrisson is an Associate Editor of the *Journal of Clinical Orthodontics* and a Professor Emeritus, Department of Orthodontics, University of Oslo, Norway. Dr. Rosa is a Professor of Orthodontics, Insubria University, Varese, Italy, and in the private practice of orthodontics in Trento, Italy.



Dr. Ludwig



Dr. Zachrisson



Dr. Rosa

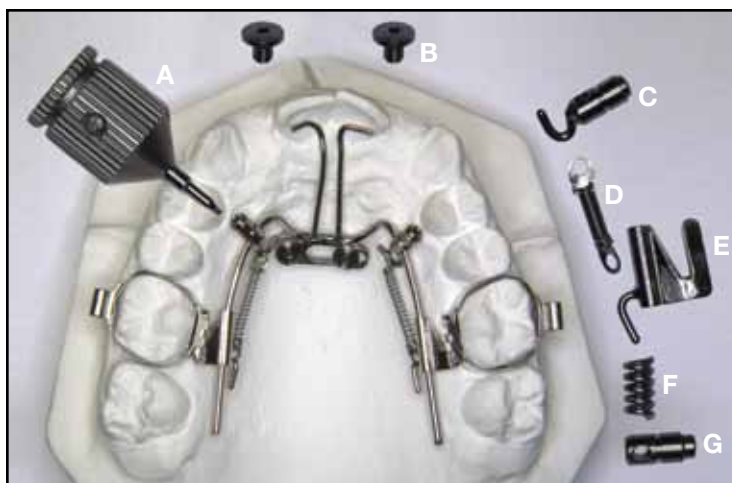


Fig. 2 T-Mesialslider components.* A. Universal screwdriver for abutment fixation. B. Abutment screws. C. Adjustable sliding lock with hook. D. Superelastic closed-coil spring with eyelets. E. Sliding tube with hook. F. Compressed push-coil spring. G. Adjustable sliding lock without hook.

1). This plate, which can be fitted either in the mouth or on a plaster cast, is affixed by two tiny screws (Fig. 2B) to the palatally inserted mini-screws. The free end of the .032" anterior wire (or wires, as shown here) is adapted to contact (or to be bonded to) the lingual surfaces of the central incisors; the .045" posterior wire is formed in a U-shape, almost parallel to the posterior teeth and to the occlusal plane.

After adaptation of the basic framework, the appliance is customized for each patient using the following components (Fig. 2):

- A universal key (screwdriver) for all screw parts (Fig. 2A).
- Adjustable sliding locks with hooks for coil-spring or elastic traction (Fig. 2C).
- Sliding tubes for insertion in standard lingual sheaths on the first molars (Fig. 2E).
- Superelastic closed-coil springs for placement between the anterior sliding lock and the sliding

molar tube (Fig. 2D); alternatively, elastic chains can be used.

- Compressed push-coil springs placed distal to the sliding molar tube (Fig. 2F) and anchored by a sliding lock without a hook (Fig. 2G).

The T-Mesialslider is now available as a universal prefabricated appliance* that can be adapted at the chair or on a plaster cast (we recommend the use of a plaster cast for easier and more precise adaptation). The prefabricated appliance has two T-wire arms to make it more versatile.

Appliance Activation

The U-shaped wire can be activated to guide the first molars for expansion/compression, intrusion/extrusion, or both. Simultaneous push (Fig.

*PSM Medical Solutions, Tuttlingen, Germany; www.psm.ms. Distributed in the United States by PSM-Mondeal North America, Inc., Indio, CA; www.mondeal-ortho.com.

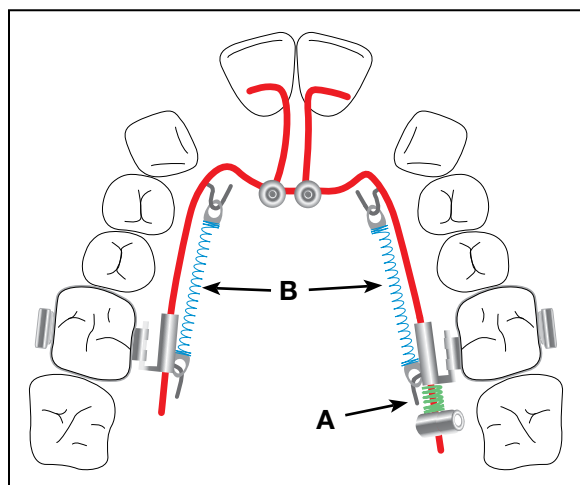


Fig. 3 Push (A) and pull forces (B) applied to molars.

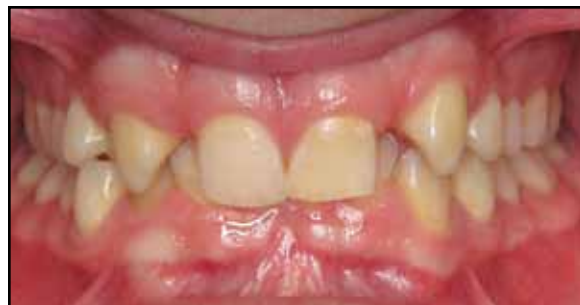

Fig. 4 Case 1. Adult male patient with agenesis of maxillary lateral incisors, deep bite, and retroclined incisors before treatment.

3A) and pull forces (Fig. 3B) can be applied from the sliding molar tubes to adjustable sliding locks or soldered hooks on the palatal wire, or to brackets or lingual cleats on individual teeth. Elastomeric chains can be placed between the central incisors and canines to close the lateral incisor spaces.

The force expressed by the nickel titanium closed-coil springs between the anterior locks and the sliding molar tubes should be at least 250g. Additional elastics or compressed-coil springs can be placed labially or lingually between the molars and premolars as desired, since the anchorage is stationary.

The versatility of the T-Mesialslider is illustrated here in three patients.

Case 1

An adult male presented with bilateral agenesis of the maxillary lateral incisors and a deep overbite in a Class II, division 2 malocclusion with retroclined central incisors (Fig. 4). The treatment objective was to move the entire maxillary dentition mesially to close all spaces and simultaneously correct the deep bite by upper-incisor torque correction and lower-incisor intrusion. Treatment

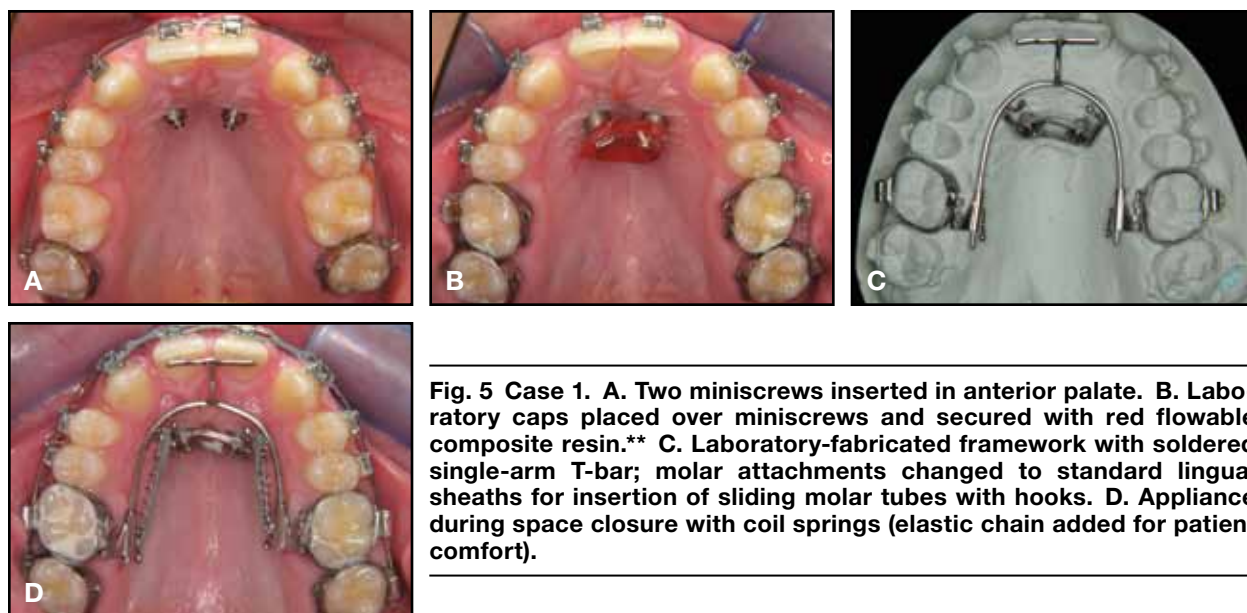


Fig. 5 Case 1. A. Two miniscrews inserted in anterior palate. B. Laboratory caps placed over miniscrews and secured with red flowable composite resin.** C. Laboratory-fabricated framework with soldered single-arm T-bar; molar attachments changed to standard lingual sheaths for insertion of sliding molar tubes with hooks. D. Appliance during space closure with coil springs (elastic chain added for patient comfort).

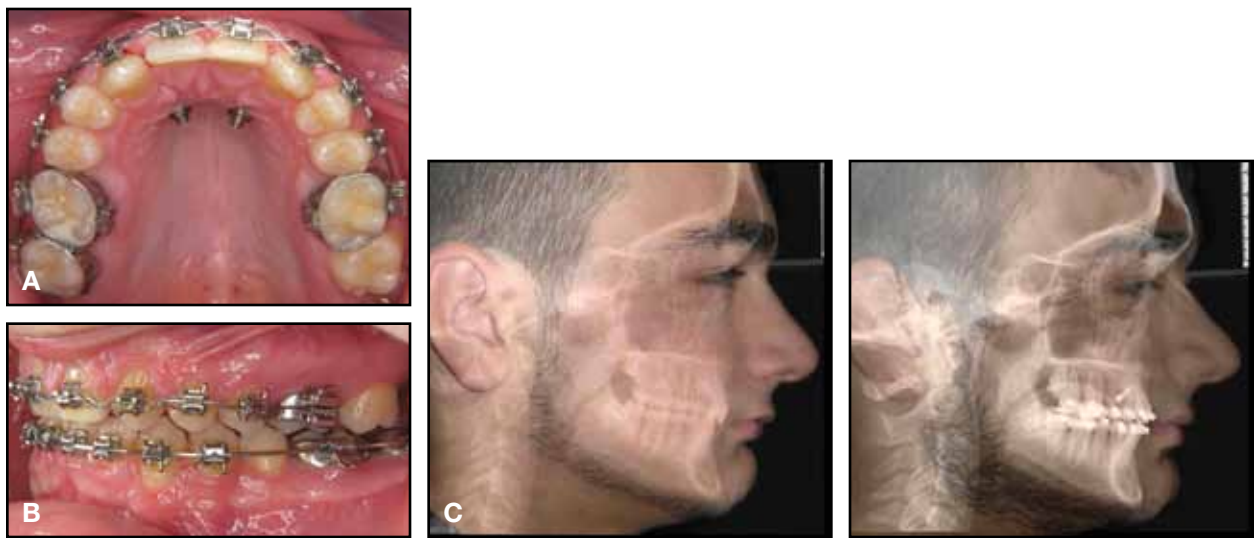


Fig. 6 Case 1. A. After nine months of space closure, palatal appliance removed and case finished with labial appliances. **B.** Archwire bends made for marginal gingival leveling (extrusion bend for canine and intrusion bend for first premolar). **C.** Pretreatment and post-space-closure cephalograms superimposed on facial profiles.

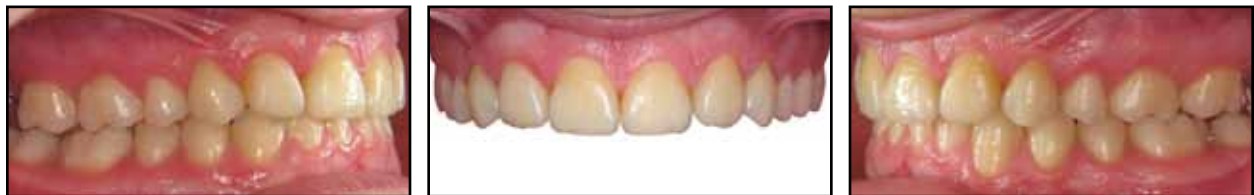

Fig. 7 Case 1. Patient two years after completion of treatment and placement of six porcelain veneers; note natural gingival contours.

was divided into a first stage of space closure and anchorage control, using the T-Mesialslider, and a second stage for finishing and esthetic detailing after removal of the palatal appliance.

After insertion of two 2mm × 9mm palatal miniscrews (Fig. 5A), laboratory caps were placed over the screwheads and secured with red flowable composite resin** (Fig. 5B). Before the impression was poured, two analog miniscrews were inserted into the laboratory caps. The T-Mesialslider was fabricated with a soldered single-arm T-bar, and two hooks were soldered to the U-shaped wire (Fig. 5C). The first-molar bands were provided with lingual sheaths to accommodate the sliding molar tubes.

Mesial molar activation was performed with superelastic coil springs at a force level of about 250g; light palatal power chains were placed alongside the springs to improve tongue comfort (Fig. 5D). Elastic traction with a force of about 100g was used between the canines and central incisors.

The spaces were closed after nine months, at which point the T-Mesialslider was removed and finishing was begun (Fig. 6A). High-torque brack-

ets (+22°) were used on the canines to improve palatal root torque; the premolars were uprighted using untorqued standard edgewise brackets. Natural “high-low-high” gingival leveling was achieved with step-bends—step-downs for the canines and step-ups for the first premolars (Fig. 6B). After cuspal grinding of the extruded canines, six porcelain laminate veneers were bonded for esthetic finishing (Fig. 7). Superimposition of the pretreatment and post-space-closure lateral cephalograms demonstrated improved incisor positions and inclinations (Fig. 6C).

Case 2

A 15-year-old female presented with bilateral agenesis of the maxillary lateral incisors and unilateral agenesis of the maxillary right canine (Fig. 8). The treatment objective was to close the spaces on both sides while leaving space for a temporary crown between the right first premolar (substituting for the right canine) and the right central incisor. At the end of the patient’s growth period, the prosthetic tooth would be replaced with an implant crown or a bonded cantilever bridge.

**Triad Gel, Dentsply Caulk, Milford, DE; www.caulk.com.

Non-Compliance Space Closure in Patients with Missing Lateral Incisors

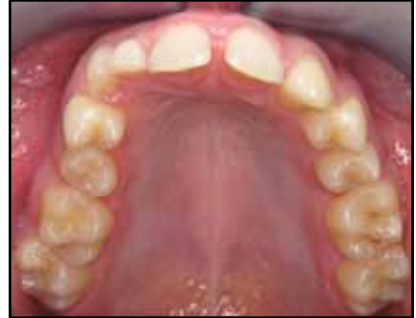
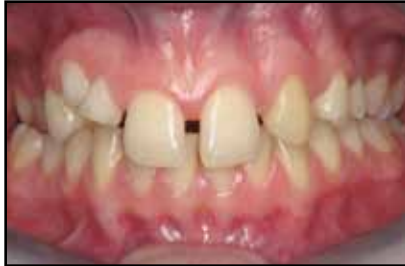
Fig. 8 Case 2. 15-year-old female patient with agenesis of maxillary lateral incisors and maxillary right canine before treatment.

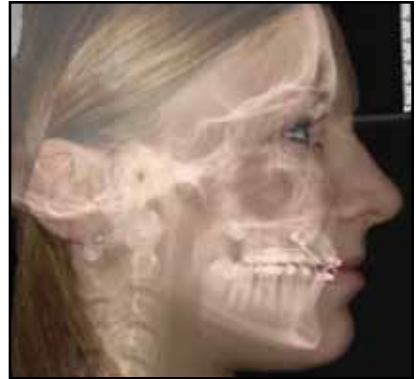
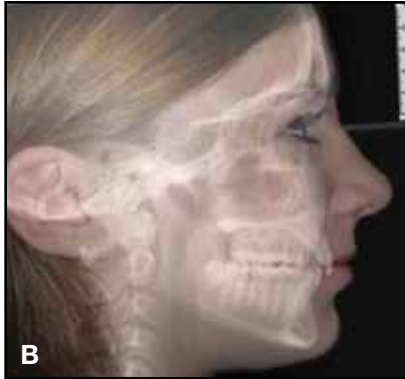
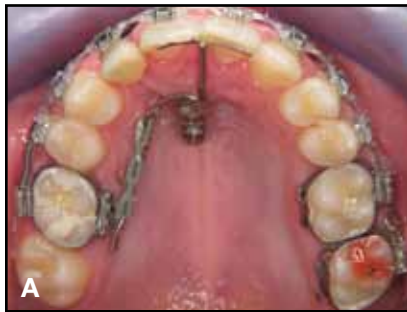

Fig. 9 Case 2. A. After 10 months of space closure using unilateral T-Mesialslider with single-arm T-wire bonded lingually to central incisors, closed-coil spring used for lingual traction (elastic chain added for patient comfort). B. Pretreatment and post-space-closure cephalograms superimposed on facial profiles.

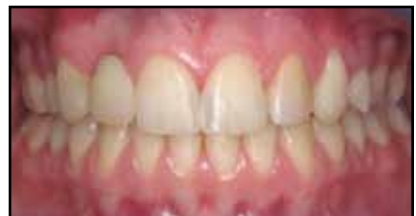
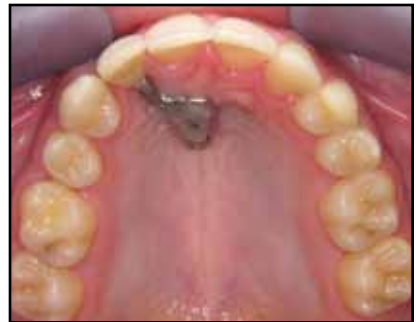
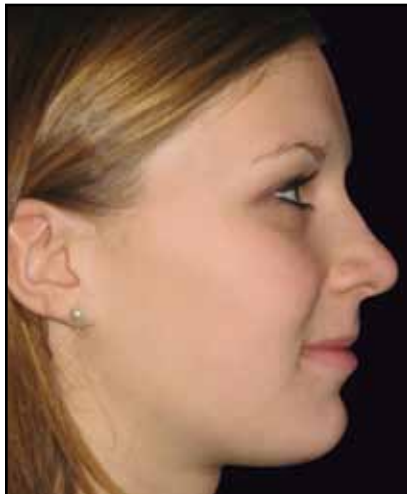Fig. 10 Case 2. Patient after 14 months of treatment; palatal screws remain in place to support temporary lateral incisor crown.

Two 2mm × 9mm palatal miniscrews were placed in line sagittally to support a unilateral T-Mesialslider. The first stage involved space closure and anchorage control, while the upper midline was corrected due to the friction provided by the "reverse anchorage loss phenomenon". In the finishing stage, a push-coil spring was added between the first molar and second premolar (Fig. 9). As in Case 1, +22°-torque brackets were used to improve the palatal root torque of the new "canines". Intrusion bends were made for the right first premolar and extrusion bends for the left canine to achieve more natural-looking gingival margins.

After debonding, the five anterior teeth were contoured with composite resin, and the palatal miniscrews were used to support a cantilevered temporary lateral incisor crown (Fig. 10). Facial photographs at the end of treatment showed a pleasant smile in frontal and side views; superimposition of the lateral cephalograms on the facial profile at the start of treatment and after about 10 months of space closure demonstrated no anterior anchorage loss and good incisor positions and inclinations (Fig. 9B).

Case 3

An adult female presented with bilateral agenesis of the maxillary lateral incisors (Fig. 11). The need for anterior anchorage was moderate, since the occlusion was almost a full Class II. The treatment objective was to maintain the position of the anterior segment.

The central incisors were connected to two palatal miniscrews using an .051" stainless steel wire, and the posterior teeth were moved mesially with power chains. Skeletal support prevented anchorage loss at the central incisors and allowed for space closure and adjustment into a well-seated Class II occlusion (Fig. 12). Treatment duration was 13 months. A fixed bonded retainer was placed for long-term retention, and an upper Essix splint was also prescribed.

As in Cases 1 and 2, intrusion of the first premolars in combination with extrusion of the canines allowed the establishment of a natural "high-low-high" gingival-margin contour. Six porcelain veneers were bonded to reshape the incisors, canines, and first premolars for a more esthetic appearance. The central incisors were widened and elongated for improved display during speech and smiling.

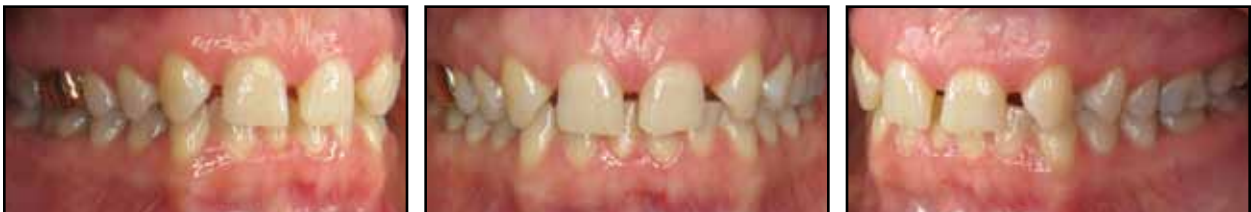

Fig. 11 Case 3. Adult female patient with Class II malocclusion and bilateral agenesis of maxillary lateral incisors before treatment.

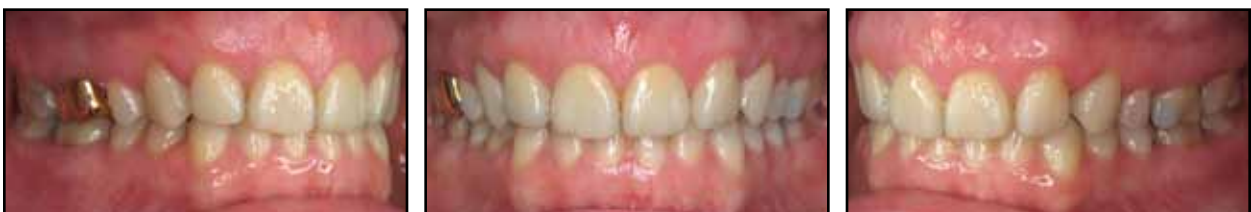

Fig. 12 Case 3. Patient after 13 months of orthodontic treatment and placement of six porcelain veneers; note natural marginal gingival contours due to extrusion of canines (substituting for lateral incisors) and intrusion of first premolars (replacing canines).

TABLE 1
MINI-IMPLANTS WITH ABUTMENTS APPROPRIATE FOR
T-MESIALSLIDER FABRICATION

Brand Name	Manufacturer	Diameter (mm)*	Fixation Mechanism	Basic Slider Framework	Hooks and Stops for Slider
AbsoAnchor Joint Head (JH)	Dentos Daegu, South Korea www.dentos.co.kr	1.5, 1.6, 1.7, 1.8, 2.0	Fixation screw	Must be fabricated	No
Benefit	PSM Tuttlingen, Germany www.psm.ms	1.5, 2.0, 2.3	Fixation screw	Yes	Yes
C-Implant	Cimplant Seoul, South Korea www.cimplant.com	1.8	Friction	Must be fabricated	No
Ortho Implant	Imtec/3M Unitek Monrovia, CA www.3munitek.com	1.8	Click on	Must be fabricated	No
I-Station	Kono Seisakusho Co. Chiba, Japan www.konoseisakusho.jp	1.6, 2.0	Fixation screw	Yes	Yes
ORTHOeasy	Forestadent Pforzheim, Germany www.forestadent.com	1.7	Ligature or cement	Must be fabricated	No
OrthoLox	Promedia Siegen, Germany www.ortholox.de	2.0	Conical with fixation screw	Yes	Yes

*Available lengths vary from 6-11mm.

Discussion

We have found the T-Mesialslider to be an optimal tool for maintaining and improving anterior tooth positions during protraction of an entire maxillary dentition in cases with missing maxillary lateral incisors. As shown in Cases 1 and 2, when the T-wire rests against the central incisors (without being bonded), the stationary anchorage allows anterior torque adjustments to be made with labial archwires for improved incisor inclination. Maxillary arch width can be controlled with the solid, U-shaped wire, which can be expanded as needed.

The main advantage of a system using splinted palatal miniscrews is that the stability and success rate of the screws are much greater than for labially inserted miniscrews in the maxilla or mandible.^{8,12-17} A recently published meta-analysis of 52 studies involving labial screws demonstrated an overall failure rate of 13.5%⁹; in contrast, published success rates of palatal miniscrews range from 100%¹⁶⁻¹⁸ to about 94-95%, the latter in situations where heavy forces (more than 500g) were used for mesial molar movement.^{8,12,17-19} As discussed elsewhere,^{13,14} the anterior palate is particularly suitable for miniscrew insertion, since it has a superior horizontal quantity of cortical bone

and thin attached gingiva. Because the vertical bone quantity is limited, the length of the miniscrews should not exceed 8-9mm.

Several different types of miniscrews with abutments can be used for the T-Mesialslider (Table 1). We recommend the use of two miniscrews—each 7-9mm in length and 1.8-2.3mm in diameter, with a 1.5-2mm transgingival neck—and an abutment appropriate for T-Mesialslider fabrication. The optimal insertion spot may be identified clinically using the contact points of the teeth¹⁴ or the palatal rugae¹³ as landmarks, as has previously been determined in cone-beam computed tomography studies.

Contrary to initial expectations, appliances in the anterior palate are not uncomfortable for most patients and have a high acceptance rate.²⁰ Devices attached to palatal miniscrews will not interfere with tooth or root movements, are nearly invisible extraorally, and provide maximum flexibility for biomechanical treatment planning.

As shown in previous articles, it is possible to treat patients with missing maxillary lateral incisors to a result that provides the look of a healthy, natural dentition through carefully performed orthodontic space closure, finished by cosmetic restoration of appropriate teeth with porcelain veneers.¹⁻⁴ Without miniscrew anchorage, however, such treatment may be time consuming—due to the push-and-pull mechanics used for tooth-by-tooth mesial movement—and requires good patient compliance.^{5,21,22} This is particularly true in a Class III patient with lateral incisor agenesis, a narrow maxilla, and pronounced spacing.^{4,21,22} With palatal miniscrew support, cases previously considered difficult or impossible to treat can now be treated successfully in a shorter period, since many teeth can be moved mesially at the same time.

REFERENCES

- Zachrisson, B.U.; Rosa, M.; and Toreskog, S.: Congenitally missing maxillary lateral incisors: Canine substitution, *Am. J. Orthod.* 139:434-445, 2011.
- Rosa, M. and Zachrisson, B.U.: Integrating esthetic dentistry and space closure in patients with missing maxillary lateral incisors, *J. Clin. Orthod.* 35:221-234, 2001.
- Rosa, M. and Zachrisson, B.U.: Integrating space closure and esthetic dentistry in patients with missing maxillary lateral incisors, *J. Clin. Orthod.* 41:563-573, 2007.
- Rosa, M. and Zachrisson, B.U.: The space-closure alternative for missing maxillary lateral incisors: An update, *J. Clin. Orthod.* 44:540-549, 2010.
- Zachrisson, B.U.: Improving orthodontic results in cases with maxillary incisors missing, *Am. J. Orthod.* 73:274-289, 1978.
- Wilmes, B.; Bowman, S.J.; and Baumgaertel, S.: Fields of application of mini-implants, in *Mini-Implants in Orthodontics: Innovative Anchorage Concepts*, ed. B. Ludwig, S. Baumgaertel, and S.J. Bowman, Quintessence Publishing Co. London, 2008, pp. 91-122.
- Wilmes, B. and Drescher, D.: A miniscrew system with interchangeable abutments, *J. Clin. Orthod.* 42:574-580, 2008.
- Wilmes, B.; Drescher, D.; and Nienkemper, M.: A miniplate system for improved stability of skeletal anchorage, *J. Clin. Orthod.* 43:494-501, 2009.
- Papageorgiou, S.N.; Zogakis, I.P.; and Papadopoulos, M.A.: Failure rates and associated risk factors of orthodontic miniscrew implants: A meta-analysis, *Am. J. Orthod.* 142:577-595, e7, 2012.
- Baumgaertel, S.: Maxillary molar movement with a new treatment auxiliary and palatal miniscrew anchorage, *J. Clin. Orthod.* 42:587-589, 2008.
- Baumgaertel, S.; Razavi, M.R.; and Hans, M.G.: Mini-implant anchorage for the orthodontic practitioner, *Am. J. Orthod.* 133:621-627, 2008.
- Kim, Y.H.; Yang, S.M.; Kim, S.; Lee, J.Y.; Kim, K.E.; Gianelly, A.A.; and Kyung, S.H.: Midpalatal miniscrews for orthodontic anchorage: Factors affecting clinical success, *Am. J. Orthod.* 137:66-72, 2010.
- Ludwig, B.; Glasl, B.; Bowman, S.J.; Wilmes, B.; Kinzinger, G.S.M.; and Lisson, J.A.: Anatomical guidelines for miniscrew insertion: Palatal sites, *J. Clin. Orthod.* 45:433-441, 2011.
- Baumgaertel, S.: Quantitative investigation of palatal bone depth and cortical bone thickness for mini-implant placement in adults, *Am. J. Orthod.* 136:104-108, 2009.
- Kim, H.J.; Yun, H.S.; Park, H.D.; Kim, D.H.; and Park, Y.C.: Soft-tissue and cortical-bone thickness at orthodontic implant sites, *Am. J. Orthod.* 130:177-182, 2006.
- Park, H.S.: Clinical study on success rate of microscrew implants for orthodontic anchorage, *Kor. J. Orthod.* 33:151-156, 2003.
- Nienkemper, M.; Wilmes, B.; Lübberink, G.; Ludwig, B.; and Drescher, D.: Extrusion of impacted teeth using mini-implant mechanics, *J. Clin. Orthod.* 46:150-155, 2012.
- Lim, H.J.; Eun, C.S.C.; and Hwang, H.S.: Factors associated with initial stability of miniscrews for orthodontic treatment, *Am. J. Orthod.* 136:236-242, 2009.
- Nienkemper, M.; Wilmes, B.; Pauls, A.; and Drescher, D.: Multipurpose use of orthodontic mini-implants to achieve different treatment goals, *J. Orofac. Orthop.* 73:467-476, 2012.
- Gunduz, E.; Schneider-Del Savio, T.T.; Kucher, G.; Schneider, B.; and Bantleon, H.P.: Acceptance rate of palatal implants: A questionnaire study, *Am. J. Orthod.* 126:623-626, 2004.
- Zimmer, B. and Seifi-Shirvande, N.: Routine treatment of bilateral aplasia of upper lateral incisors by orthodontic space closure without mandibular extractions, *Eur. J. Orthod.* 31:320-326, 2009.
- Tabuchi, M.; Fukuoka, H.; Miyazawa, K.; and Goto, S.: Skeletal Class III malocclusion with unilateral congenitally missing maxillary incisor treated by maxillary protractor and edgewise appliances, *Angle Orthod.* 80:405-418, 2010.