

Mini-Implant-Supported Temporary Pontics

BENEDICT WILMES, DMD, MSD, PHD
MANUEL NIENKEMPER, DDS, MSC
STEPHANE RENGER, DDS, DMD
DIETER DRESCHER, DMD, PHD

There are two basic treatment options for patients with missing teeth: space closure or space opening for prosthetic replacement.¹⁻⁴ Space closure seems advisable in many cases because of a better functional and esthetic long-term prognosis.^{3,4} Today, appliances attached to temporary anchorage devices (TADs) in the anterior palate, such as the Mesialslider,⁵ the T-Bow,⁶ or the T-Mesialslider,⁷ can enable mesialization for space closure in the upper arch without the need for special patient compliance, as well as retrusion of the lower dentition in conjunction with Class III elastics.

A dental implant should not be placed in a patient younger than 18, because it will likely be overtaken by alveolar growth and end up in infra-position.⁸ Since orthodontic space opening is usually finished by age 15, the question becomes how to bridge the gap from the end of orthodontic treatment to the insertion of the dental implant. Bonded bridges and removable dentures have been associated with atrophy of the local bone, which may necessitate future hard- and soft-tissue grafting.^{8,9} Moreover, Maryland bridges are known for loosening, while removable dentures are uncomfortable and unpopular with adolescents.

As an alternative to bonded bridges and dentures, mini-implants can be inserted to support temporary pontics (“children’s implants”).^{6,10,11}

*PSM Medical Solutions, Tuttlingen, Germany; www.psm.ms. Distributed in the U.S. by PSM North America, Indio, CA; www.psm-na.us.



Fig. 1 Inner thread allows abutment to be attached to head of Benefit mini-implant; double-hex head prevents rotation of abutment and crown.

This approach allows esthetic and stable temporary substitution while preserving the local bone.

Clinical Procedure

We recommend the use of a mini-implant such as the Benefit,* which has an inner thread that permits an abutment to be attached for connection to the crown⁶ (Fig. 1). Larger mini-implants (2mm × 11mm, 2mm × 13mm, or 2mm × 15mm) ensure optimum stability of temporary pontics. Although these mini-implants have self-drilling threads, predrilling to a depth of 2-3mm will help avoid lateral slippage of the mini-implant if the alveolar process is markedly peaked—as



Dr. Wilmes



Dr. Nienkemper



Dr. Renger



Dr. Drescher

Dr. Wilmes is a Professor, Dr. Nienkemper is an Instructor, and Dr. Drescher is Professor and Head, Department of Orthodontics, University of Düsseldorf, Moorenstrasse 5, 40225 Düsseldorf, Germany. Dr. Renger is in the private practice of orthodontics in Saint-Louis, France. Dr. Wilmes is also a Visiting Professor, Department of Orthodontics, University of Alabama at Birmingham School of Dentistry, and the developer of the Benefit system; e-mail: wilmes@med.uni-duesseldorf.de.

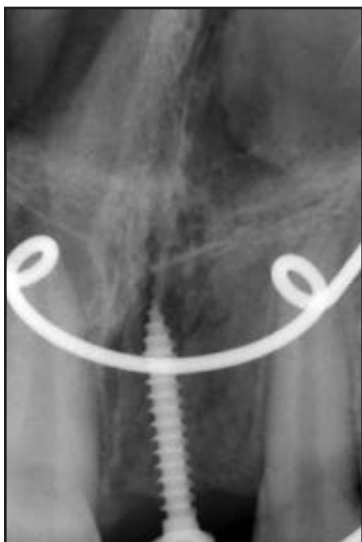
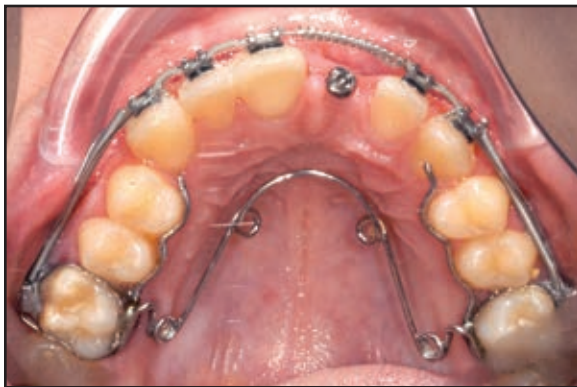

Fig. 2 13-year-old female patient with 2mm × 13mm Benefit mini-implant inserted in space of upper permanent central incisor lost due to trauma.

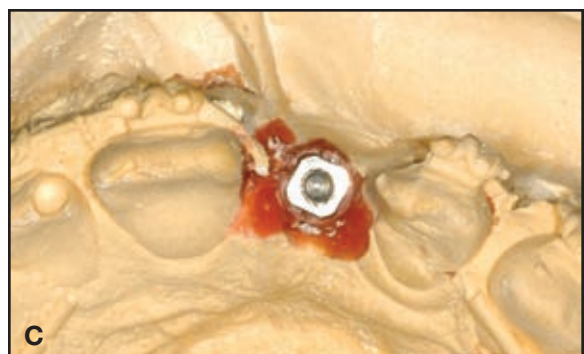
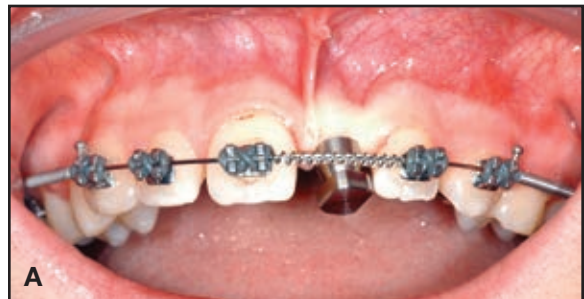

Fig. 3 A. Impression cap placed over mini-implant. B. Laboratory analog. C. Laboratory analog on plaster cast.

often occurs if the ridge has been edentulous for a long period.¹² There is no need for flap preparation, since the mini-implant is inserted transgingivally.

The exact insertion site and angulation must be carefully planned so that the mini-implant is surrounded by bone on all sides (Fig. 2). The amount of available bone can be estimated by manual palpation and by soft-tissue measurement using a dental probe with a rubber stop after local anesthesia. To allow sufficient space for the abutment and pontic, the mini-implant should be inserted as deep as possible. A radiograph should then be taken to confirm the correct positioning of the TAD.

The pontic can be fabricated in the mouth, but is easier to make on a plaster cast. The transfer

process requires an impression cap, a silicone impression, and a laboratory analog (Fig. 3).

An abutment serves as the scaffold for the pontic (Fig. 4). New tooth-colored resin abutments are more esthetic than the original stainless steel abutments, as seen in the cases presented here.

First, the abutment is ground to the desired size (Fig. 5). A prosthetic tooth is then contoured (Fig. 6A) and fixed in the desired position with wax (Fig. 6B). A silicon transfer cap is pressed over the occlusal and labial surfaces of the pontic (Fig. 6C), and the wax is removed (Fig. 6D) so that the pontic can be reattached to the transfer cap in its original position (Fig. 6E). The abutment is then affixed to the mini-implant head, with a wax plug acting as a placeholder to maintain access to the fixation screw (Fig. 6F). A composite is used to fill concavities and model the crown (Fig. 6G).

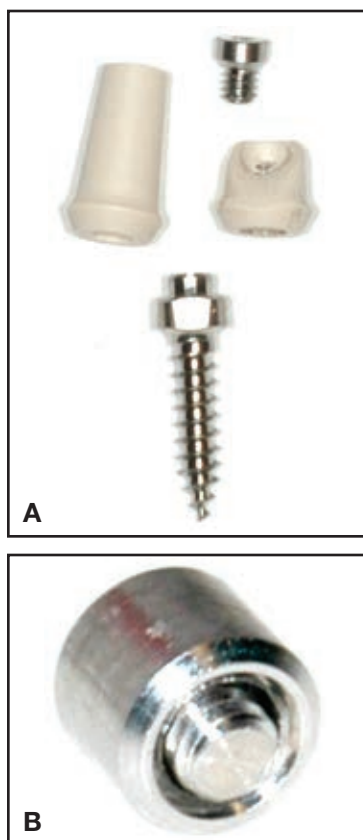


Fig. 4 A. Benefit fixation screw, resin abutments, and mini-implant. B. Fixation screw is incorporated in stainless steel abutment.

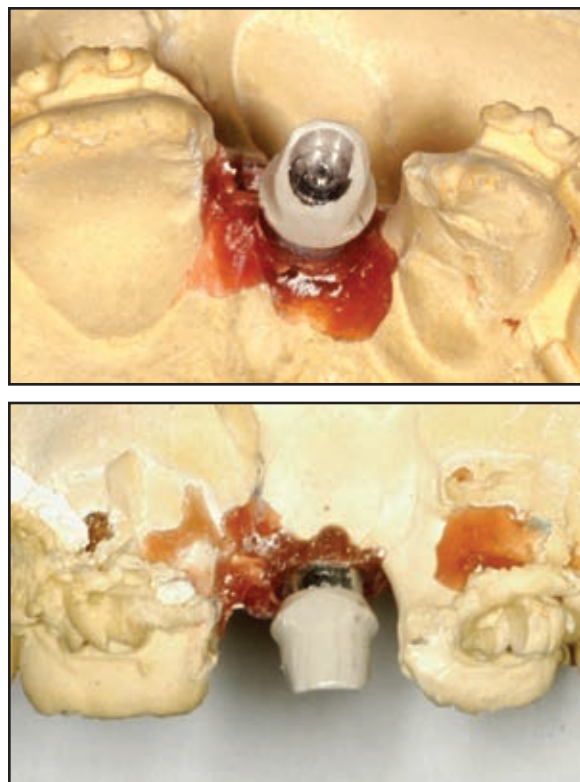


Fig. 5 Esthetic tooth-colored resin abutment on plaster cast after grinding.

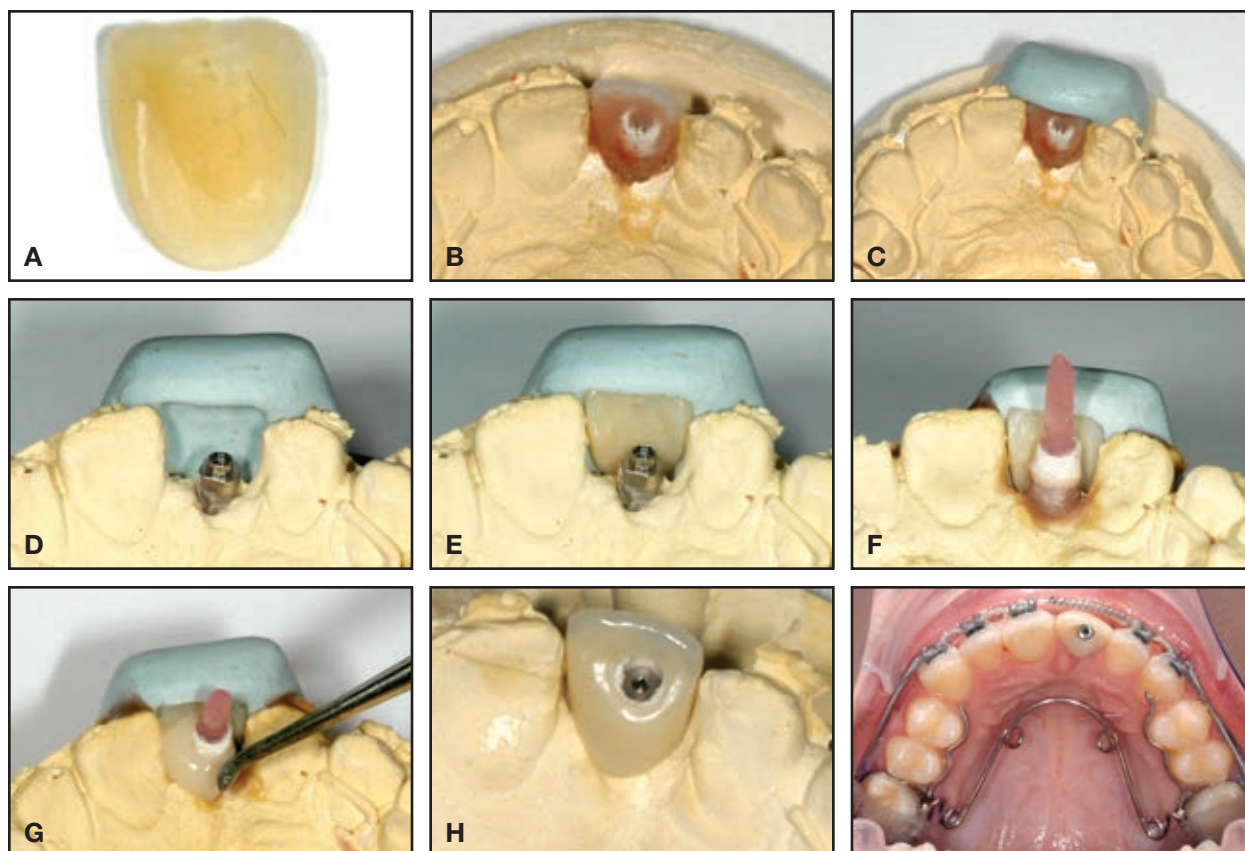


Fig. 6 A. Prosthetic crown ground to desired shape. B. Pontic temporarily affixed to abutment with wax. C. Silicon transfer cap pressed over occlusal and labial surfaces. D. Crown and wax removed from cast. E. Crown reattached to transfer cap in original orientation. F. Resin abutment attached to mini-implant, with wax plug inserted to maintain access to fixation screw. G. Composite applied to form final pontic. H. Pontic polished and inserted.

After polishing, the crown is attached to the mini-implant with the small fixation screw (Fig. 6H). An alternative procedure is to attach only the abutment to the mini-implant with the fixation screw and to bond the pontic in place with composite. Finally, the pontic should be ground to prevent any static or dynamic occlusal contacts that might overload the mini-implant.

Case 1

A 14-year-old male with missing upper lateral incisors presented in our clinic after previous orthodontic space opening (Fig. 7A). Two Benefit mini-

implants (2mm × 13mm) were inserted to support temporary pontics (Fig. 7B). Impressions were taken, and the pontics were fabricated on a plaster cast. The crowns were not fixed to the abutments during the laboratory process, but were subsequently bonded over the mini-implants (Fig. 7C).

Case 2

A 14-year-old female with missing upper lateral incisors presented in our clinic after previous orthodontic space opening (Fig. 8A). Two Benefit mini-implants (2mm × 11mm) were inserted to support temporary pontics. As in Case 1, the

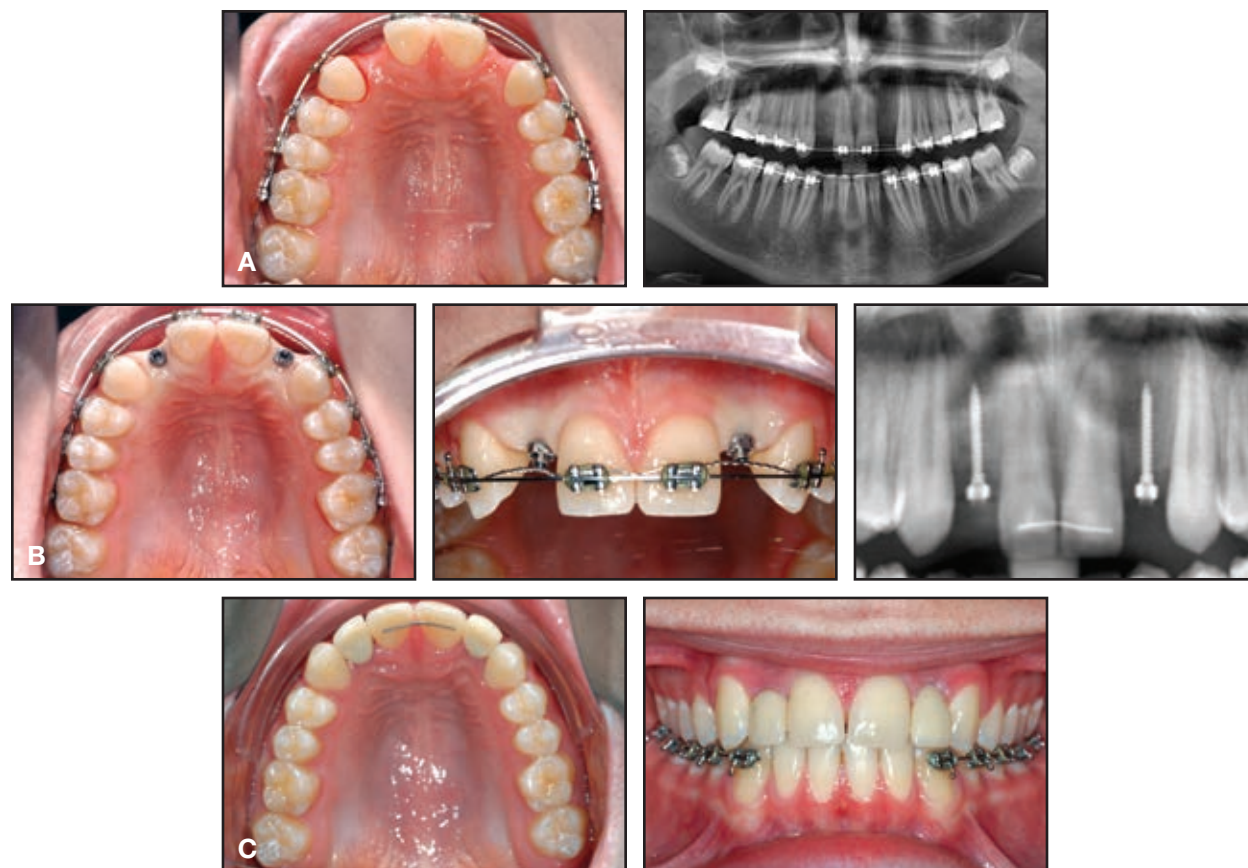

Fig. 7 Case 1. A. 14-year-old male patient with missing upper lateral incisors after orthodontic space opening. **B.** Mini-implants (2mm × 13mm) inserted in lateral incisor spaces. **C.** Temporary crowns bonded to resin abutments with composite.

crowns were fabricated on a plaster cast and were not fixed to the abutments in the laboratory. For a more esthetic appearance, we used an opaquer on the left crown (Fig. 8B); the metal abutment showed through the composite crown on the right side.

Four years later, when the patient was 18, she was scheduled for removal of the mini-implants and placement of dental implants. Because of the stability of the mini-implants and the health of the hard and soft tissues, however, the general dentist decided to replace only the crowns (Fig. 8C). Radiographs taken immediately after mini-implant insertion and two, five, and six years later confirmed vertical bone preservation and healthy implant beds (Fig. 8D).

Case 3

This 13-year-old female presented with missing upper lateral incisors, upper second premolars, and upper second molars. After 11 months of limited orthodontic treatment in the upper arch, two Benefit mini-implants (2mm × 11mm) were inserted to support temporary pontics in the canine areas. The abutments were connected to the pontics in the laboratory, and the pontics were screwed directly to the mini-implants (Fig. 9A) and ground to prevent occlusal contacts.

Five years later, after the completion of growth, the patient was referred for upper restorations (Fig. 9B). Although the pontics had to be

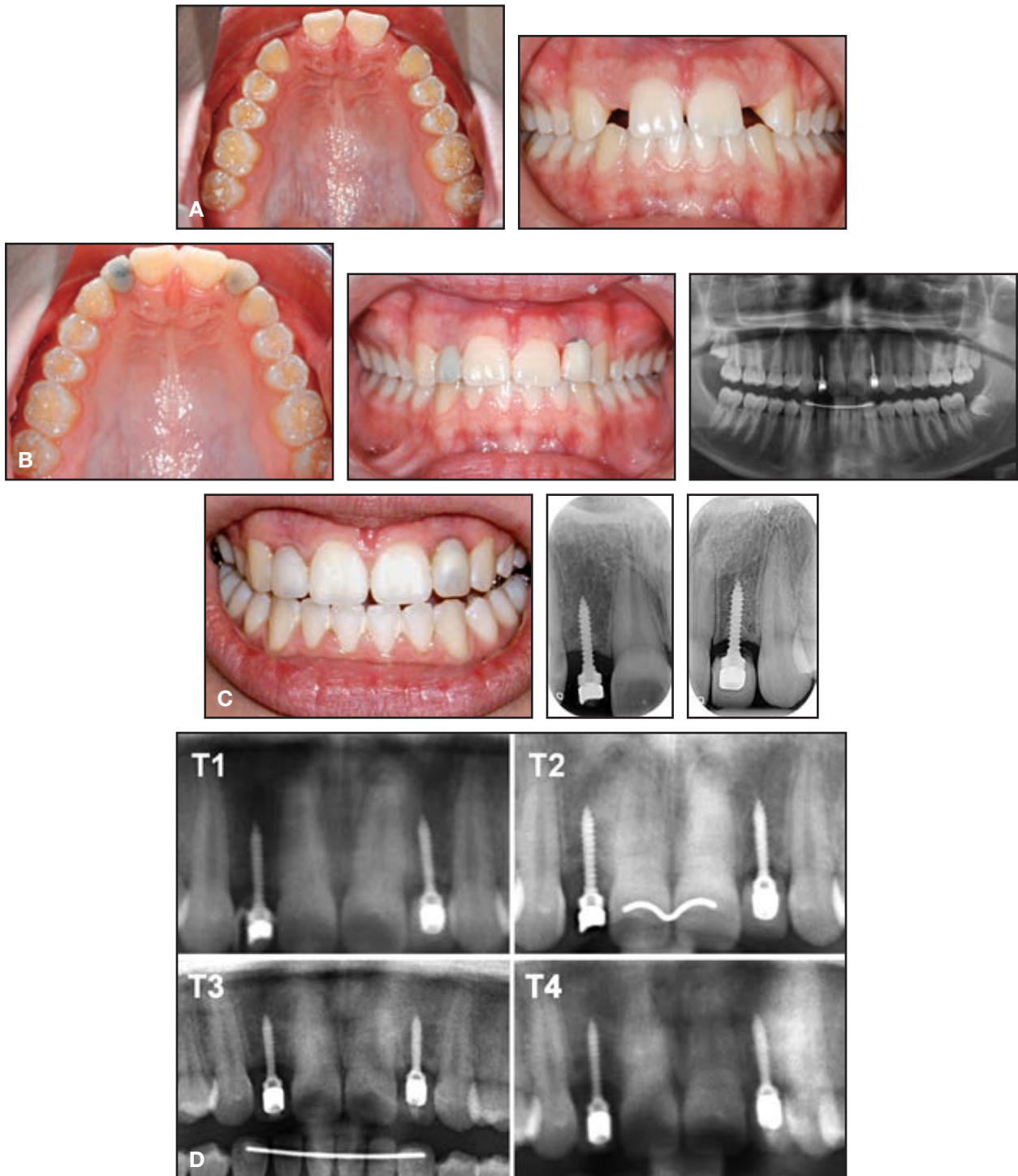


Fig. 8 Case 2. A. 14-year-old female patient with missing upper lateral incisors after orthodontic space opening. B. Temporary pontics bonded over mini-implants (2mm × 11mm), with opaquer used on left crown. C. Four years later, crowns replaced using same mini-implants. D. Radiographs of upper incisor region taken immediately after (T1), two years after (T2), five years after (T3), and six years after (T4) insertion of mini-implants.

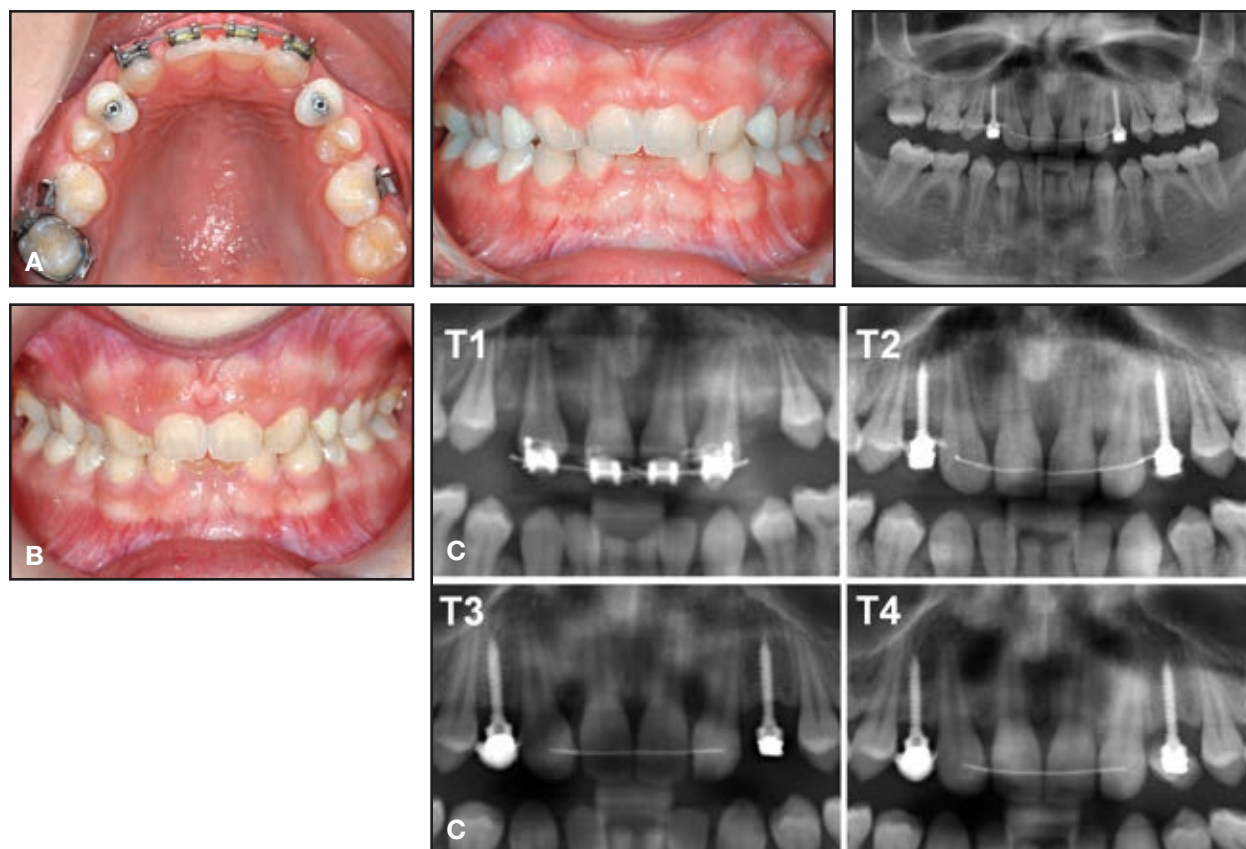


Fig. 9 Case 3. A. 13-year-old female patient with missing upper lateral incisors, second premolars, and second molars near end of upper-arch orthodontic treatment, after insertion of mini-implants (2mm x 11mm) and pontics in canine regions. B. Five years later, patient referred for prosthetic restorations. C. Radiographs of upper incisor region taken immediately before (T1), immediately after (T2), three years after (T3), and five years after (T4) insertion of mini-implants.

repaired within this five-year period, radiographs showed healthy implant beds with no signs of bone atrophy or local growth inhibition (Fig. 9C).

Discussion

A TAD-supported pontic is an effective alternative to a Maryland bridge or a removable denture for temporary replacement of a missing tooth in an adolescent patient. Only one of the 21 mini-implants we have placed for this purpose has failed—a success rate of 95.2%. Since the failed mini-implant was inserted in the molar area, we do not advise placing mini-implants to support

posterior pontics at present. The use of sufficiently large mini-implants (2mm in diameter, 11-15mm in length) and avoidance of occlusal interferences seem to be the most important factors in terms of stability.

Both the original stainless steel abutments (Fig. 4B, Cases 2 and 3) and the newer resin abutments (Fig. 4A, Case 1) must be ground and adapted to provide enough space for the temporary crowns. Since the metal abutment has a tendency to shine through the crown, an opaquer should be used on the pontic (Fig. 8B). The resin abutments are more esthetic.

The temporary crown can be attached by

screwing it directly to the mini-implant (Case 3) or by bonding it over the abutment (Cases 1 and 2). The former allows removal of the crown for future color changes or repairs, but the latter seems to provide greater stability and thus a lower risk of crown fracture.

Although mini-implants experience some osseointegration,^{13,14} their polished, smooth surfaces allow them to be removed without anesthesia, even after many years in place. The risk of fracture during insertion and removal is quite low when large-diameter screws are used.^{15,16} Alveolar growth inhibition has been reported by other authors,¹¹ but we have rarely observed this phenomenon, probably because of the smaller dimensions of mini-implants compared to dental implants. Therefore, it is critical to use a mini-implant that is large enough for stability but small enough to avoid interference with alveolar growth. Further clinical studies involving three-dimensional evaluation of bone volume should be performed before and after use of mini-implant-supported pontics.

REFERENCES

1. Robertsson, S. and Mohlin, B.: The congenitally missing upper lateral incisor. A retrospective study of orthodontic space closure versus restorative treatment, *Eur. J. Orthod.* 22:697-710, 2000.
2. Zachrisson, B.U.; Rosa, M.; and Toreskog, S.: Congenitally missing maxillary lateral incisors: Canine substitution, *Am. J. Orthod.* 139:434-438, 2011.
3. Zachrisson, B.U. and Mjor, I.A.: Remodeling of teeth by grinding, *Am. J. Orthod.* 68:545-553, 1975.
4. Thordarson, A.; Zachrisson, B.U.; and Mjor, I.A.: Remodeling of canines to the shape of lateral incisors by grinding: A long-term clinical and radiographic evaluation, *Am. J. Orthod.* 100:123-132, 1991.
5. Wilmes, B.; Nienkemper, M.; Nanda, R.; Lübberink, G.; and Drescher, D.: Palatally anchored maxillary molar mesialization using the Mesialslider, *J. Clin. Orthod.* 47:172-179, 2013.
6. Wilmes, B. and Drescher, D.: A miniscrew system with interchangeable abutments, *J. Clin. Orthod.* 42:574-580, 2008.
7. Ludwig, B.; Zachrisson, B.U.; and Rosa, M.: Non-compliance space closure in patients with missing lateral incisors, *J. Clin. Orthod.* 47:180-187, 2013.
8. Spear, F.M.; Mathews, D.M.; and Kokich, V.G.: Interdisciplinary management of single-tooth implants, *Semin. Orthod.* 3:45-72, 1997.
9. Rupp, R.P.; Dillehay, J.K.; and Squire, C.F.: Orthodontics, prosthodontics, and periodontics: A multidisciplinary approach, *Gen. Dent.* 45:286-289, 1997.
10. Graham, J.W.: Temporary replacement of maxillary lateral incisors with miniscrews and bonded pontics, *J. Clin. Orthod.* 41:321-325, 2007.
11. Ciarlantini, R. and Melsen, B.: Miniscrew-retained pontics in growing patients: A biological approach, *J. Clin. Orthod.* 46:638-640, 2012.
12. Nienkemper, M.; Pauls, A.; Ludwig, B.; Wilmes, B.; and Drescher, D.: Preprosthetic molar uprighting using skeletal anchorage, *J. Clin. Orthod.* 47:433-437, 2013.
13. Prager, T.M.; Mischkowski, R.; Laube, N.; Jost-Brinkman, P.G.; and Muller-Hartwich, R.: Remodeling along the bone-screw interface, *J. Orofac. Orthop.* 69:337-348, 2008.
14. Melsen, B. and Costa, A.: Immediate loading of implants used for orthodontic anchorage, *Clin. Orthod. Res.* 3:23-28, 2000.
15. Wilmes, B.; Panayotidis, A.; and Drescher, D.: Fracture resistance of orthodontic mini-implants: A biomechanical in vitro study, *Eur. J. Orthod.* 33:396-401, 2011.
16. Jolley, T.H. and Chung, C.H.: Peak torque values at fracture of orthodontic miniscrews, *J. Clin. Orthod.* 41:326-328, 2007.