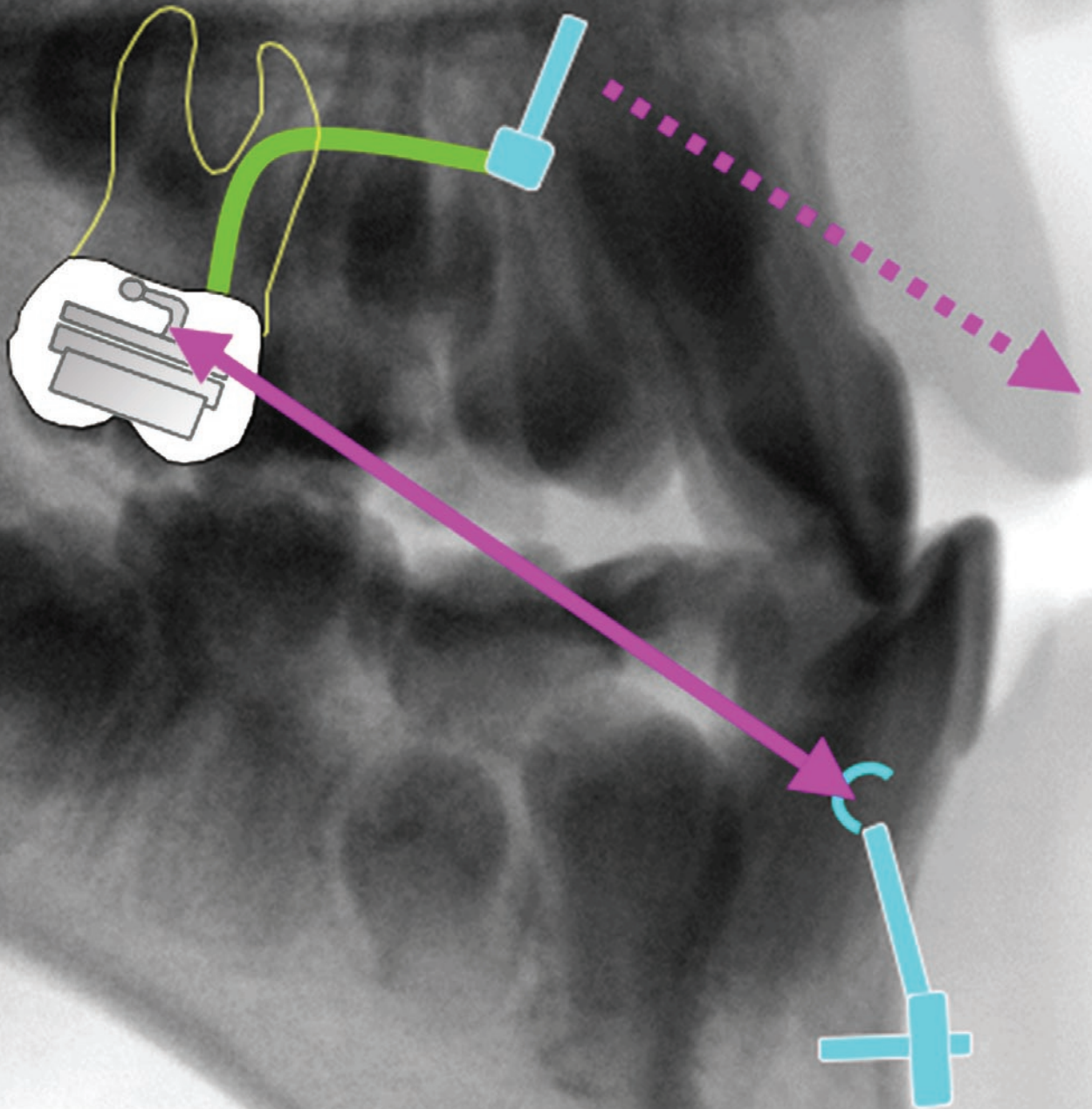




www.jco-online.com

JOURNAL OF CLINICAL ORTHODONTICS

January 2011



Early Class III Treatment with a Hybrid Hyrax-Mentoplate Combination

BENEDICT WILMES, DDS, MSC, PHD
MANUEL NIENKEMPER, DDS, MSC
BJÖRN LUDWIG, DMD, MSD
CHUNG HOW KAU, BDS, MSD, MBA, PHD, MORTH, FDS, FFD, FAMS
DIETER DRESCHER, DDS, MSC, PHD

Skeletal Class III malocclusions are relatively uncommon and usually associated with genetic factors. The etiology may involve a retrognathic maxilla, a prognathic mandible, or both.^{1,2} Young patients with Class III malocclusion and maxillary deficiency are treated primarily with facemasks, but because the force is applied to the teeth, the inevitable mesial migration of the dentition can result in severe anterior crowding.³ Furthermore, skeletal effects are often difficult to achieve with this approach.³

To overcome these disadvantages, De Clerck combined the use of four miniplates (two mandibular anterior and two maxillary posterior) with Class III elastics, avoiding the need for extraoral appliances while applying force directly to the skeletal structures.⁴

We have developed a new option for sagittal skeletal support that requires only two mini-implants in the anterior palate. The Benefit sys-

tem* (Fig. 1) is used to securely couple the temporary anchorage devices and the appliance.⁵ To facilitate advancement of the maxilla, we also recommend opening the midpalatal sutures by rapid expansion.⁶ The Hybrid Hyrax,^{5,7-9} a tooth- and bone-borne expander, can prevent mesial migration of the teeth and enable simultaneous rapid maxillary expansion and skeletally borne maxillary protraction.^{8,9}

De Clerck typically inserted the mandibular miniplates after eruption of the canines. To allow earlier placement, we developed the Mentoplate** (Fig. 2A), which is inserted subapical to the lower incisors and can therefore be used in patients as

*PSM Medical Solutions, Moltkestrasse 41, 78532 Tuttlingen, Germany; www.pms.ms. Distributed in the U.S. by Mondeal North America, Inc., Box 500521, San Diego, CA 92150; www.mondeal-ortho.com.

**Promedia Medizintechnik, Marienhütte 15, 57080 Siegen, Germany; www.promedia-med.de.



Dr. Wilmes



Dr. Nienkemper



Dr. Ludwig



Dr. Kau



Dr. Drescher

Dr. Wilmes is an Associate Professor, Dr. Nienkemper is an instructor, and Dr. Drescher is Professor and Head, Department of Orthodontics, University of Düsseldorf, Moorenstrasse 5, 40225 Düsseldorf, Germany. Dr. Wilmes is also a Visiting Professor and Dr. Kau is Chairman and King James IV Professor, Department of Orthodontics, University of Alabama at Birmingham School of Dentistry. Dr. Ludwig is a Contributing Editor of the *Journal of Clinical Orthodontics*; an Instructor, Department of Orthodontics, University of Homburg, Saar, Germany; and in the private practice of orthodontics in Traben-Trarbach, Germany. Dr. Wilmes is inventor of the Hybrid Hyrax and developer of the Benefit system; Dr. Drescher is inventor of the Mentoplate. E-mail Dr. Wilmes at wilmes@med.uni-duesseldorf.de.

young as 8. With the Mentoplate in the lower arch and the Hybrid Hyrax in the upper, forces are applied only to the skeletal structures (Fig. 2B).

Clinical Procedure

After administration of topical anesthesia, two mini-implants with interchangeable abutments (2mm × 9mm, Benefit system, Fig. 1) are inserted with a contra-angle screwdriver next to the mid-palatal suture, near the second and third palatal rugae. An implant diameter of 2mm is recommended for better stability.¹⁰ A dental probe is used to measure soft-tissue thicknesses from anterior to

posterior and to identify a region with thin mucosa, which will ensure primary stability and avoid long lever arms.^{11,12} Pre-drilling is not needed in young patients because of the low mineralization of the bone.

At the same appointment, bands are fitted to the upper first molars. After transfer caps are placed over the miniscrews, a silicone impression is taken.*** If the space between the mini-implants is narrow, the transfer caps can be cut to fit side-by-side. The angular relationship of the transfer

***Provil, Heraeus Holding GmbH, Heraeusstrasse 12-14, 63450 Hanau, Germany; heraeus-dental.de.




Fig. 1 Benefit system. A. Mini-implant. B. Laboratory analog. C. Impression cap. D. Wire abutment with wire in place. E. Bracket abutment. F. Standard abutment. G. Slot abutment. H. Screwdriver for abutment fixation.

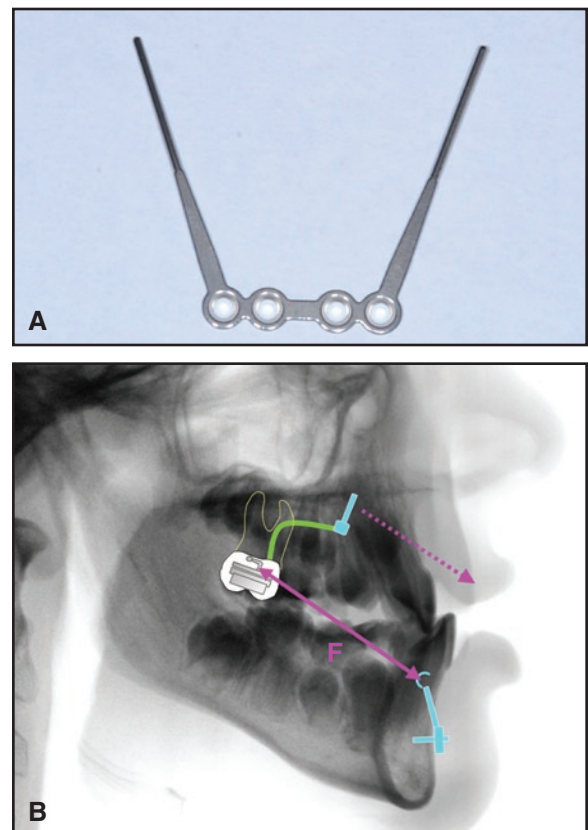


Fig. 2 A. Mentoplate with four fixation holes and transmucosal extensions. B. Biomechanics of combined Hybrid Hyrax-Mentoplate system: forces generated by Class III elastics are transferred to skeletal structures of maxilla and mandible.

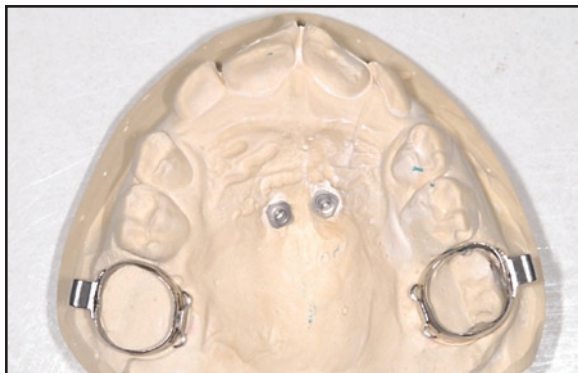


Fig. 3 Plaster cast with molar bands and two laboratory analogs of mini-implants in place.

caps is maintained by connecting them with a light-cured adhesive† in the mouth. After the impression is taken, the laboratory analogs are placed over the transfer caps (Fig. 3). Two standard Benefit system abutments are then screwed over the laboratory analogs. A standard Hyrax‡ palatal split screw is connected by laser-welding it anteriorly to the two abutments and posteriorly to the molar bands. The appliance can still be fitted over the implants even if they are not absolutely parallel.

The Hybrid Hyrax is inserted one week later by pressing it gently over the mini-implants and alternately screwing the two abutments onto the mini-implants. To facilitate the installation, we recommend use of a light-cured cement††† for the molar bands. The expansion screw should be activated immediately after insertion of the Hybrid Hyrax; turning the screw 180° twice a day results in a daily expansion of .8mm.

The oral surgeon places the titanium Mento-plate in the mandible under local anesthesia. After preparation of a mucoperiosteal flap, the two extensions are shortened and adapted. The extensions should penetrate the soft tissue in the attached

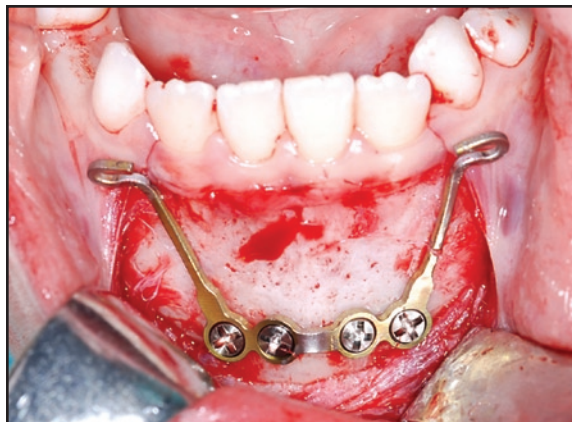

Fig. 4 Case 1. Fixation of Mento-plate with four subapical screws.

mucosa (Fig. 4). After the Mento-plate is fixed with four screws, the flap is flipped back and sutured.

We have treated seven young Class III patients (three males, four females; average age 10.6) with this Hybrid Hyrax-Mento-plate combination. All patients began wearing Class III elastics§ (3.5oz, 3/16") immediately after maxillary expansion. The following are representative cases.

Case 1

A 9-year-old female presented with a severe skeletal (Wits: -8.3mm) and moderate dentoalveolar Class III malocclusion (Fig. 5). A Hybrid Hyrax and Mento-plate were placed. After one week of rapid maxillary expansion, Class III elastics were applied (Fig. 6). The soft tissues appeared healthy throughout treatment.

After nine months of treatment (Fig. 7), the patient's occlusion and profile showed impressive improvement (Wits: -2.8mm).

Case 2

A 12-year-old male presented with a severe skeletal Class III malocclusion (Wits: -5.9mm) and negative overjet (Fig. 8). A Hybrid Hyrax was activated one week after insertion of the Mento-plate and Benefit mini-implants (Fig. 9). Resin bite-opening blocks were bonded to the lower molars

†Transbond LR, trademark of 3M Unitek, 2724 S. Peck Road, Monrovia, CA 91016; www.3mUnitek.com.

‡Registered trademark of Dentaaurum GmbH & Co. KG, Turnstrasse 31, 75228 Ispringen, Germany; www.dentaaurum.de.

†††Band-Lok, Reliance Orthodontic Products, 1540 W. Thorndale Ave., Itasca, IL 60143; www.relianceorthodontics.com.

§Rocky Mountain Orthodontics, 650 W. Colfax Ave., Denver, CO 80204; www.rmortho.com.

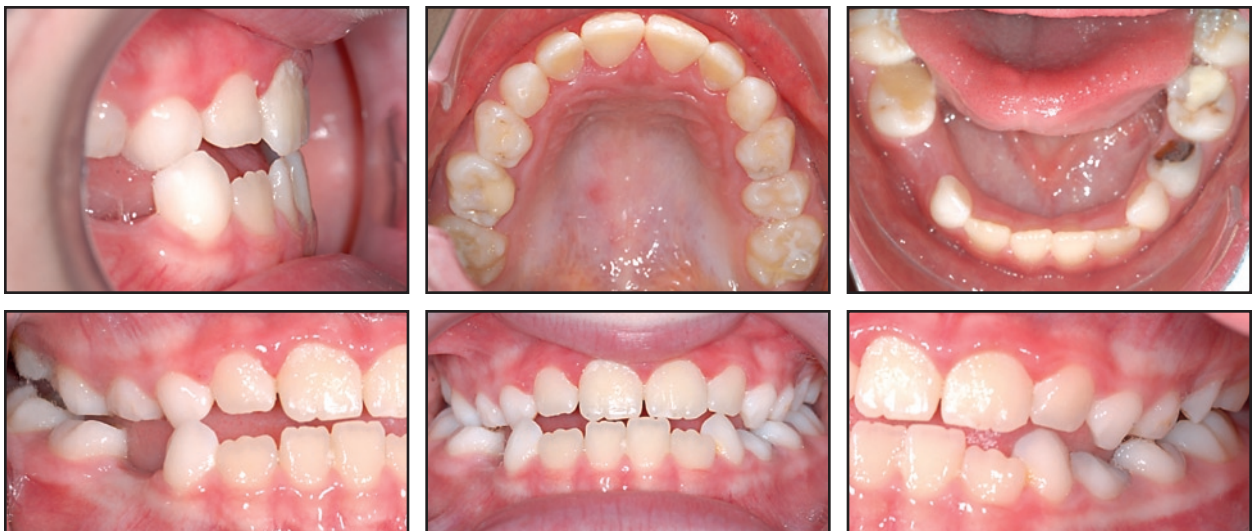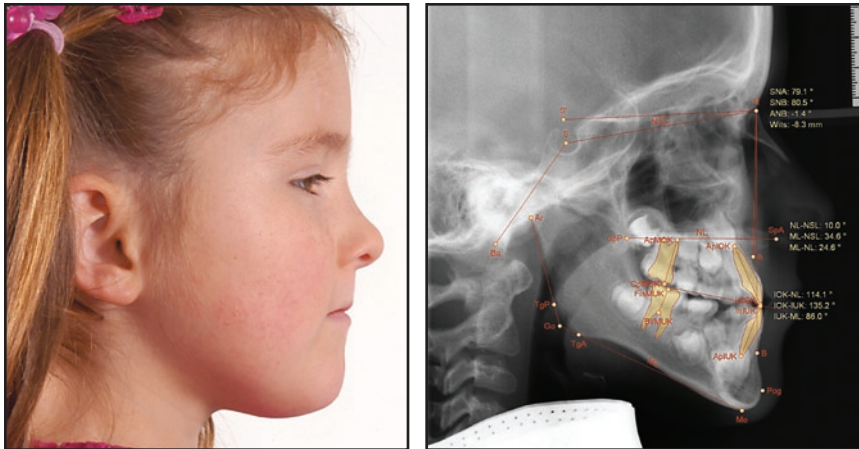


Fig. 5 Case 1. 9-year-old female patient with severe skeletal and moderate dentoalveolar Class III malocclusion before treatment.

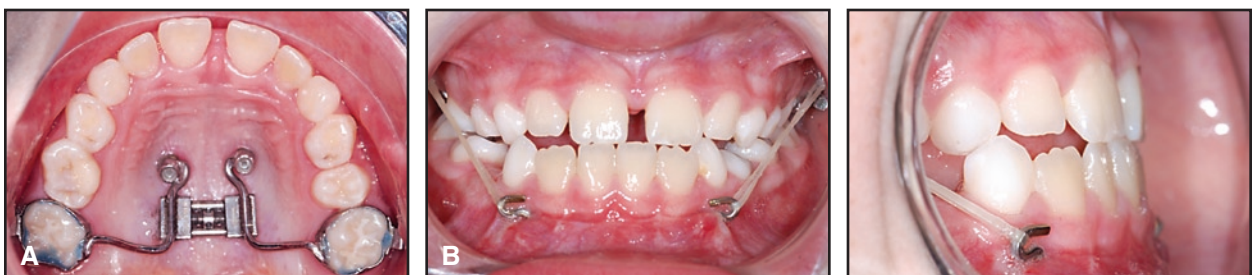

Fig. 6 Case 1. A. Diastema apparent after one week of maxillary expansion with Hybrid Hyrax. B. Class III elastics attached between Hybrid Hyrax and Mentoplate.

to facilitate correction of the anterior crossbite. No soft-tissue impingement by the Mentoplate was observed.

After six months (Fig. 10A), the patient demonstrated substantial occlusal and skeletal improvement (Wits: -2.7mm). The profile was also markedly improved 14 months later, at the end of orthodontic treatment (Fig. 10B).

Discussion

Among our seven young patients, none of the 14 Benefit mini-implants placed in the anterior palate has failed, and no complications have been

observed. We prefer the anterior palate for insertion of the Hybrid Hyrax because of its superior bone quality and relatively low rates of miniscrew failure.⁷ The attached mucosa offers better stability than other areas, and there is no risk of tooth damage. Usually the screws are removed without anesthesia.

The Hybrid Hyrax can also be used for rapid palatal expansion in patients with inadequate anterior dental anchorage (missing deciduous teeth or premolars with underdeveloped roots). The heavy forces associated with other methods may cause root damage or curvature if the premolars have just erupted.

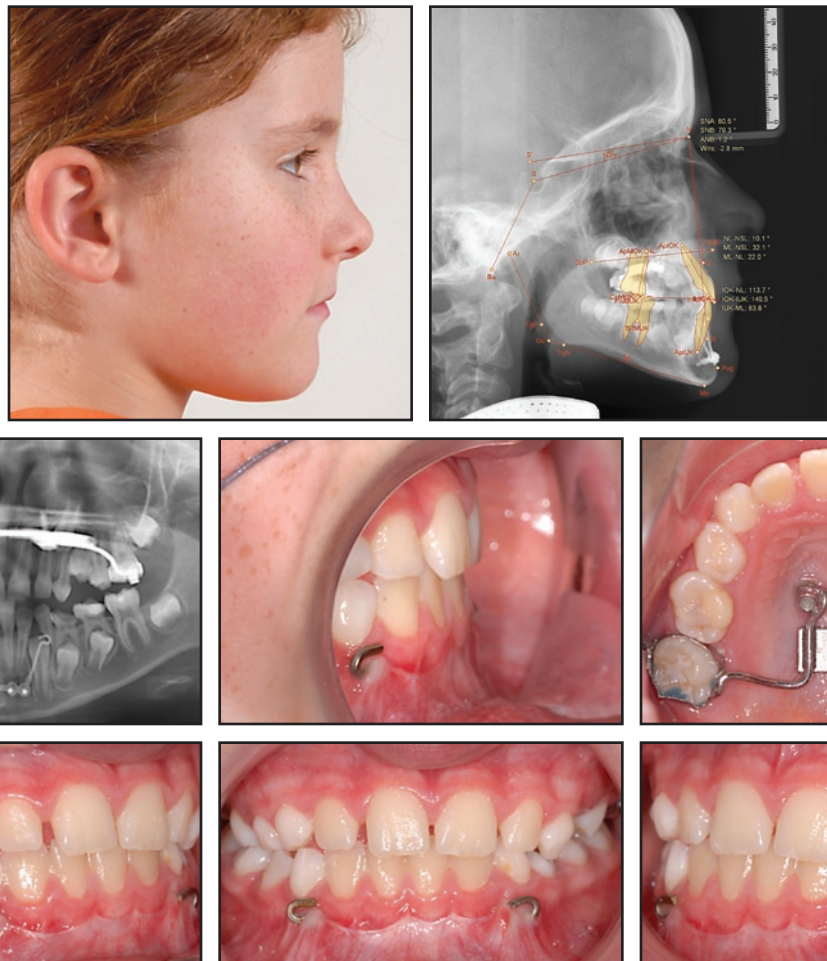


Fig. 7 Case 1. Patient after nine months of treatment.

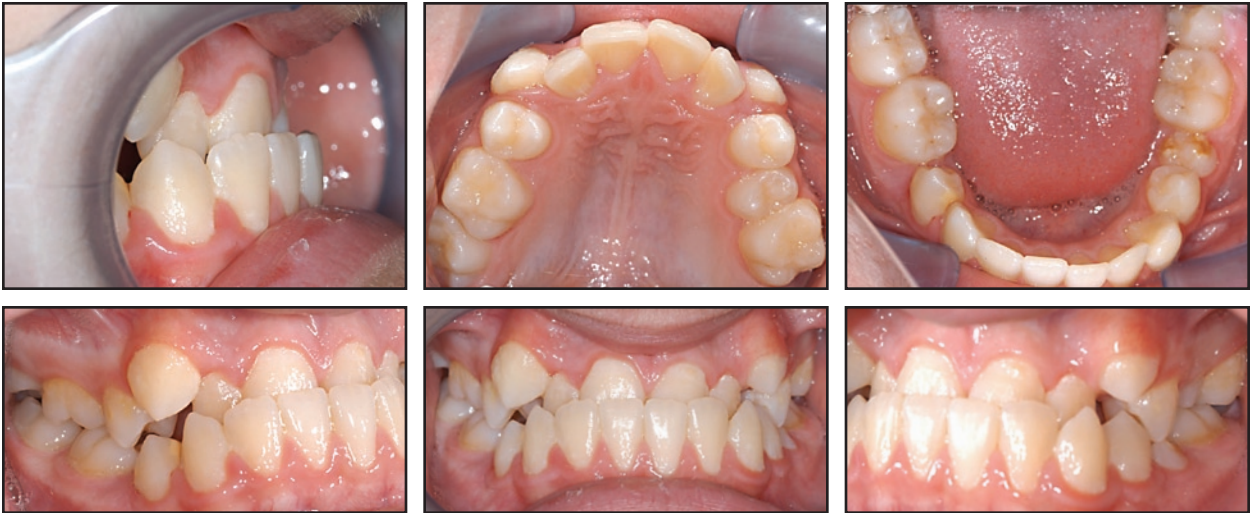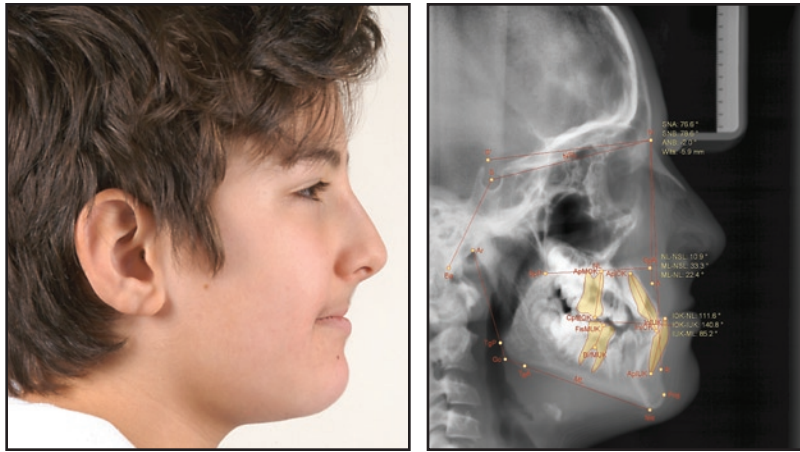


Fig. 8 Case 2. 12-year-old male patient with severe skeletal Class III malocclusion and negative overjet before treatment.

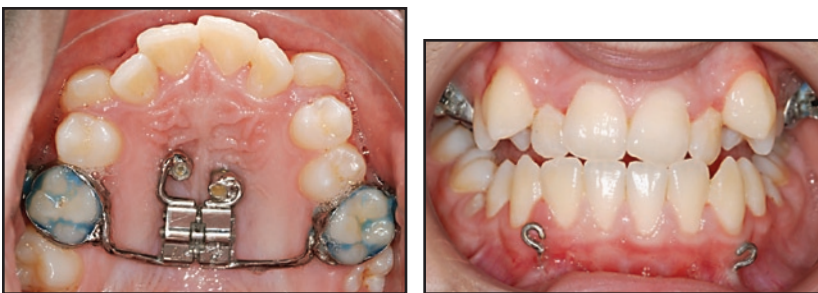


Fig. 9 Case 2. Hybrid Hyrax and Mentoplate in place.

None of the seven Mentoplates has failed in our patients, although we observed mild irritation in cases where the plate extensions passed over the mobile mucosa. Based on these results, it appears that the Mentoplate could be useful not only in orthopedic treatment, but in orthodontic correction as well. Considering that mini-implant failure rates in the alveolar process are relatively high, the mental region appears to be a better site for mandibular skeletal anchorage—it is the “anterior palate” of the lower jaw.

The Hybrid Hyrax-Mentoplate approach for early Class III treatment offers several advantages over other methods:

- Forces are applied directly (by the Mentoplate) or transferred indirectly (Hybrid Hyrax) to skeletal structures.
- The appliances are nearly invisible; no extraoral devices are required.
- Rapid expansion opens the midpalatal sutures for better maxillary protraction.
- Anchorage is stable and reliable.

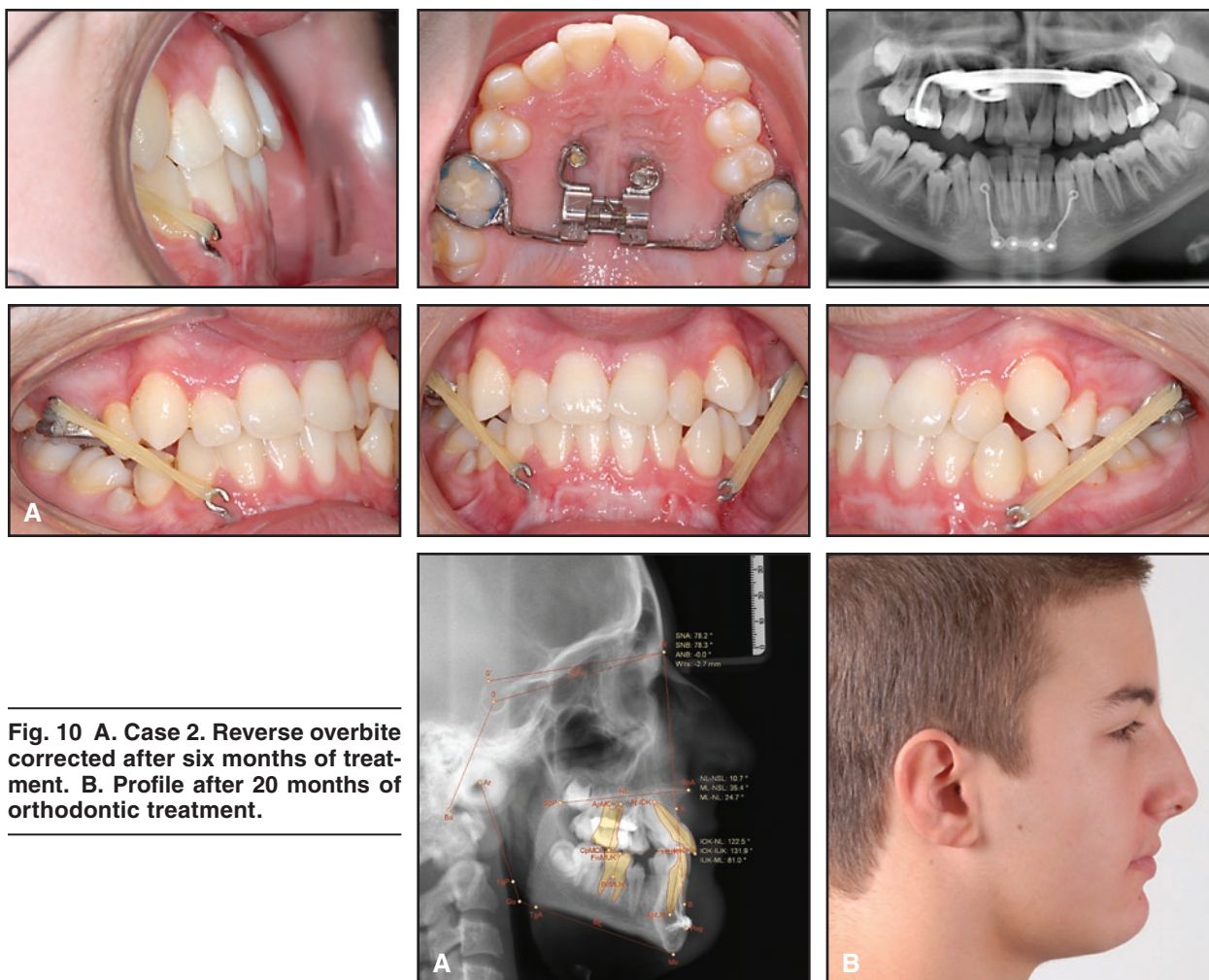


Fig. 10 A. Case 2. Reverse overbite corrected after six months of treatment. B. Profile after 20 months of orthodontic treatment.

- Insertion is possible before complete eruption of the lower canines.
- The placement procedure is less invasive than when multiple miniplates are used.
- The upper and lower arches remain fully accessible for orthodontic tooth movements.

This combination of the Hybrid Hyrax and the Mentoplate seems to offer a promising approach for early treatment of patients with Class III malocclusion.

REFERENCES

1. Litton, S.F.; Ackermann, L.V.; Isaacson, R.J.; and Shapiro, B.L.: A genetic study of Class 3 malocclusion, *Am. J. Orthod.* 58:565-577, 1970.
2. Proffit, W.R.; Fields, H.W. Jr.; and Moray, L.J.: Prevalence of malocclusion and orthodontic treatment need in the United States: Estimates from the NHANES III survey, *Int. J. Adult Orthod. Orthog. Surg.* 13:97-106, 1998.
3. Williams, M.D.; Sarver, D.M.; Sadowsky, P.L.; and Bradley, E.: Combined rapid maxillary expansion and protraction face-mask in the treatment of Class III malocclusions in growing children: A prospective long-term study, *Semin. Orthod.* 3:265-274, 1997.
4. De Clerck, H.J.; Cornelis, M.A.; Cevidanes, L.H.; Heymann, G.C.; and Tulloch, C.J.: Orthopedic traction of the maxilla with miniplates: A new perspective for treatment of midface deficiency, *J. Oral Maxillofac. Surg.* 67:2123-2129, 2009.
5. Wilmes, B.; Drescher, D.; and Nienkemper, M.: A miniplate system for improved stability of skeletal anchorage, *J. Clin. Orthod.* 43:494-501, 2009.
6. Baccetti, T.; McGill, J.S.; Franchi, L.; McNamara, J.A. Jr.; and Tollaro, I.: Skeletal effects of early treatment of Class III malocclusion with maxillary expansion and face-mask therapy, *Am. J. Orthod.* 113:333-343, 1998.
7. Wilmes, B. and Drescher, D.: A miniscrew system with interchangeable abutments, *J. Clin. Orthod.* 42:574-580, 2008.
8. Wilmes, B.: Fields of application of mini-implants, in *Mini-Implants in Orthodontics: Innovative Anchorage Concepts*, ed. B. Ludwig, S. Baumgaertel, and S.J. Bowman, Quintessence Publishing Co., Berlin, 2008, pp. 91-122.
9. Wilmes, B.; Nienkemper, M.; and Drescher, D.: Application and effectiveness of a mini-implant- and tooth-borne rapid palatal expansion device: The hybrid hyrax, *World J. Orthod.* 11:323-330, 2010.
10. Wilmes, B.; Ottenstreuer, S.; Su, Y.Y.; and Drescher, D.: Impact of implant design on primary stability of orthodontic mini-implants, *J. Orofac. Orthop.* 69:42-50, 2008.
11. Büchter, A.; Wiechmann, D.; Koerdt, S.; Wiesmann, H.P.; Piffko, J.; and Meyer, U.: Load-related implant reaction of mini-implants used for orthodontic anchorage, *Clin. Oral Impl. Res.* 16:473-479, 2005.
12. Wilmes, B. and Drescher, D.: Impact of insertion depth and predrilling diameter on primary stability of orthodontic mini-implants, *Angle Orthod.* 79:609-614, 2009.